



## Morphology of Iliotibial Tract and its Clinical Significance

Rupa Chhapparwal<sup>1\*</sup>, Subhash Joshi<sup>2</sup>, Sharda Joshi<sup>3</sup>

<sup>1</sup>Associate Professor, Department of Anatomy, Sri Aurobindo Medical College and Post Graduate Institute, Indore, Madhya Pradesh, India,

Email: cdrupa29@gmail.com,  
Orcid ID: 0000-0003-1166-7022

<sup>2</sup>Director Professor, Department of Anatomy, Sri Aurobindo Medical College and Post Graduate Institute, Indore, Madhya Pradesh, India. Email: drsdjoshi1@gmail.com,  
Orcid ID: 0000-0003-3289-2253

<sup>3</sup>Director Professor, Department of Anatomy, Sri Aurobindo Medical College and Post Graduate Institute, Indore, Madhya Pradesh, India.

Email: sharda\_joshi02@yahoo.co.in,  
Orcid ID: 0000-0002-5446-9811.

\*Corresponding author

Received: 25 May 2021  
Revised: 9 July 2021  
Accepted: 17 July 2021  
Published: 21 August 2021

### Abstract

**Background:** The iliotibial tract (ITT) is present only in human beings. It seems to appear with the development of the upright posture. It stabilizes the knee both in extension and in partial flexion; therefore, used constantly during walking and running. Iliotibial Band Syndrome is a common thigh injury associated with running, cycling or hiking. The anatomy and functional significance of ITT is complex and controversial. Considering the significance of the knowledge of morphology for surgeries and keeping in mind the ever evolving and yet unexplored facets of this subject as there was paucity, the present study was undertaken to shed more light on this topic. **Methods:** The study was carried out on 17 embalmed cadavers. Fascia lata was cleaned and ITT was identified on anterolateral aspect of thigh. Various measurements were recorded. **Results:** Average length of segment of ITT below the level of TFL & G. Max is 32 cm and 28.9 cm. The total length of ITT was 52.1 cm. Width of ITT at mid-thigh level was 4.4 cm. **Conclusions:** The various parameters that have been studied in the present work in central Indian population have not been carried out in such great details.

**Keywords:-** Iliotibial band, Friction syndrome, Fascia Lata, ITT, Maissiat's band.

## INTRODUCTION

The iliotibial tract or iliotibial band (Maissiat's band, ITT) is a linear fibrous reinforcement of the fascia lata.<sup>[1]</sup> It is a lateral thickening of the fascia lata, arises from the iliac crest of the ilium. The ITT moves down the outer third of the thigh, at the femur bone, passing over the greater trochanter. At the level of the greater trochanter, fibers from the Tensor fascia lata (TFL) and gluteus maximus (G.Max) blend

with the ITT anteriorly and posteriorly, respectively.<sup>[2]</sup> Maissiat (1843) considered the ilio-trochantero-tibiale bande to be a ligament connecting the ilium with the knee and playing the principal part in maintaining the balance of the body instance and motion. He stated that man's pre-eminence which shines among all other animals is due anatomically and primarily to the existence of the ilio-trochantero-tibial band. Thus man only, who possesses this band of superior elastic nature,



associated with a small muscular body, also possesses by virtue of this exceptional gift, the natural primary right, there inscribed, to walk upright on earth, to stand up straight, utilizing the full height of his vertebral column, to see and understand everything around him: to dominate and subjugate by his arm, always free and armed with intelligence, everything which could revolt.[3]

It is assumed that the ITT is developed with an upright posture. Probably the ITT helped the species which adopted this posture to attain their bipedal gait.[4] ITT is present only in human beings. Although in lower animals TFL and G.Max get attached to fascia lata, there is no ITT. With the assumption of erect posture the human pelvis, in place of being horizontally placed (as in quadrupeds) becomes vertically disposed and the necessity of bipedalism has to lead to condensation of fascia lata in its anterolateral part of the thigh stretching from the iliac crest to the tubercle of Gerdy and helps to balance the hip and the knee.[1] ITT is essential for erect posture because its tension between the ilium and the upper portion of the lateral condyle of the femur provides stabilizing ligament for the knee joint.[3] The ITT maintains the knee in extension and partial flexion; and is, therefore, used during walking and running. The ITT is the main support of the knee against gravity when leaning forward with slightly flexed knees.[5]

Iliotibial Band Syndrome (ITBS or ITBFS, for Iliotibial Band Friction Syndrome) is one of the common thigh injuries generally in association with running, cycling, or hiking, though it also occurs in weightlifters, skiers, and soccer players.[6] It is usually developed in runners

who suddenly increase their level of activity. Risk factors for ITBS include gait abnormalities like overpronation, leg length inconsistencies, or bow-leggedness.[7] This syndrome needs more clinical investigation directed to morphological, etiological, clinical, and anatomical basis, along with the incidence of the syndrome in the general population.[8] WHO reported ITB friction syndrome as the sixth most common overuse injury in runners (4.3%).[9]

This study aimed to demonstrate the normal anatomy of the stabilizing structures of the side of the knee with anatomic correlation in cadavers. A cadaveric study in an unsuspected population provides a basis for understanding the normal variants, and evaluation of screening for such syndromes. Considering the significance of the knowledge of morphology for surgeries and taking into consideration the ever-evolving and yet unexplored facts of this subject as there was paucity, the present study was undertaken to throw more light on this topic.

## MATERIAL AND METHODS

The Lower limbs for this study were collected from the Department of Anatomy, SAMS & PGI Indore. The sample size for the study comprised 17 adult cadavers (34 limbs) collected over 3 years. The study was carried out on 17 embalmed cadavers (age 60-65 years, height 167.50 cm) with no apparent pathology. The dissection was carried out bilaterally on the adult cadavers. The skin and subcutaneous tissue were removed. Fascia lata (FL) was cleaned and ITT was identified on the anterolateral aspect of the thigh. Various measurements were recorded (Width of ITT at mid-thigh, Total length of ITT from the iliac

crest to the lowest point of insertion, Length of ITT below the level of TFL & G. Max.) with the help of digital vernier caliper, thread, scale & measuring Tape. The study was undertaken only after the approval was obtained from the Ethical Committee of the institution.

## RESULTS

The various parameters to be studied were visualized and as planned various metrical and non-metrical features were recorded and photographed. The following were studied and measured:


- Total Length and Width of ITT at mid-thigh.
- Length of ITT below the level of TFL & G. Max.

The results obtained from the present study have been tabulated in [Table 1]

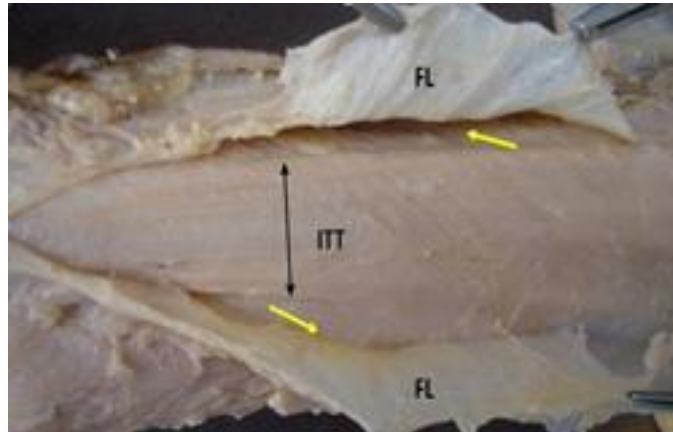
### It was observed that –

The upper broader part of ITT between TFL and G. Max showed as a translucent sheet against the light [Figure 1].


The average length of the segment of ITT below the level of TFL is 32 cm (R -32.6 cm/ L - 31.5 cm); whereas the average length of the segment of ITT below the level of G. Max is 28.9 cm (R -29.3 cm/ L - 28.6 cm). The total length of ITT was 52.1 cm (R -52.5 cm/ L - 51.7 cm). The average width of ITT at mid-thigh level was 4.4 cm on both sides.



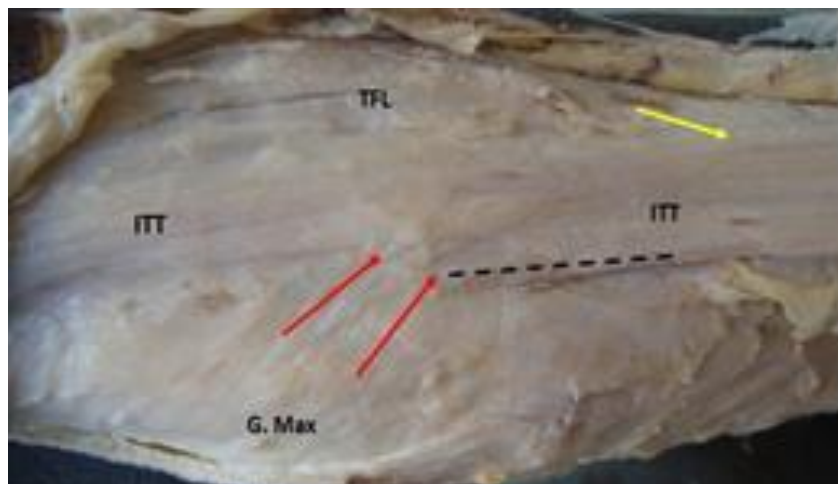
**Figure 1:** Showing upper broader part of ITT between TFL and G. Max shown as translucent sheet against the light.



**Figure 2:** Shows well defined broad ITT being exposed after splitting the superficial layer of FL.



**Figure 3:** Superficial layer of FL has been split to expose the lower tendinous part of TFL (yellow arrow) which merges with ITT



**Figure 4:** Showing G. Max (red arrows) joining posterior edge of ITT (dotted line). Also seen are the fibers of TFL joining ITT (yellow arrow)



**Table 1:** Measurement of ITT.

Observations	Total length of ITT (From iliac crest to lowest point of insertion) (cm)	Length of segment of ITT below the level of TFL & G. Max (cm)	Width of ITT at mid-thigh level (cm)
Maximum	R- 60 L- 60	R-36/34 L-35.5/34	R-6 L-5.7
Minimum	R- 47 L- 42.5	R-28/26 L-28/27	R-3.3 L-2.8
Average	R- 52.5 L- 51.7	R-32.6/29.3 L-31.5/28.6	R-4.4 L-4.4

ITT- Iliotibial Tract, TFL- Tensor fascia lata, G. Max- Gluteus maximus, R-Right, L- Left

## DISCUSSION

ITT is made of dense fibrous connective tissue that appears from the TFL, the gluteal fascia, and G. max. It descends vertically at the lateral aspect of the thigh, between the layers of the superficial fascia, and inserts on Gerdy's tubercle and the lateral proximal aspect of the fibular head.<sup>[10]</sup> The ITT is essential for erect posture because its tension between the ilium and the upper portion of the lateral condyle of the femur provides an additional stabilizing ligament for the knee joint.<sup>[3]</sup> Evans (1979) defined the ITT as the vertical component of the deep fascia of the thigh. The vertical bunch of fibrous tissue in mid-thigh, the majority can be followed, up to the iliac tubercle.<sup>[4]</sup>

In all the cases studied cutting of fascia lata to enclosed ITT was observed [Figure 2]. Flethy fibers of TFL in the lower part are replaced by tendinous fibers which join the ITT [Figure 3]. A similar feature has been described on the anat.stonybrook.edu website.

The majority of the fibers of G.max get attached to the posterior edge of ITT and are prolonged into it. The combined pull of these 2 muscles (TFL and G.max) can be conveniently transferred to the ITT. Like TFL from ITT, it can act on its origin and thereby help in balancing the pelvis on the thigh.<sup>[3,11]</sup>

In the current study, the fibers of TFL or G. Max could be traced into ITT which is in the form of a thick flattened tendon. [Figure 4]. It is present on the anterolateral aspect of the thigh. It begins as a distinct band slightly below the greater trochanter, where the fibers of TFL or G. Max converge and extend up to Gerdy's tubercle. The total length of ITT from the iliac crest up to Gerdy's tubercle was 52.1 cm (R-52.5cm/L-51.7cm). In the literature reviewed Wang et al (2006),<sup>[12]</sup> has reported its length as 7-13 cm. They have neither indicated the point of reference for measuring this length nor given any explanation for such discrepancy of length. The dissimilarity in length can be accounted for by the difference in the stature, age, and race of the two groups studied. As a lower point of attachment of TFL to ITT was higher than that of G.Max, hence the average length of ITT below the attachment of TFL was 32 cm whereas below the G.Max it was 28.8 cm. Other workers in this field have not given this particular measurement hence it could not be compared.

The average width of ITT at the mid-thigh level was found to be 4.4 cm on both sides. Wang et al (2006),<sup>[12]</sup> mentioned the width of ITT as 3.5 cm. They have not mentioned the level at which the width was measured.

Findings in the current study show that the ITT narrows when traced inferiorly.

It is well known that the ITT is a thickened band which has been marked out as ligamentous (Kaplan 1958), tendon of G.Max and TFL (John Fairclough et al 2006) or strong accessory ligament (Birnbaum et al. 2004) controlling the two joints- hip and knee.<sup>[1,3,6,13]</sup>

An IT band injury, commonly known as Runner's Knee, can be prevented and/or healed by a combination of implementing several brief pre-and post- exercising stretches as well as correction of the running form, especially concerning the pronation of the foot upon impact with the ground.<sup>[9,14]</sup> The cause of the iliotibial tract friction syndrome in Northern Europe may be the cool climate, and slippery running surfaces.<sup>[8]</sup> Groves performed the first anterior cruciate ligament (ACL) reconstruction using an iliotibial band transplant. Tendon material from ITT was used in a special way for adding stability to the knee called iliotibial band tenodesis. By surgically tightening the ITT, excessive excursion of the tibia is prevented. A graft from the ITT has mechanical properties and results in less anterior knee pain.<sup>[15]</sup>

Shortening of the IT band is associated with low back pain, iliotibial friction syndrome,

patellofemoral pain syndrome, chondromalacia patellae, and anterior knee pain. Due to tightness of the IT band, the subjects suffer from pain, ascending and descending stairs, difficulty in running, cycling, etc.<sup>[1]</sup>

## CONCLUSIONS

The anatomy and functional importance of the Iliotibial tract is complex and remains controversial. Several descriptions have been contradictory or incomplete. Disorders of the iliotibial tract may be the reason for pain and disability. A Study of the anatomy and morphology of the iliotibial tract describes how it acts to balance the hip and knee joints and that would be useful for surgeons and physiotherapists for improvement in the diagnosis and management of disorders of ITT.

The various observations that have been studied in the present work in the central Indian population have not been implemented in such great detail in the Indian context. Hence, these values can be utilized for ascertaining normalcy.

## REFERENCES

1. Beal RK. The iliotibial band a review. *Curr Orthop Pract.* 2009;20(1):87-91. <http://dx.doi.org/10.1097/BCO.0b013e328316ec7f>.
2. Carro LP, Hernando MF, Cerezal L, Navarro IS, Fernandez AA, Castillo AO. Deep gluteal space problems: piriformis syndrome, ischiofemoral impingement and sciatic nerve release. *Muscles Ligaments Tendons J.* 2016;6(3):384-396. doi:10.11138/mltj/2016.6.3.384
3. Kaplan EB. The iliotibial tract Clinical and morphological significance. *JBJS.* 1958;40A(4):817-832.
4. Evans P. The postural function of the iliotibial tract. *Ann R Coll Surg Engl.* 1979;61(4):271-80.
5. Standring S. Pelvic girdle and lower limb. In: Gray H, Susan S, Borley NR, Collins P, Crossman AR, Gatzoulis MA, Healy JC, et al. editors. *Gray's anatomy: the anatomical basis of clinical practice.* 40th Ed. Section 9. London: Churchill Livingstone 2008;1349- 1350

6. Lavine R. Iliotibial band friction syndrome. *Curr Rev Musculoskelet Med.* 2010;3(1-4):18-22. doi:10.1007/s12178-010-9061-8
7. Aderem J, Louw QA. Biomechanical risk factors associated with iliotibial band syndrome in runners: a systematic review. *BMC Musculoskelet Disord.* 2015;16:356. doi:10.1186/s12891-015-0808-7
8. Orava S. Iliotibial tract friction syndrome in athletes—an uncommon exertion syndrome on the lateral side of the knee. *Br J Sports Med.* 1978;12(2):69-73. doi: 10.1136/bjism.12.2.69.
9. Lucas CA. Iliotibial band friction syndrome as exhibited in athletes. *J Athl Train.* 1992;27(3):250-252.
10. Labronici PJ, Teixeira TM, de Medeiros FB, et al. Clinical and Anatomical Comparison of the Fibular Nerve in Gerdy's Safe Zone. *Rev Bras Ortop.* 2015;45(1):23-27. doi:10.1016/S2255-4971(15)30212-3
11. Kirici Y, Ozan H. Double gluteus maximus muscle with associated variations in the gluteal region. *Surg Radiol Anat.* 1999;21(6):397-400. doi: 10.1007/BF01631351.
12. Wang C, Yu D, Cong H. [Primary repair of tissue defects of achilles tendon and skin by free grafting of anterolateral femoral skin flap and iliotibial tract]. *Zhongguo Xiu Fu Chong Jian Wai Ke Za Zhi.* 2006;20(10):1037-9.
13. Birnbaum K, Siebert CH, Pandorf T, Schopphoff E, Prescher A, Niethard FU. Anatomical and biomechanical investigations of the iliotibial tract. *Surg Radiol Anat.* 2004;26(6):433-46. doi: 10.1007/s00276-004-0265-8.
14. Orchard JW, Fricker PA, Abud AT, Mason BR. Biomechanics of iliotibial band friction syndrome in runners. *Am J Sports Med.* 1996;24(3):375-9. doi: 10.1177/036354659602400321.
15. Saran R. Evaluation of anterior cruciate ligament repair with iliotibial band. *People's J Scient Res.* 2010;3(2):11-16.

**Acknowledgements:**

“The authors would like to thank and pay respect to all those kind hearts who have donated their body for research and education purposes without whom this work would not have been accomplished”

Source of Support: Nil, Conflict of Interest: None declared