

Rare Presentations on Fibroptic Bronchoscopy.

Gurpreet Singh¹, Rajwinder Kaur², Gurpreet Singh Oberoi³, NC Kaja⁴

¹Senior Consultant, Pulmonary Medicine & Critical care, Satguru Partap Singh Hospital, Ludhiana, India.

²Senior Resident, Satguru Partap Singh Hospital, Ludhiana, India.

³Resident CTVS DNB, Registrar, Fortis Hospital, Mohali, India.

⁴Professor, Chest and TB Department, Govt Medical College, Amritsar, India.

Received: May 2019

Accepted: May 2019

Copyright: © the author(s), publisher. It is an open-access article distributed under the terms of the Creative Commons Attribution Non-Commercial License, which permits unrestricted non-commercial use, distribution, and reproduction in any medium, provided the original work is properly cited.

ABSTRACT

Flexible bronchoscopy is a brief procedure routinely performed under local anaesthesia or under sedation by pulmonologist. These days flexible bronchoscopy is more widely used for diagnostic as well as therapeutic purposes without much morbidity or complications. Flexible bronchoscopy gives better access to the tracheo-bronchial tree with its more flexible tip to reach upper lobe areas and greater patient comfort as compared to rigid bronchoscopy. Here, we present few cases of infectious as well as non-infectious diseases who were diagnosed only after diagnostic bronchoscopy was done. All patients have typical presentation on bronchoscopy. Diagnostic bronchoscopy should be done at the earliest for early diagnosis and better disease outcome.

Keywords: Bronchoscopy, mycetoma, vasculitis, mucormycosis.

INTRODUCTION

In 1897, Gustav Killian, gave the idea of bronchoscopy by extracting a foreign body from bronchus and exploring tracheo-bronchial tree with rigid esophagoscope.^[1] Fibre-optic bronchoscope was first time introduced by Shigeto Ikeda in 1966 and he gave initiative to the practice of diagnostic and therapeutic bronchoscopy in pulmonary medicine.^[2] Since then bronchoscopy plays a pivotal role with regard to diagnosis of various endo-bronchial diseases as well as therapeutic purposes as in critical care. In cases of massive haemoptysis, it is helpful in localization of the anatomic site of bleeding, isolation of the involved airway, control of haemorrhage and treatment of the underlying cause of haemoptysis. Here we put all cases of airway diseases which have unique presentations on bronchoscopy and were exclusively diagnosed after bronchoscopy guided specimen.

CLINICAL CASES

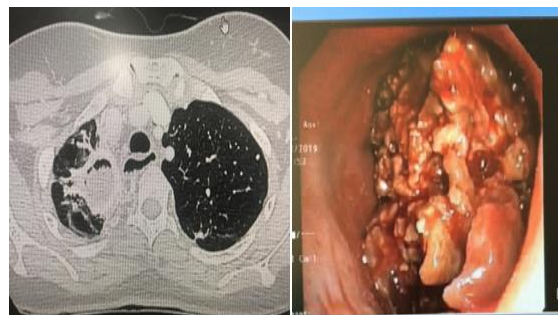Case 1

A 32 years old female, previously treated case of pulmonary tuberculosis, presented to our OPD with complaint of haemoptysis. Her CECT chest was done which revealed right upper lobe fibro-cavitary lesion with mycetoma formation in apico-posterior segment of right upper lobe.

Name & Address of Corresponding Author

Dr. Rajwinder Kaur,
Department of Pulmonary Medicine and critical care,
SPS Hospitals,
Ludhiana.

Exploratory bronchoscopy was done. It revealed no evidence of active bleeding but there was a large mycetoma involving apico-posterior segment of right upper lobe. Bronchoscopic biopsy was taken. KOH mount and biopsy from fungal ball revealed hyaline branched septate fungal hyphae. Patient was managed conservatively with antifungal drugs and advised for bronchial artery embolization if there is recurrent/massive haemoptysis.

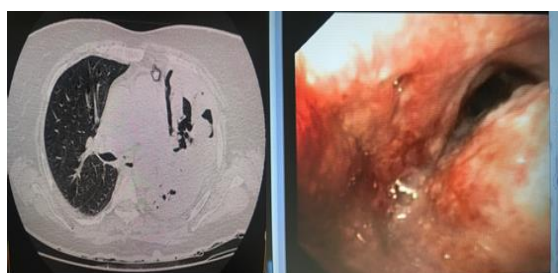


(1) CT chest showing right upper lobe cavity with mycetoma formation in it. (2) Bronchoscopic view of mycetoma within a cavity in right upper lobe.

Case 2

51 years old female was admitted to SPS Hospitals Ludhiana with complaint of cough with expectoration for last 2 months. She had history of hearing loss with bilateral ear discharge for 15 days. Patient was operated for fistula in ano 15 days back. Now she was having purulent discharge from fistulectomy wound. Swab culture from the wound showed growth of enterococcus faecium. Contrast enhanced CT of chest revealed a large area of air

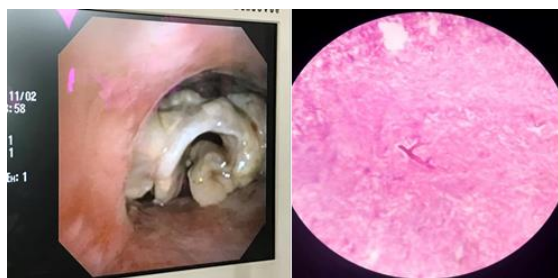space consolidation involving left upper and lower lobe with multifocal areas of breakdown /cavitation within. Diagnostic bronchoscopy was done which revealed mucosal ulceration & stenosis of left main bronchus. Endo-bronchial biopsy revealed granulomatous inflammation with polyangitis. CT Paranasal sinuses was also done which revealed chronic bilateral maxillary sinusitis with bilateral otitis media, mucosal thickening in all other sinuses. Osseous destruction of maxilla with soft tissue thickening and air foci in it. Tissue from buccal mucosa also showed acute leucocytoclastic vasculitis. She was diagnosed with granulomatosis with Polyangitis with high PR3 (protease 3) activity. Patient was treated with high dose steroids and intravenous cyclophosphamide therapy.



(1) CT chest showing completely attenuated lumen of left main bronchus with left lung collapse consolidation. (2) bronchoscopic view of carina showing ulcerated mucosa with stenosed left main bronchus

Case 3

A 30 year old male patient was admitted in emergency of our hospital with complaints of shortness of breath & cough with expectoration for 1 month. He was known case of diabetes mellitus type-1 for 5 yrs. Sputum and blood cultures were sterile. In view of worsening breathlessness, patient was intubated. CT Chest revealed bilateral lower lobe pneumonia with large cavitating lesions in left upper lobe and left lower lobe. Bronchoscopy was performed which revealed dirty white hard mass like spiral growth over carina, obstructing the main stem bronchus. Biopsy revealed hyaline aseptate hyphae, with wide (right) angled, irregular branching pattern consistent with mucormycosis.



(1) Bronchoscopic view of hard mass like growth of mucor over carina obstructing main stem bronchus. (2) microscopic view showing filamentous aseptate branching fungal hyphae .

Case 4

A 43-year old female patient presented to our OPD with dyspnea and episodes of haemoptysis for last 8-9 months. Her medical history was unremarkable. She was treated as asthmatic by local practitioner for a few months. At presentation, stridor was the only abnormal finding on physical examination. She was not able to perform Pulmonary function tests (PFTs) because of respiratory distress. All lab investigations were within normal limits. Her Chest X-Ray postero-anterior (PA) was normal. We got CT chest done which revealed mass in tracheal lumen nearly totally obliterating the lumen of trachea [Figure 1].

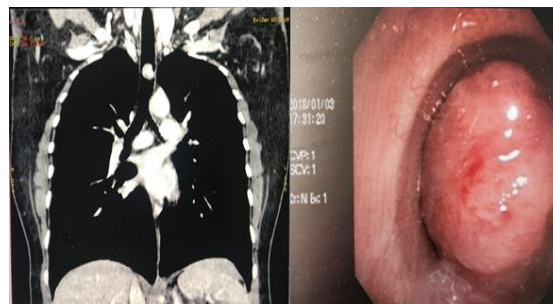


Figure 1: (i) coronal view of CT chest showing tracheal tumor obliterating >95% of its lumen. Fig. (ii) bronchoscopic view of tracheal tumor

Flexible bronchoscopy was performed under moderate sedation and showed a smooth-surfaced, lobulated mass lesion that was obliterating most of tracheal lumen [Figure 2].

Tracheostomy and tumor excision was done under general anaesthesia. The mass was removed with coblation technique and was sent for histopathological examination. Patient was kept in ICU (intensive care unit) on mechanical ventilation for next 24 hrs. On histologic examination, pathological diagnosis of the mass was consistent with inflammatory myofibroblastic tumor. IHC panel studies were negative. On follow-up, Symptoms of patient resolved and check bronchoscopy was done to further examine the airways which showed no positive findings.

DISCUSSION

Bronchoscopy procedure is very well tolerated and most commonly performed on outpatient basis. Flexible bronchoscopes have a fiber-optic light source that illuminates the distal end of the scope allowing visualization of the airways. It has a suction port which allows for aspiration of fluid and defogging of the camera through a working channel. One can bend the tip of the scope 120–180 degrees with toggle at handling end of bronchoscope. Premedication for bronchoscopy is not routinely recommended. Although patient will well tolerate the procedure under local anaesthesia, intravenous sedation should be offered to every patient.^[3] The aim of sedation is to facilitate patient comfort and satisfaction and to minimize patient anxiety, cough

and dyspnoea during procedure and reducing complications of the procedure.^[4-6] Lidocaine is the most commonly used local anaesthetic for fiberoptic bronchoscopy. It is short-acting, has a wide margin of safety and tissue toxicity is rare. Lidocaine gel, spray and nebulization are used to anaesthetise the mucous membranes and vocal cords. Lowest doses of lidocaine solution (1%) are used with spray-as-you-go technique.^[3] toxicity may occur above recommended doses of lidocaine (>600mg). Treatment includes supplemental oxygen and intravenous methylene blue (1 mg/kg) which should always be available in bronchoscopy suite.^[7]

Common diagnostic uses of flexible bronchoscopy include exploration of central airways for obstruction such as foreign body, tumour, or sampling of airway masses. Visual inspection of the airway is also done in cases of trauma. In cases of consolidation, bronchial washings are taken after instillation of normal saline in airways. Brushing and biopsy are useful in cytological diagnosis of malignancies as well as invasive infections. Therapeutic bronchoscopy plays an important role in foreign body removal, for whole lung lavage as in pulmonary alveolar proteinosis. In intensive care unit, bedside technique is used to place endotracheal tube in cases of difficult intubation, percutaneous tracheostomy, clearing retained secretions in lung atelectasis, instillation of mucolytics in airways in severe asthmatics and in management of massive haemoptysis.^[8] Bronchoscopy identifies the site of bleeding in 73–93% of episodes of massive bleeding.^[9]

Morbidity and mortality associated with fiberoptic bronchoscopy are very low. Bronchospasm, laryngospasm and reduction in oxygen saturation is commonly encountered in patients undergoing bronchoscopy. Use of supplemental oxygen is recommended and pulse oximetry should be routinely used. Oxygen delivery via a pharyngeal catheter was found to be superior to nasal catheter to prevent hypoxemia. Cardiac arrhythmias, as well as ischaemic episodes, have been reported to occur during the procedure especially in at risk patients. Increases in systolic arterial pressure and heart rate during procedure are associated with ECG changes in 15% cases.^[10] Minor bleeding occurs in 0.19% and severe in 0.26% of bronchoscopies.^[11] X-Ray chest is routinely done to rule out pneumothorax after trans-bronchial lung biopsy.

Bronchoscopy has evolved in the current era in form of various diagnostic and therapeutic forms: EBUS-TBNA (Endo-bronchial Ultrasound Guided Trans-bronchial Needle Aspiration) and Navigational Bronchoscopy are advances for evaluation of distal parenchymal as well as mediastinal lesions.^[12] It has valuable role in palliative treatment in lung cancers e.g. bronchoscopic stent placement and tumor ablation. Auto-fluorescence imaging bronchoscopy (AFI) is advanced endoscopic technology that can

detect subtle mucosal changes with the aid of different colors.^[13]

CONCLUSION

Although rigid bronchoscopy is efficient tool in field of interventional medicine, but fibre-optic bronchoscopy has its own value in present era for early diagnosis and management of endo-bronchial lesion. We found that early bronchoscopy will not only give the definitive diagnosis but also can help better management and improves patient outcome as in cases of haemoptysis for maintaining airways before bronchial artery embolization. Risk of complications can be reduced with thoroughly ruling out the risk factors and performing the procedure in presence of expertise personnels.

REFERENCES

1. Becker HD. A short history of bronchoscopy. In: Ernst A, eds. Introduction to Bronchoscopy. New York, NY: Cambridge University Press, 2009.
2. Ikeda S. Flexible bronchofiberscope. Ann Otol Rhinol Laryngol 1970;79:916-923.
3. The British Thoracic Society guideline for diagnostic flexible bronchoscopy in adults. Thorax 2013
4. Gonzalez R, De-La-Rosa-Ramirez I, Maldonado-Hernandez A, et al. Should patients undergoing a bronchoscopy be sedated? Acta Anaesth Scand 2003; 47: 411–415.
5. Putinati S, Ballerin L, Corbetta L, Trevisani L, Potena A. Patient satisfaction with conscious sedation for bronchoscopy. Chest 1999; 115: 1437–1440.
6. Matot I, Kramer MR. Sedation in outpatient bronchoscopy. Resp Med 2000; 94: 1145–1153.
7. John Pawlowski and Stephen D. Pratt ANESTHESIA FOR BRONCHOSCOPY. in ARMIN ERNST editor. Introduction to Bronchoscopy. Cambridge University Press 2009: p:46-61.
8. Lee, Pyng & Tamm, M & Chhajed, Prashant. (2004). Advances in bronchoscopy - Therapeutic bronchoscopy. The Journal of the Association of Physicians of India. 52. 905-14.
9. Hsiao EL, Kirsch CM, Kagawa FT, Wehner JH, Jensen WA, Baxter RB: Utility of fiberoptic bronchoscopy before bronchial artery embolization for massive hemoptysis. AJR Am J Roentgenol 2001; 177: 861–867
10. Davies L, Mister R, Spence DP, Calverley PM, Earis JE, Pearson MG. Cardiovascular consequences of fibreoptic bronchoscopy. Eur Respir J 1997; 10: 695–8
11. Facciolo N, Patelli M, Gasparini S, Lazzari Agli L, Salio M, Simonassi C: Incidence of complications in bronchoscopy. Multicentre prospective study of 20,986 bronchoscopies. Monaldi Arch Chest Dis 2009; 71: 8–14
12. Haas AR, Vachani A, Serman DH. Advances in diagnostic bronchoscopy. Am J Respir Crit Care Med. 2010;182(5):589–597. doi:10.1164/rccm.201002-0186CI
13. He Q1, Wang Q, Wu Q, Feng J, Cao J, Chen BY. Value of autofluorescence imaging videobronchoscopy in detecting lung cancers and precancerous lesions: a review. Respir Care 2013;58:2150-9.

How to cite this article: Singh G, Kaur R, Oberoi GS, Kajal NC. Rare Presentations on Fiberoptic Bronchoscopy. Ann. Int. Med. Den. Res. 2019; 5(4):TB07-TB09.

Source of Support: Nil, **Conflict of Interest:** None declared