

Laparoscopic Radical Hysterectomy for Early Stage Cervical Cancers – A Single Team Experience

S.G. Balamurugan¹, B.Kalpana², A. N. Lesin Kumar³, A. Giles Fanny³

¹Surgical oncologist, Guru Hospital, 4/120F, Ring road, Uthangudi, Madurai, Tamilnadu

²FNB reproductive medicine, Obstetrician and Gynecologist, Guru Hospital, 4/120F, Ring road, Uthangudi, Madurai, Tamilnadu

³DNB General Surgery, consultant surgeon, Guru Hospital, 4/120F, Ring road, Uthangudi, Madurai, Tamilnadu

Received: July 2019

Accepted: August 2019

Copyright: © the author(s), publisher. It is an open-access article distributed under the terms of the Creative Commons Attribution Non-Commercial License, which permits unrestricted non-commercial use, distribution, and reproduction in any medium, provided the original work is properly cited.

ABSTRACT

Background: Current evidence on the efficacy and safety of Laparoscopic Radical Hysterectomy for early stage cervical cancer is adequate to support the use of this procedure provided that normal arrangements are in place for clinical governance, consent and audit. This study aims to present our single unit experience of Laparoscopic Radical Hysterectomy performed for early stage cervical cancers. **Methods:** 74 laparoscopic radical hysterectomies performed for early stage cervical cancers from 2012 to 2017 were reviewed. **Results:** Key efficacy outcomes evaluated were completing the procedure without conversion to open surgery (conversion rate – 3/74), the mean operating time (144 mts), intra operative complications (rectal injury 2/74, primary hemorrhage 1/74), post operative complications (ureteric fistula 2/74, vesicovaginal fistula 1/74, port site hernia 1/74), number of LN removed (mean - 14 LN on each side), recovery time (6 hrs on average) and length of hospital stay (average – 5days); long term outcomes viz recurrence rate and % year survival are under study. **Conclusion:** Our initial experience indicate that laparoscopic radical hysterectomy is safe, feasible and effective with low morbidity and with comparable outcome to open approach; It does not compromise oncological radicality of resection; short term results are promising; long term results are awaited.

Keywords: Radical hysterectomy, cancer cervix, Laparoscopy.

INTRODUCTION

The laparoscopic approach for cervical cancer has been shown to result in shorter hospital stay, faster return of bowel function, less pain, better cosmetic results and lesser overall morbidity than open surgery; Moreover randomized controlled trials have shown that the long term recurrence and survival results of laparoscopic surgery are not different from those of conventional open technique. Therefore, laparoscopic surgery is now considered as an accepted treatment for cervical cancer if the necessary expertise is available;

Herein we report our experience with 74 laparoscopic radical hysterectomies performed for early cervical cancers and summarize the operative and postoperative outcomes.

MATERIAL AND METHODS

After getting consent from the patients who were on follow up, 74 radical hysterectomies performed by a single team in our institute between Nov 2012 and Nov 2017 were reviewed.

Name & Address of Corresponding Author

Dr. S. G. Balamurugan
Guru hospital, 4/120F,
Ring road, Uthangudi,
Madurai, Tamilnadu.

The tumor board primarily evaluated the patients. Depending on the tumor stage and patients consent and choice of RT vs surgery, patients with early stage cervical cancers I and II A were chosen for the surgery. Apart from thorough clinical examinations, contrast enhanced CT (CECT) or magnetic resonance imaging (MRI) were used to rule out parametrial invasion and distant metastasis. Advanced Ca cervix with parametrial invasion, adjacent organ infiltration, distant metastasis and post RT residual or recurrent diseases were excluded. Patients unfit for general anesthesia in virtue of age related morbidities or other comorbid conditions were also excluded

Surgical Technique:

Under ETGA, patient is placed in Lloyd Davis position. a small sand bag is kept beneath the patient at the level of ASIS; a total of 5 ports are used.

A 10 mm camera port in the umbilicus. A 10mm working port in the Mc Burneys point on right side.

A 5mm port para rectally in the midclavicular line. A set of two 5mm ports are inserted in the mirror image of the ports on left side [Figure 1].

Surgeon and camera surgeon stand on the left side. Assistant surgeon stands on the right side.

Myoma screw is used to manipulate uterus; dissection starts by cutting the round ligament with harmonic shears extending into UV fold down

wards and plane is dissected between bladder and uterus [Figure 2]; this dissection is facilitated by CO2 insufflation; the peritoneal cut is completed onto left side cutting the left round ligament; Uterus is antverted and ureter dissection is started; peritoneum medial to infundibulo pelvic ligament is incised; ureter is exposed and pushed laterally; peritoneal cut is extended down in to POD; rectum is pulled up and peritoneum over POD is incised with harmonic shear; CO2 gas gushes in and immediately opens the loose areolar plane between rectum and posterior vaginal wall. The rectum is dissected off the posterior vaginal wall upto levator ani; the ureter is retracted medially and posterior leaf of broad ligament above ureter is cut; ureter is retracted medially and pararectal plane is opened [Figure 3]; the internal iliac A forms the lateral boundary of this space ; Uterine A is identified and clipped near the origin; and cut; dissection is continued in the pararectal space; till the levator ani muscle; the uterosacral and Mackendrot's ligaments are cut from their origin; the paracolpos which is the continuation of Mackendrot's ligament is divided upto levator ani muscle; the medial cut end of uterine A is then lifted off the ureter, thus exposing the ureteric tunnel; similar steps taken on the contralateral side; ureteric tunnel dissection is done with adequate traction and countertraction; exposed paracolpos is cut as laterally as possible. good length of vagina exposed below the growth and vagina is opened with adequate cuff; infundibulo pelvic ligaments are cut at the end with ligasure and entire specimen is separated and removed through vagina; vagina is repacked to avoid CO2 leak; pelvic LN dissection is started at the bifurcation of common iliac A; loose areolar tissue over EIA is swept till inguinal ligament; fibro fatty tissue along EIV is dissected; nodes in the obturator are swept cranially. Dissection is done upto bifurcation of ext iliac V. psoas muscle with genitofemoral N is the lateral limit of dissection. Same procedure repeated on opposite side [Figure 4]. Nodal dissection specimen is removed through vagina; after confirming hemostasis vaginal closure is done intracorporeally with 2-0 vicryl continuous interlocking sutures; A nasogastric tube (No.16) is introduced through one of the 5mm ports and kept as drain posterior peritoneum is not closed. Ports are removed under vision and 10mm port sites are sutured

RESULTS

A total of 74 laparoscopic radical hysterectomies were done; the average age was 48.6 years (range 30 – 56 years). 34 patients were stage IB1, and 40 patients had stage IIA1 disease by FIGO staging; The average blood loss was 112 ml (range 20 – 400ml). The mean operating time was 154 min (range 120 to 260 min).

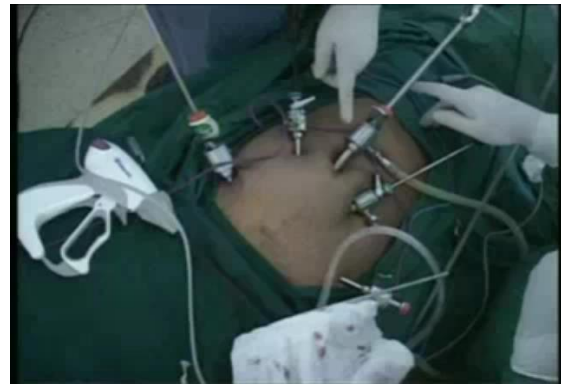

Figure 1:

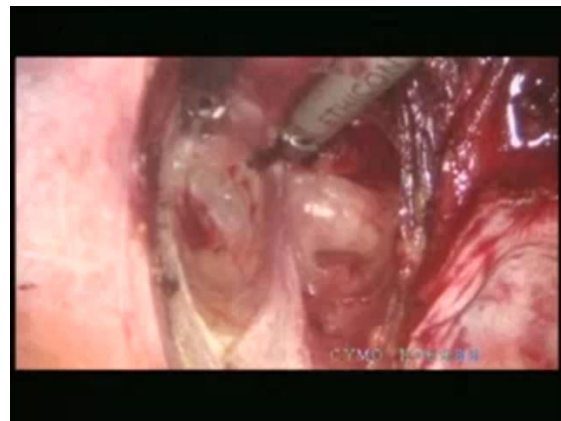


Figure 2:

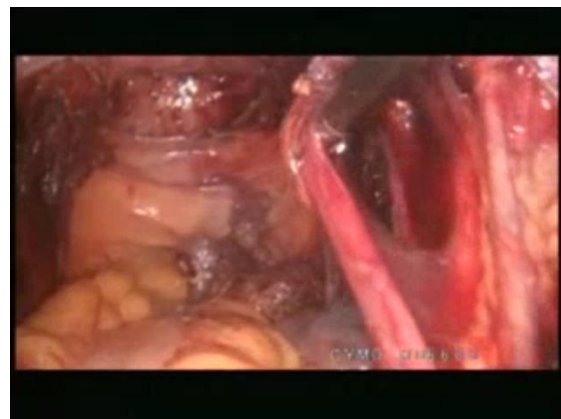


Figure 3:

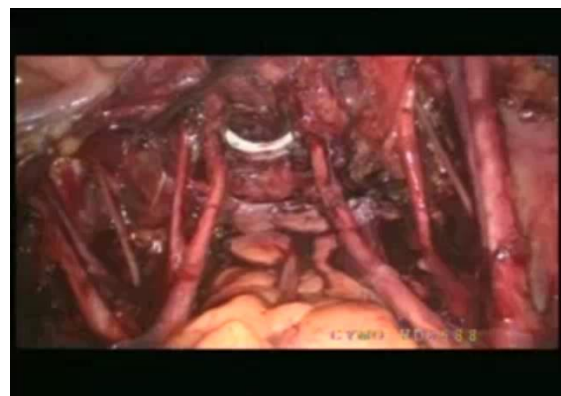


Figure 4:

Average number of pelvic nodes dissected out was 14 (range 10 to 18) on each side; Three patients required conversion to open procedure; bleeding was the cause for conversion in one patient and rectal injury was the cause for conversion in 2 patients; the mean in hospital stay was 5 days (3-8 days) 4 patients presented with delayed postoperative complications; two patients developed ureteric fistula presenting after 15 days were managed by ureteric stenting; one patient with vesico vaginal fistula required open repair; one patient developed port site hernia two years later that was corrected surgically Post op histo pathology was squamous cell carcinoma with varying degree of differentiation in different cases; mean pathological T staging was T1b2 . 48 patients had positive nodes with mean number of positive nodes – 5 including both the sides (range 1 -12); 52 patients had lympho vascular invasions in the primary lesion; Patients with poorly differentiated tumor histology, deep stromal invasion, lymphovascular invasion and positive nodes were administered adjuvant RT. Long term results viz recurrence rate and survival rate are under study

reported an operative mortality rate of 18% and major morbidity 31%.^[3] The procedure entails removal of the Uterus and parametrium (Broad, Round, Cardinal and Utero-Sacral ligaments) and the upper one-third to one-half of the vagina, with bilateral pelvic node dissection. A good knowledge of pelvic anatomy, meticulous sharp dissection and mobilization of the bladder and rectum is required for this procedure.^[2,3] The five-year survival rate for primary surgical radical abdominal hysterectomy is 83% and this is comparable to radiation therapy which has a survival rate of 74%.^[4]

Acceptance of a new surgical technique in the practice of oncology requires that technical feasibility be demonstrated and morbidity and mortality associated with it are not prohibitively high, also, short and long-term survival should be comparable to that of the accepted standard therapy. Techniques used to perform radical hysterectomy with aortic and pelvic lymph node dissection laparoscopically are well-described.^[5] Much less is known about the morbidity and mortality associated with this procedure and even less has been published regarding short or long-term survival following laparoscopic radical hysterectomy (type III), aortic and pelvic lymph node dissection.^[6] Laparoscopic radical hysterectomy (LRH) with para-aortic and pelvic node dissection was first performed by Nehzat et al in 1989.^[6] There are two types of Laparoscopic radical hysterectomy, the first type being the total laparoscopic radical hysterectomy in which the entire process of radical hysterectomy is carried out laparoscopically, however closure of the vaginal vault could also be done through the vaginal route. Laparoscopic assisted radical vaginal hysterectomy (LARVH) is the second type and it involves mobilisation of the ureters ureteric dissection, lymphadenectomy and development of the paravesical and paraarectal spaces laparoscopically, while the rest of the procedure is completed vaginally as classically described by Schauta.

Minimal access surgical procedures are now proposed for many open procedures and have largely replaced the open approach for many common surgical procedures such as appendectomy and cholecystectomy. The obvious reduction in trauma to the abdominal wall and pelvic organs confers a number of potential advantages, including a shorter hospital stay, less pain, faster recovery time and more rapid return to normal function.^[7,8]

Radical surgeries in general are associated with more morbidity and in some cases greater mortality than non-radical surgeries, the reason for this can be attributed to the extensive nature of tissue dissection and disruption of radical procedures. This is further increased in open surgery where access to tissues is more. Laparoscopic procedures in general are associated with less tissue disruption, less pain, less infection and adhesion formation because of the reduced incision, little or no tissue handling and use

Table 1: Summary of results

Total Number	74
Age Stage	48.6 years (range 30 – 56 years)
IB1	34
IIA1	41
Duration of surgery	154 min (range 120 to 260 min)
Blood loss	112 ml (range 20 – 400ml)
Conversion	3
Complications	
Per op	
Bleeding	1
Rectal injury	2
Post op	
Ureteric fistula	2
Vesicocaginal fistula	1
Port site hernia	1
In hospital stay	5 days (3-8 days)

DISCUSSION

Worldwide there are 500,000 new cases of cervical cancer reported annually making it the second most common cancer in women, with 80% of cases from developing countries.^[1]

Radical abdominal hysterectomy (RAH) is indicated in patients with diagnosed Cervical cancer with FIGO stage IA2 to IIA selected patients with stage II adenocarcinoma of the endometrium in whom radical surgery is feasible, upper vaginal carcinoma, uterine or cervical sarcomas and other rare malignancies confined to the cervix, uterus and/or the upper vagina.^[2]

The first radical hysterectomy was performed by Clark at Johns Hopkins's Hospital in 1895. Wertheim added removal of the pelvic lymph nodes and parametrium to what Clark did and in 1905, he

of energy sources like diathermy. All these contribute to a better outcome particularly for patients with cancer. Presently medical practice is geared towards efficiency and patient satisfaction which is also one of the qualities of laparoscopy. It has the advantage of being used to determine patients eligibility for continuation of radical surgery, if prior diagnostic laparoscopy contraindicates radical surgery as may be seen in cases of under staging.

CONCLUSION

In our experience, laparoscopic radical hysterectomy is a safe and feasible alternative to open surgery for patients with early cancer cervix and shows equally good oncological outcome and lesser overall morbidity.

REFERENCES

1. Okonofua F E: HPV Vaccine and prevention of cervical cancer in Africa. African journal of reprod Health. Vol 11, No 2, Aug 2007, Pg 7-9.
2. Mann W J: Radical Hysterectomy; Up to date for patients. View in www.uptodate.com/patient/content/topic.do?topickey=gy_surg/444.
3. Sundborg M J; Radical hysterectomy: In e medicine view in <http://www.emedicine.com/med/topic3343.htm>
4. Landoni F,Maneo A, Colombo A, Placa F, Milani F, Perego P, et al . Randomised Study of radical surgery versus radiotherapy for stage 1b-11a cervical cancer. Lancet 1997; 350:535-540.
5. Spirtos M D, Schlaerth J B and Ballon S C. Laparoscopic radical hysterectomy with aortic and pelvic lymphadenectomy, in Gershenson D and Fowler J (eds): Operative Techniques in Gynecological Surgery 1997,2,200-218.
6. NezhatF,Datta S, Nezhat C, Yildrin G, Nezhat C; Role of laparoscopy in hysterectomy; Urogynecology, US Obstetrics and Gynecology 2007, Pg 68-70
7. Mishra R K. Complications of minimal access surgery; In Textbook of practical laparoscopic surgery. 1st edJaypee Publishers Delhi 2008; Pg 388-389.
8. Laparoscopy may be the best operation for early cervical cancer. Reuters Health Information June 29, 2007. Reuters limited.

How to cite this article: Balamurugan SG, Kalpana B, Kumar ANL, Fanny AG. Laparoscopic Radical Hysterectomy for Early Stage Cervical Cancers – A Single Team Experience. Ann. Int. Med. Den. Res. 2019; 5(5):SG20-SG23.

Source of Support: Nil, **Conflict of Interest:** None declared