

Analysis of Factors in Establishing Microvascular Surgery in Oral Cancer Patients in Odisha: A 12 Year Study

Bibhuti B. Nayak¹, Sanjay Panda², Manjunath NML³

¹Associate Professor, Department of Plastic Surgery, SCB Medical College, Cuttack.

²Professor, AH Cancer Hospital, Cuttack.

³Consultant Surgical oncologist, HCG Panda Cancer Hospital.

Received: March 2019

Accepted: March 2019

Copyright:© the author(s), publisher. It is an open-access article distributed under the terms of the Creative Commons Attribution Non-Commercial License, which permits unrestricted non-commercial use, distribution, and reproduction in any medium, provided the original work is properly cited.

ABSTRACT

Background: Microvascular reconstruction is now widely available in India. However the situation was quite different two decades back. **Methods:** The procedure was available only in a very few centers located mostly in the metro cities. It was considered a very complex and difficult surgery requiring height degree of skill and precision. Spreading or establishing this technique in smaller cities was filled with lot of challenges and was never an easy task. **Results:** The most difficult part was to gain the confidence of local oncosurgeons who refused to believe that this technique could be executed in smaller centers and cities. This article is a study of the factors and challenges faced by the author to establish this technique in the state of Odisha. **Conclusion:** It took a couple of years to convince the oncosurgeons to initiate the procedure. Another five years to consolidate. Since 2010 its a well established technique in the state of Odisha. The microvascular surgeons trained under the author and from other centers outside the state have spread the procedure to many more centers in Odisha. From an occasional procedure in 2003, Microvascular reconstruction has become a routine procedure in Odisha today.

Keywords: Challenges, microvascular, reconstruction, Odisha

INTRODUCTION

Oral cavity reconstruction is the most challenging endeavor for a reconstructive surgeon. It has all the scope to test a reconstructive surgeon's capabilities, as it comprises the important facets of an ideal reconstruction. The goals of an ideal reconstruction are the best functional, anatomical and cosmetic outcomes. Pedicled flaps are time tested and well established modalities of oral reconstruction, exemplified by Pectoralis major Myocutaneous flap. Inferior cosmetic outcomes, technical inability due to lack of reach to the desired defect, donor site morbidity are few facts which called for a better reconstructive modalities.^[1] Free tissue transfers achieve the goals far more superiorly in experienced hands.^[2]

Alexis Carrel introduced vascular anastomosis for which, he was awarded with Nobel Prize in the year 1912.^[3,4] After this, many surgeons started doing vascular anastomosis and limb replantation surgery. With the advent of operating microscope in the year 1921, and also introduction of fine instruments for

ear and eye surgeries, era of small vessel anastomosis started. Microvascular reconstruction (MVR) was initiated in many centers around the world in the end of 1950's. In India initial microvascular reconstructions were mainly in the trauma related wounds. The MVR was implemented in oral cancer patients in 1980's.^[4] The aim of the present article is to elaborate on the problems of establishing and implementing MVR in a resource-constrained region like Odisha.

In the year 2003, none of the hospitals in Odisha were offering microvascular reconstruction in the state where this study was done. One of the authors of this article got training in a different state in the country with an aim of establishing a unit of microvascular surgery in the hometown. The problems faced by him in establishing the program included lack of awareness, affordability, lack of family support, lack of motivation among patients and their relatives and presence of comorbidities. Physician factors included fear of flap loss, increase in the treatment cost, lack of initiative for the change, non-availability of expert reconstructive surgeon. Many surgeons believed that this was extremely complex procedure possible only in select few metros. Socioeconomic issues included lack of financial support from governmental schemes for reconstructive surgery, lack of awareness among higher authorities, considering reconstructive

Name & Address of Corresponding Author

Dr. Bibhuti B. Nayak
Associate Professor,
Department of Plastic Surgery,
SCB Medical College,
Cuttack.

surgery as a very complex procedure possible only in some metros with highly sophisticated back up services, as an aesthetic procedure [Table 1]. This article depicts the author's struggle to surpass these factors and establish and also motivate others to start the service.

MATERIALS AND METHODS

The data was collected from a prospectively maintained case details with record of reasons for not opting micro vascular reconstruction whenever pedicled flap was chosen. All the patients who were managed between 2004 and 2016 were included for the study. Total of 1506 patients were included. All the patients were diagnosed to have oral cavity squamous cell carcinoma. Patients with incomplete clinical details were excluded. All the patients were managed in a single cancer center, managed by a team of experts. Clinical details were discussed in tumor board and treatment decisions recorded, including the nature of reconstructive technique. Patients were counseled by trained staff so as to prepare them and the family for possible problems and expected outcomes, alternative techniques and financial implications. The data was analyzed using SPSS software.

RESULTS

Table 1: Reasons for not opting Micro vascular reconstruction (Multiple factors in a single patient considered)

Factors for not considering Micro vascular reconstruction in 462 patients	No of patients (n= 462)
Not feasible (Technical)	9
Financial issues	368
Anesthetic reasons and comorbidities	42
Reluctance from surgical oncologist	183
Lack of awareness among patient and relatives	249
Lack of resources in the hospital	56

Table 2: Types of reconstructions

Type of reconstruction	No of patients
Primary closure	62
Local rotation flaps/Skin grafts	37
Pedicled flaps	462
Free flaps	945
Total	1506

1506 Patients underwent oral cavity reconstruction following oral cavity cancer resections. Table 2 shows the various reconstructive modalities and number of patients who underwent the procedure. Mean age of patients was 50 years and male to female ratio was 4:1. Figure 2 depicts the changing patterns of reconstructive modalities over a period of time. As it can be appreciated from the graph, there is gradual increase in the number of micro vascular flaps and a corresponding reduction in pedicled and

other locoregional flaps. Among the micro vascular flaps, radial free flap was the most common procedure [Figure 1] and common indications included carcinoma buccal mucosa, tongue and upper alveolus. Next common procedure was free fibula flap, which was done most frequently for lower alveolar tumors. [Table 3] depicts the complications and overall 30-day flap survival rates for the reconstructive surgeries.

Table 3: Various complications in patients who underwent free tissue transfers in two columns to show the comparisons that results have improved with experience

Complications	Numbers (percentage)	
	2003 to 2010 (n=139)	2011 to 2016 (n=806)
Complete flap loss	5 (3.6)	7 (0.87)
Partial flap loss	16 (11.5)	14 (1.7)
Parotid fistula	10 (7.2)	12 (1.5)
Bleeding, Hematoma	25 (18)	23 (2.8)
Re-explorations (number)	23 (16.5)	28 (3.5)
Surgical site infections	12 (8.6)	8 (1)
Wound skin necrosis	6 (4.3)	7 (0.9)
Major swallowing problems	3 (2.2)	5 (0.6)
Major speech problems	8 (5.7)	7 (0.9)

Table 4: Factors helping in reducing the cost for micro vascular reconstruction

1	Reduction in overall operating and hence anesthesia time
2	Anticoagulants – Not used
3	Reduced complications due to increase in expertise and experience resulting in overall decrease in prices
4	High volume with team efforts also reduced in overall price per patient
5	Reduction in medication use including anesthesia drugs, antibiotics, and supportive drugs
6	Reduced number of intensive care and hospital stay

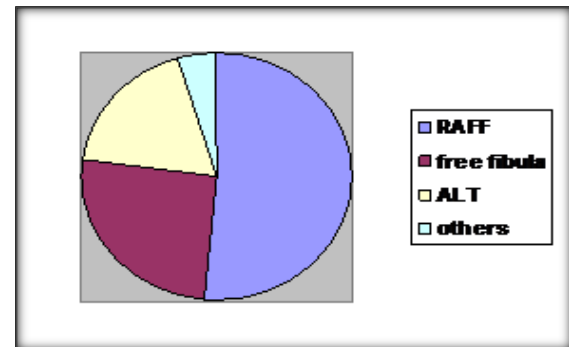


Figure 1: Spectrum of various flaps

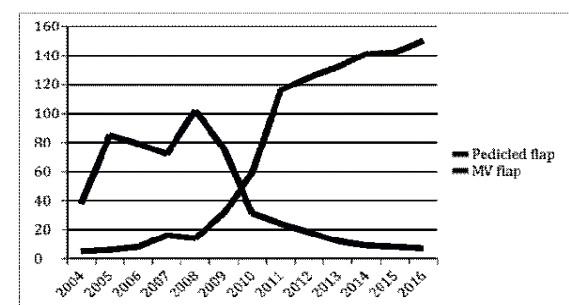


Figure 2: Trends of reconstructive surgery for oral cancer patients 2004 to 2016 (MV – Micro vascular) n=1506

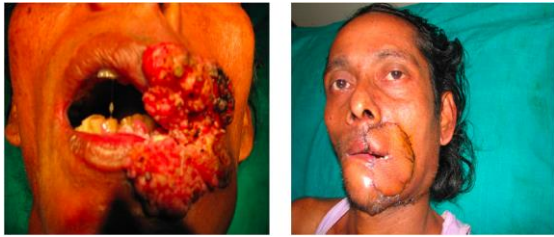

Figure 3: Free Radial forearm free flap reconstruction

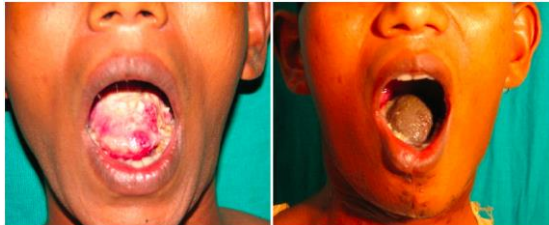

Figure 4: Tongue and floor of mouth reconstruction using Anterolateral thigh flap

DISCUSSION

Any new surgical procedure is seen with skepticism and has to undergo the test of time for its survival and ultimate establishment. [Table 1] shows the factors associated with not considering MVR over pedicled flaps. Surgeon who has strong belief and mastery in a particular procedure has to persevere and understand the elements of resistance so as to establish the technique as a standard of care for the betterment of patient. Oral cavity cancers are the most common cancers in India and more so in some states.^[5] Pedicled flaps are commonly used to reconstruct the oral cavity defects. Pectoralis major Myocutaneous flap is considered as workhorse for the head and neck reconstruction.^[6,7] Micro vascular reconstruction is a well-established technique for the reconstruction of oral cavity defects. Initial problems of technical insufficiencies, lack of skills and motivation lead to slow progress and finally in the modern surgical era, it has all the technical accomplishment and required skill for routine practice.

In the year 2003, none of the hospitals in the state were offering micro vascular reconstruction for oral cavity defects following oncological resections. Lack of financial support and trained staff were the main factors. Micro vascular reconstruction requires technical support in terms of surgical instruments and operating microscope with additional burden on the hospital establishment, trained staff for assistance and monitoring the flaps. Most of the governmental schemes do not support the finance for the micro vascular reconstruction. Author of the present article, trained a team for micro vascular reconstruction, which included a technical assistant, a staff nurse, a person to monitor and take care of the wound, patient counselor and a manager. In the years 2003 – 04, mainly pedicled flaps were used and most of which could have received micro vascular

reconstruction. Apart from answering the mentioned factors for not accepting micro vascular reconstruction in oral cancer, the replantation and free flaps in posttraumatic wounds were presented in all forums to develop confidence among the target group. Gradually the hospital authorities could be convinced about the volume and hence they invested in operating microscope and surgical instruments. Patient counselor played a major role in convincing the patient about the advantages of the procedure. It was shown that apart from cosmetic benefits, it helps in early recovery and early initiation of adjuvant treatment leading to financial savings and cost effectiveness.^[8,9]

Lack of family support and motivation were the factors apart from financial concerns. Again the medico-social worker and counselor helped in convincing the patient's family about their role in the patient management. Patient comorbidities and age of the patient were other factors as the procedure involved more anesthetic hours, need of anticoagulation and re-explorations. Through good surgical techniques, increasing number of free flaps and gaining more expertise and experience of the whole team and it was shown that whole micro vascular reconstruction could be completed in the same time as for pedicled flaps. Average time taken for radial free flap was less than 2 hours and even composite double flaps could be completed in an average 4 hours. Except in the initial few patients, anticoagulation was not used in the patient management. Medications for the comorbid conditions could be initiated with usual course and no perioperative mortality was observed because of patient comorbidities. All the factors, which helped in reducing the overall expenditure, are summarized in the [Table 4].

Resistance from the primary treating oncologist while considering micro vascular reconstruction was because of skepticism about the new procedure and expected complications. Micro vascular reconstruction was glorified as a complex technique, which could be mastered with long learning curve and involved highest level of expertise. Associated complications were the main points of discussion rather than the procedure itself. Concerns were raised about the possible delay in adjuvant treatment because of the complications. Patient had to be counseled regarding the extra financial burden they had to bear because of flap related complications. After completing a decent series of free flaps, there was a newfound confidence and preference for this procedure. More and more oncosurgeons started involving the team in their centers as well. Slowly over a period of time author could convince ablative surgeons about the safety and feasibility of the procedure [Table 3], and it could be done in the same way as pedicled flaps with superior functional, anatomical and cosmetic results [Figure 3,4]. It can

be seen from [Table 3] that the flap survival and rate of reexploration have improved over time.

Reconstruction in the setting of previously treated oral cancer patients with second primaries or recurrences and in post irradiation setting is more challenging. It is the limiting factor in the curative management of these patients. Often these patients had to be sent for palliative radiotherapy or chemotherapy or even best supportive care, because the surgical defect could not be reconstructed. These patients were managed by micro vascular reconstruction and they could be offered curative treatment and this is all the more important in patients without nodal metastasis because of better prognosis in comparison to node positive disease. This aspect again convinced and encouraged ablative surgeons to opt for the MVR.

Lack of skilled personnel to perform micro vascular reconstruction was also a main factor for not practicing the same in the home state. By looking at the results from the author's institution, other hospitals also started offering these modalities for the deserving patients. Also surgeons trained under the author could establish independent units elsewhere and continued to expand the program in different hospitals.

Most of governmental schemes for low socioeconomic patients do not support reconstructive modalities with adequate finances. Main reason is that the reconstructive part of oncological management is considered as aesthetic issue and more thrust is on oncological outcome. Through consistent efforts, over a period of time it was realized that unless patient gets good reconstruction, adjuvant treatment gets delayed and with poor oncological outcomes. Also in the recurrent and residual disease setting, where locoregional flaps are exhausted, micro vascular technique is the only option for reconstruction.

In spite of achieving many milestones, problems in expanding the program continue. The burden is huge, resources are limited, but the mastery of technique and establishing a team to both continue the ongoing program and establishing other centers are the key to success.

CONCLUSION

Micro vascular reconstruction is the standard of care in the management of oral cavity cancer patients and more readily available in Odisha than a decade and half back; still more than approximately 70% health centers in Odisha are not equipped to offer micro vascular service. Demand for micro vascular surgery is clear, trained surgeons are available and through good surgical technique, optimal utilization of resources, and team efforts satisfactory results can be achieved. As the technique becomes more easily available, more number of patients would undergo the procedure with overall improvement in the

oncological outcome and quality of life secondary to functional and aesthetic benefits.

REFERENCES

- Schuller DE. Limitations of the pectoralis major myocutaneous flap in head and neck cancer reconstruction. *Arch Otolaryngol Chic Ill* 1960. 1980 Nov;106(11):709-14.
- McCroly AL, Magnuson JS. Free tissue transfer versus pedicled flap in head and neck reconstruction. *The Laryngoscope*. 2002 Dec;112(12):2161-5.
- Tamai S. History of microsurgery--from the beginning until the end of the 1970s. *Microsurgery*. 1993;14(1):6-13.
- Tamai S. History of microsurgery. *Plast Reconstr Surg*. 2009 Dec;124(6 Suppl):e282-294.
- Globocan 2012 - Home [Internet]. [cited 2017 Sep 9]. Available from: <http://globocan.iarc.fr/Default.aspx>
- Bussu F, Gallus R, NAVACH V, BRUSCHINI R, TAGLIABUE M, Almadori G, et al. Contemporary role of pectoralis major regional flaps in head and neck surgery. *Acta Otorhinolaryngol Ital*. 2014 Oct;34(5):327-41.
- Liu M, Liu W, Yang X, Guo H, Peng H. Pectoralis Major Myocutaneous Flap for Head and Neck Defects in the Era of Free Flaps: Harvesting Technique and Indications. *Sci Rep* [Internet]. 2017 Apr 7 [cited 2017 Sep 9];7. Available from: <http://www.ncbi.nlm.nih.gov/pmc/articles/PMC5384233/>
- Gao LL, Basta M, Kanchwala SK, Serletti JM, Low DW, Wu LC. Cost-effectiveness of microsurgical reconstruction for head and neck defects after oncologic resection. *Head Neck*. 2017 Mar;39(3):541-7.
- Deganello A, Gitti G, Parrinello G, Muratori E, Larotonda G, Gallo O. Cost analysis in oral cavity and oropharyngeal reconstructions with microvascular and pedicled flaps. *Acta Otorhinolaryngol Ital Organo Uff Della Soc Ital Otorinolaringol E Chir Cerv-facc*. 2013 Dec;33(6):380-7.

How to cite this article: Nayak BB, Panda S, Manjunath NML. Analysis of Factors in Establishing Microvascular Surgery in Oral Cancer Patients in Odisha: A 12 Year Study. *Ann. Int. Med. Den. Res*. 2019; 5(3):SG14-SG17.

Source of Support: Nil, **Conflict of Interest:** None declared