

# A Novel Technique for Protection of Facial Nerve during Parotidectomy.

Santanu Sinha<sup>1</sup>, Abhimanyu Basu<sup>2</sup>, Soumen Das<sup>3</sup>, Radha Raman Mondal<sup>4</sup>, Sujitesh Saha<sup>5</sup>

<sup>1</sup>Associate Professor, Department of General Surgery, IPGMER and SSKM Hospital, Kolkata – 700020.

<sup>2</sup>Professor, Department of General Surgery, IPGMER and SSKM Hospital, Kolkata – 700020.

<sup>3</sup>In-charge, Colorectal and Peritoneal Cancer Services and Head of Surgical Oncology, Netaji Subhas Chandra Bose Cancer Hospital, Nayabad, Kolkata, India

<sup>4</sup>M.S. Resident, Department of General Surgery, IPGMER and SSKM Hospital, Kolkata – 700020.

<sup>5</sup>Associate Professor, Department of Paediatric Surgery, IPGMER and SSKM Hospital, Kolkata – 700020.

Received: April 2019

Accepted: May 2019

**Copyright:** © the author(s), publisher. It is an open-access article distributed under the terms of the Creative Commons Attribution Non-Commercial License, which permits unrestricted non-commercial use, distribution, and reproduction in any medium, provided the original work is properly cited.

## ABSTRACT

**Background:** Identification and protection of Facial Nerve is of prime importance during surgery of parotid glands. Several techniques are available in literature to identify and preserve FN. We present here a case series with dissection of FN in a novel technique during parotidectomy which has significantly lowered the morbidity due to injury of the FN. **Methods:** All data, from all the patients who underwent Parotidectomy in our unit (conducted or supervised by a single surgeon) in the Department of General Surgery, IPGMER and SSKM Hospital, Kolkata, between March 2014 to March 2019, using our novel technique for identification and protection of FN, was retrospectively analysed. Outcome measurement was expressed in terms of type of surgery, duration, estimated blood loss, any intra-operative or post-operative complications, length of hospital stay, duration of drain in place, Histopathological (HPE) reports, size of the tumour, margin and lymph node status, Facial Nerve weakness and other complications. **Results:** Total 13 patients underwent Parotidectomy (Total or Superficial) following our technique of identifying and protecting Facial Nerve (FN). Four of them had temporary FN paresis in immediate post-op period. None of the patients had FN paresis on follow-up at 1 year. **Conclusion:** The novel technique described in our study for identification and protection of FN is a promising technique for Parotid Surgery.

**Keywords:** Facial nerve, Parotidectomy.

## INTRODUCTION

Parotidectomy operation either (superficial or total) is considered a difficult procedure by most general surgeons due to fear of injury to the facial nerve. An inexperienced surgeon tries to identify the facial nerve at a plane which is much more superficial than it ought to be. This increases the operating time as well as the chance of Facial Nerve (FN) injury is not diminished. For benign and low grade parotid tumours, the goal of the surgery is to remove the gland without injuring the FN.<sup>[1]</sup> Several techniques are available to identify and preserve FN including Prograde Approach (FN trunk to branches), Retrograde approach (FN branches to trunk), using Conley's Pointer, upper border of the posterior belly of the digastric muscle, squamotympanic fissure, the styloid process (the nerve is superficial to it) and the mastoid process (can be drilled and the nerve identified more proximally).<sup>[2]</sup> However, none of the approaches correctly pinpoints the site or plane of

the FN during dissection. We present here a case series with dissection of FN in a novel technique during parotidectomy which has significantly lowered the morbidity due to injury of the FN.

## MATERIALS AND METHODS

### Selection of Cases:

We reviewed all data retrospectively from all the patients who underwent Parotidectomy using this novel technique for identification and protection of FN in our unit (conducted or supervised by a single surgeon) in the Department of General Surgery, IPGMER and SSKM Hospital, Kolkata, between March 2014 to March 2019. All primary and recurrent tumours operated due to benign causes and low-grade malignancies were included. High grade malignancies were excluded from our study. All patients underwent relevant clinical examination, imaging and fine needle aspiration biopsy (FNAB) to confirm diagnosis. After routine pre-operative work-up and consent, patients underwent the surgery under general anaesthesia.

### Surgical Technique:

### Name & Address of Corresponding Author

Dr. Sujitesh Saha  
Associate Professor,  
Department of Paediatric Surgery,  
IPGMER and SSKM Hospital,  
Kolkata – 700020

All operations were started with a modification of standard facio-mastoid-cervical incision (Modified Blair's) described as follows:

1. Incision is always started from the anterior jugular vein in the upper skin crease up to the mastoid and we believe that this modification gives two advantages. Firstly, it gives a clear field due to absence of any blood trickling from above as is found in conventional technique where the incision is started from above i.e. the facial part first. Secondly, this facilitates dissection in a clear field and easier and faster identification of the posterior belly of digastric. This structure is frequently hidden under lymph node. The posterior belly of digastric, when followed upwards, is an important pointer to the facial nerve.
2. The facial part of the incision is made next and deepened up to the junction of bony and cartilaginous part of external auditory canal.
3. The mastoid part of the incision is made last. The Facial nerve tends to lie deep to this part of the incision.
4. Next, we follow a technique not hitherto described before. A blunt artery forceps is introduced from the lower part of the facial incision at the level of the junction of the bony & cartilaginous part of external auditory canal (exposed by previous dissection) & slowly the tip is manipulated up to the upper part of cervical incision staying in the same plane. The overlying fascia, fibrous strands and parotid tissue (mainly the lower part & tail of the parotid) is gently teased off till the level of the artery forceps or till a bleeding vessel is encountered. In our experience the facial nerve always lies below this plane of the artery forceps. The importance of the bleeding vessel lies in the fact that it acts as a safety buffer. This artery has been described as the Stylomastoid artery and is probably the most accurate marker of the facial nerve in our experience. Use of monopolar electrocautery was preferably avoided while cauterizing this vessel as the nerve invariably lies within 2-5 mm of this artery.

Once the main trunk was identified, all the peripheral branches were dissected out in prograde manner (from main trunk to the pes) in standard manner. Deep lobe resection was done in standard manner if indicated. In superficial parotidectomy, our aim was to achieve a R0 resection as well as preservation of parotid duct. For total parotidectomies, FN trunk and selected branches were preserved which were not involved grossly by the tumour.

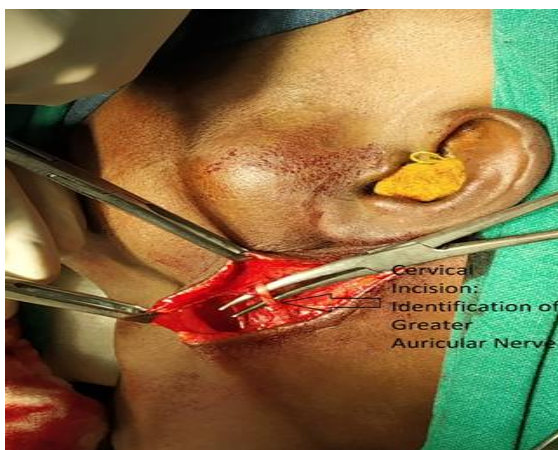

Figure 1: Initial Cervical Incision

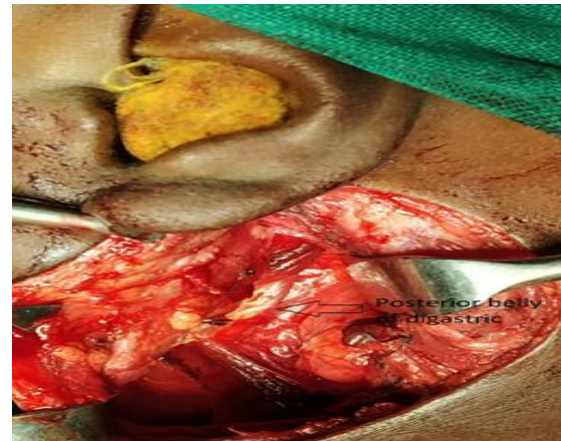

Fig. 2: Exposure Of Posterior Belly Of Digastric

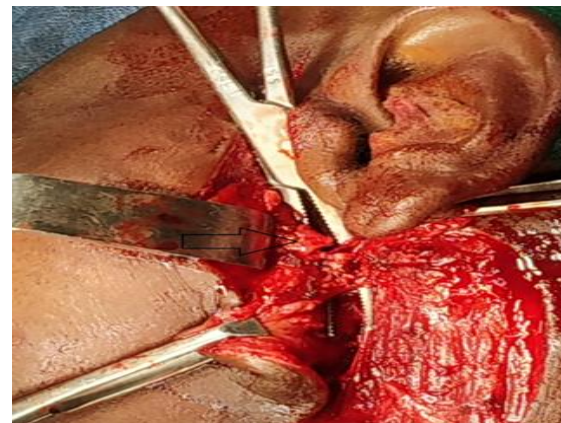


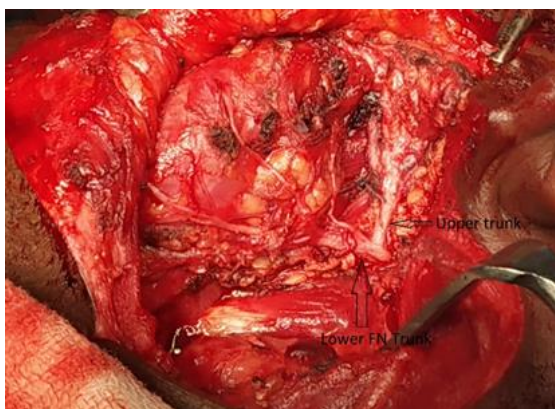
Figure 3: Artery forceps introduced from the level of junction of the bony and cartilaginous part of external auditory canal into the neck

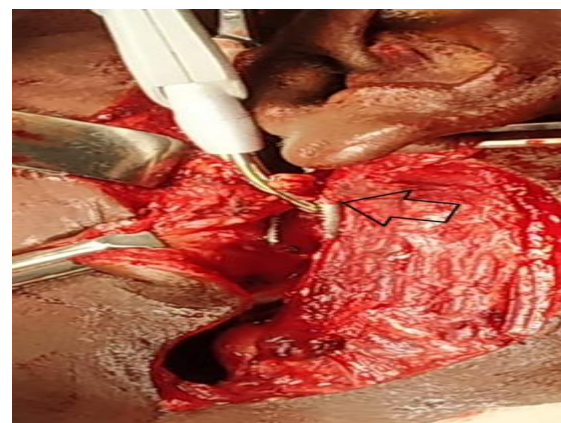
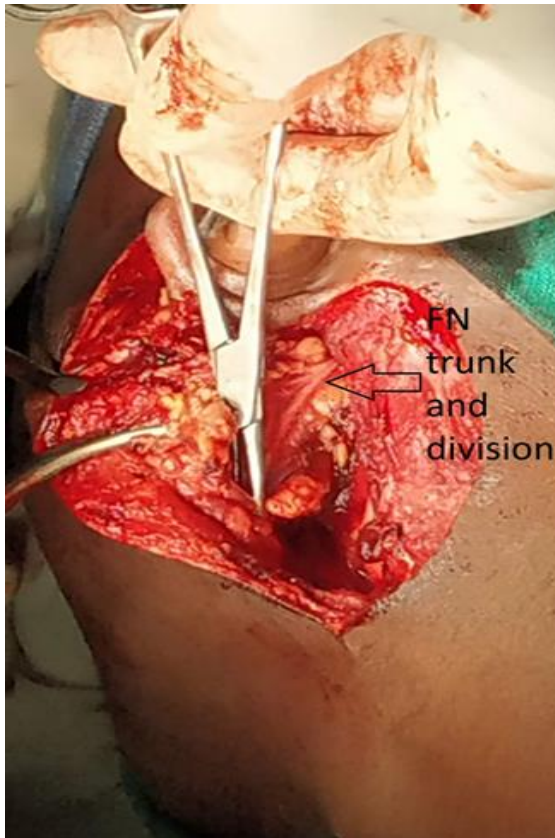
Figure 4: Tissue Above Artery Forceps Being Incised



**Figure 5: The Facial Nerve Lies Just Below The Forceps**



**Figure 6: The Facial Nerve And Its Branches At The End Of Operation Lies Exposed**

All cases were performed by a team consisting of the visiting surgeon (VS) and at least one surgical postgraduate resident. No magnification was used. Post-operatively, drains were removed after 48-72 hours with output <30 ml/day and patients were discharged in clinically stable condition.

#### **Measurement of Outcome:**

All the patients were assessed at the time of discharge, after 30 days and after 1 year. Type of surgery, duration, estimated blood loss, any intra-operative or post-operative complications, length of hospital stay, duration of drain in place,

Histopathological (HPE) reports, size of the tumour, margin and lymph node status were documented. FN weakness was defined as paresis to any branch of the FN noticed by a resident, nurse, the patient, or the attending physician during follow-up visit. FN status was expressed with 'Facial Nerve Grading Scale 2.0' (FNGS 2.0)<sup>3</sup>.

## **RESULTS**

A total 13 patients (9 male and 4 female) underwent parotidectomy (either superficial or total) with the novel technique described above. The average age of the patients  $\pm$  SD was  $43 \pm 15$  years. Histopathologically, we had 61.53% (8 of 13) pleomorphic adenomas, 15.38% (2 of 13) Warthin's tumours, 1 case of basal cell adenomas, 1 acinic cell carcinomas, 1 case of low-grade mucoepidermoid carcinoma.

In our series, 84.6% (11 of 13) patients underwent superficial parotidectomies and 2 patients underwent total parotidectomies. The mean  $\pm$  SD operating time was  $126.2 \pm 33.4$  minutes (90 minutes to 200 minutes), mean  $\pm$  SD blood loss was  $47.3 \pm 25.6$  ml. The average length of post-operative hospital stay was 4 days (SD  $\pm$  2.3 days), and the mean  $\pm$  SD duration of postoperative drains was  $2.4 \pm 6$  days. The total wound complication rate was 23.08% (3 out of 13, including 1 Frey's Syndrome and 2 seromas. No Sialocele / Parotid Fistula / other complications were found.

The mean  $\pm$  SD tumour size was  $4.3 \pm 1.4$  cm (as found in histopathological report).

Assessment of Facial Nerve with FNGS 2.0 score revealed 30.8% (4 of 13) patients had temporary neuropraxia immediate post-operatively. Overall, 1 patient had Grade III FNGS 2.0 FN dysfunction score, 3 patients had Grade II FNGS 2.0 score immediate post-operative period. After 1 month, only 1 patient had FNGS 2.0 score. There was no residual FN neuropraxia on assessment after 1 year. No patient sustained temporary or permanent injury to the main trunk of the FN.

## **DISCUSSION**

The technique described in study to safeguard the FN during dissection shows a promising result in our case series. Incidence of global facial paresis had been reported as high as 77.2% in an study by Infante-Cossio et al.<sup>[4]</sup> In 1 year follow-up, they had reported no patients to have FN paresis, which is comparable to our result. However, in our study, immediate post-operative FN paresis was only 30.8%, thus clearly showing ours as a promising technique.

The facial nerve lies in a deeper plane than is frequently sought. The traditional pointers to the nerve like the tragal pointer fail to locate the depth at which the nerve lies. We have considered the various

anatomical landmarks and have combined it together to evolve a more reproducible technique to appreciate the depth at which the nerve lies. The dissection of the posterior belly of Digastric and tracing it upwards as far as possible through the cervical incision is greatly facilitated by starting the operation from the cervical route as it provides a bloodless field without blood trickling down from above. In addition, we have given more importance to the Stylomastoid artery and consider it to be the sentinel vessel guarding the facial nerve. Any abnormal spurting vessel encountered in the mastoid region and specially if it is deep to the plane of the introduced artery forceps should alert the surgeon to the Facial nerve lurking nearby. But perhaps the most significant modification has been the introduction of the artery forceps from above downwards as described in our technique. The surgeon can be confident that the bulk of tissue lying above the forceps does not contain the facial nerve and thus can resect the tissue above the forceps keeping in mind that the facial nerve lies below.

When compared to extracapsular dissection, McMullen et al., in their case series of 40 patients, had shown only 1 case of FN paresis and no cases of Frey's Syndrome.<sup>[5]</sup> We admit that extra-capsular dissection is superior than our technique in terms of FN paresis. However, extracapsular dissection has specific indications, cannot be done in all cases and needs more expertise. Limited Parotidectomy had been shown superior than Complete Superficial Parotidectomy by some authors<sup>6</sup>, however, none of them could show superiority in protection of FN.

The Facial nerve remains an enigma to the General Surgeon still now and Parotidectomy operation is at times even avoided for fear of nerve injury. Relatively inexperienced surgeons tend to mistake thick fascial strands or fibrous bands for facial nerve and enter the substance of the parotid or even the tumour by following those structures masquerading as the facial nerve, thereby, causing spillage or increasing the chances of injury to the facial nerve branches. This not only increases the complication rates but also results in significantly increased operative time. The modifications designed and followed by us will hopefully make the procedure more standardized and identification of the facial nerve more predictable.

## CONCLUSION

The novel technique described in our study for identification and protection of FN is a promising technique for Parotid Surgery.

## REFERENCES

1. Kligerman MP, Song Y, Schoppy D, et al. Retrograde Parotidectomy and facial nerve outcomes: A case series of 44 patients. *Am J Otolaryngol.* 2017;38(5):533-536. doi:10.1016/J.AMJOTO.2017.05.003

2. Williams NS, O'Connell PR, McCaskie AW. *Bailey & Love's Short Practice of Surgery.* 27th ed. (Williams Norman, O'Connell P Ronan MA, ed.). CRC Press; 2018.
3. Vrabc JT, Backous DD, Djalilian HR, et al. Facial Nerve Grading System 2.0. *Otolaryngol Neck Surg.* 2009;140(4):445-450. doi:10.1016/j.otohns.2008.12.031
4. Infante-Cossio P, Gonzalez-Cardero E, Garcia-Perla-Garcia A, Montes-Latorre E, Gutierrez-Perez J-L, Prats-Golczer V-E. Complications after superficial parotidectomy for pleomorphic adenoma. *Med Oral Patol Oral Cir Bucal.* 2018;23(4):e485-e492. doi:10.4317/medoral.22386
5. McMullen CP, Smith R V., Ow TJ, Tassler A, Schiff BA. Minimal Margin Extracapsular Dissection. *Ann Otol Rhinol Laryngol.* 2016;125(11):912-917. doi:10.1177/0003489416661344
6. Eviston TJ, Yabe TE, Gupta R, Ebrahimi A, Clark JR. Parotidectomy: surgery in evolution. *ANZ J Surg.* 2016;86(3):193-199. doi:10.1111/ans.13212

**How to cite this article:** Sinha S, Basu A, Das S, Mondal RR, Saha S. A Novel Technique for Protection of Facial Nerve during Parotidectomy. *Ann. Int. Med. Den. Res.* 2019; 5(4):SG12-SG15.

**Source of Support:** Nil, **Conflict of Interest:** None declared