

# Endoscopic Thyroidectomy for Benign Thyroid Lesions: A Prospective Study.

Sanjay Pal<sup>1</sup>, Ram Khare<sup>1</sup>, Raj Gajbhiye<sup>2</sup>

<sup>1</sup>Resident, Department Of General Surgery, Government Medical College Nagpur.

<sup>2</sup>Professor and HOD, Department Of General Surgery, Government Medical College Nagpur.

Received: April 2019

Accepted: April 2019

**Copyright:** © the author(s), publisher. It is an open-access article distributed under the terms of the Creative Commons Attribution Non-Commercial License, which permits unrestricted non-commercial use, distribution, and reproduction in any medium, provided the original work is properly cited.

## ABSTRACT

**Background:** Thyroidectomy is one of the most common operations performed throughout the world, with solitary thyroid nodules being one of the more common indications for surgery. Though conventional open thyroidectomy is considered extremely safe and remains the treatment of choice, it is associated with an undesirable scar. Endoscopic thyroidectomy has the distinct advantage of limiting external scarring and having better cosmetic results. It moreover is associated with reduced post-operative pain, and enhanced postoperative recovery. **Methods:** It was a hospital based non randomized prospective descriptive study carried out in department of general surgery at tertiary hospital in which 39 patients with benign thyroid lesions were included on the basis of a predefined inclusion and exclusion criteria. Detailed history, clinical and local examination was done in all the cases. Thyroid function tests, FNAC under ultrasound guidance, indirect laryngoscopy and imaging of thyroid gland was done in all the cases. All patients underwent endoscopic thyroid surgery (Total, near total, subtotal or hemithyroidectomy). Patients were followed up for 6 months after surgery. P value less than 0.05 was taken as statistically significant. **Results:** Out of 39 studied cases there were 35 males and 4 females with a M:F ratio of 1:8.75. Most common age group was found to be 30-40 years with a mean age of 32 yrs. Average size of thyroid nodule was 3.20 cms and right lobe was predominantly involved (69.23%). Predominant Pathology on FNAC was found to be colloid goiter (71.79%). All patients underwent endoscopic thyroidectomy. Mean duration of surgery was 55 minutes. Most common surgery undertaken was hemithyroidectomy (84.62%) followed by total thyroidectomy (10.16%) and completion total thyroidectomy (5.13%). Average total blood loss was significantly less (36 ml). Mean visual analogue score at 24 and 48 hours post-operatively were 4.14 and 2.85. Mean duration of hospital stay was 3.3 days. Majority of the patients (89.75%) were extremely satisfied with the cosmetic results. **Conclusion:** Endoscopic thyroidectomy for Benign thyroid lesion is associated with less blood loss during surgery, comparatively less severe pain, decreased mean duration of hospital stay and satisfactory cosmetic results.

**Keywords:** Endoscopic thyroidectomy, Benign thyroid lesions, VAS scores, Outcome.

## INTRODUCTION

Thyroidectomy is one of the most common operations performed throughout the world, with solitary thyroid nodules being one of the more common indications for surgery.<sup>[1]</sup> Conventional open thyroidectomy is considered extremely safe and remains the treatment of choice. However, this procedure often leaves an undesirable scar on the anterior neck and seriously affect the aesthetic appearance of the neck.<sup>[2]</sup> Excitingly, the development of minimally invasive surgical techniques has served to overcome this limitation.<sup>[3]</sup> It has become an ideal goal for a surgeon to pursue to minimize surgical injuries and improve cosmetic outcomes. In 1998, Esposito reported the first case of

single-incision laparoscopic cholecystectomy.<sup>[4]</sup> Thereafter, minimally invasive surgical procedures have been gradually extended to cholecystectomy and weight loss surgery.<sup>[5,6]</sup> Similarly, minimally invasive endoscopic thyroidectomy has also become increasingly popular recently. Since Huscher et al first introduced endoscopic thyroidectomy in 1997, surgeons around the world have designed a variety of endoscopic thyroid surgical procedures, including areola, axillary, breast, anterior chest, or breast-axillary hybrid approaches.<sup>[7,8]</sup> It has been demonstrated that endoscopic thyroidectomy exhibits excellent therapeutic effects and improved cosmetic outcomes, compared with conventional open thyroidectomy. After nearly a hundred years of performing a thyroidectomy essentially the way it was described by Theodore Kocher in the 19th century, the past decade has seen dramatic changes in modern surgical technique. Much of this change has been technologically driven, with the introduction of high-resolution endoscopy, advanced energy devices and the evolution in addition to a faster and probably safer thyroidectomy, the possibility of accomplishing this

### Name & Address of Corresponding Author

Dr Ram Khare  
Resident,  
Department Of General Surgery,  
Government Medical College  
Nagpur.

procedure through a smaller incision has been widely recognized and increasingly embraced. The evolutionary development of laparoscopic surgery satisfies the aesthetic demand, recovery, and limited trauma in nearly all fields of surgical disciplines, including the treatment of differentiated thyroid cancer.<sup>[9-11]</sup>

Gagner,<sup>[12]</sup> reported the first endoscopic neck surgery in 1996 and video-assisted thyroid lobectomy was done by H'uscher et al.<sup>[13]</sup> Soon, endoscopic thyroidectomy (ET) was developed into scarless operation by Ikeda et al.<sup>[14]</sup> and Ohgami et al,<sup>[15]</sup> by using alternative techniques. Miccoli et al,<sup>[16]</sup> did invasive video-assisted thyroidectomy for papillary carcinoma successfully in 2001. Various methods of scarless endoscopic thyroidectomy (SET) procedure were successfully done in Asian countries like Korea and Japan.<sup>[17]</sup>

With this background we conducted this study of endoscopic thyroidectomy at our set up by axillary breast approach for benign condition of thyroid nodule for its safety and feasibility. The purpose of our study was to study indications and approach used for endoscopic thyroidectomy. Intraoperative and postoperative complications as well as safety and feasibility of endoscopic thyroidectomy.

## MATERIALS AND METHODS

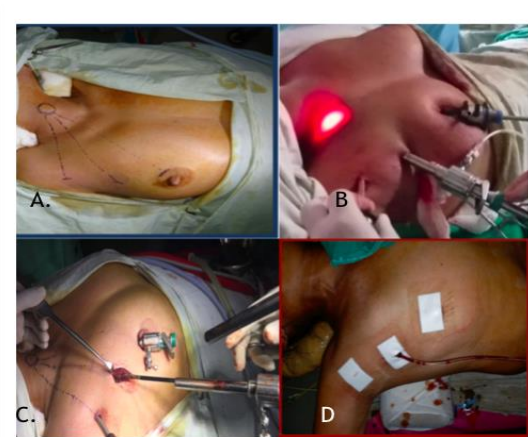
This was a hospital based non randomized prospective descriptive study carried out in department of general surgery at tertiary hospital over a period of 2 years. Patients diagnosed to be having benign thyroid lesions were included in this study on the basis of a predefined inclusion and exclusion criteria. Institutional ethical committee approved the study and written informed consent was obtained from all the patients. A detailed history was taken in all the cases including details of swelling like onset, duration and rate of growth, whether patient had any obstructive symptoms due to swelling. Symptoms and signs of thyrotoxicosis and hypothyroidism were also looked for in detail. Local examination of gland and a detailed systemic examination was done in all the cases. Gland was inspected from front. In short necked individual Pizzillo's method was used. Palpation of each lobe was carried out by Lahey's method. Percussion was done on manubrium sterni to exclude retrosternal extension. Auscultation was done to rule out systolic bruit.

Besides routine investigations all patients underwent investigations such as thyroid function test (T3, T4 and TSH in all cases FT3 and FT4 in all the cases). In hyperthyroid patient Carbimazole in appropriate doses was given. Thyroid function test was repeated 6 weekly. Once patient is Euthyroid patient is posted for surgery. In hypothyroid patient Thyroxine supplementation was given in L-thyroxine form till patient became Euthyroid. In our setup all FNAC were done under USG guidance. X-ray neck and chest

X-Ray as well as indirect laryngoscopy was done in all the cases. Ultrasound examination was done and the details such as number, size, echogenicity, presence of calcification and vascularity of the thyroid nodules were noted. Presence of any lymph nodes were also noted during ultrasound. Cross sectional imaging such as CT- Neck was done in few cases of enlarged nodular thyroid gland, thyroid mass and to assess extra glandular extension and metastatic lymph nodes in neck, upper mediastinum and to know retrosternal extension. Preanesthetic evaluation including ECG was done in all the cases.

Operative procedure:

All patients were operated under general anesthesia. Patients were given supine position with Neck moderately extended with sandbag under shoulder of operating side. The position of camera port (10mm), right hand working port (5mm) and left-hand working port (5mm) was anterior axillary fold midway of lateral border of pectoralis major, 12 o'clock circum areolar and anterior axillary fold deltopectoral groove respectively. Initial blunt dissection was done in subcutaneous plane up to supraclavicular region. Working space created with CO2 insufflation using 6 to 8 mm of Hg. Thyroid dissection was done in subplatysmal plane by ultrasonic harmonic scalpel. Specimen was extracted from 10 mm port by slightly increasing skin incision for large swelling. Drain was kept from 10 mm site and specimen was sent for histopathology Hemostasis was achieved by bipolar diathermy. Hemithyroidectomy, Subtotal thyroidectomy, Near Total thyroidectomy and Total thyroidectomy was done depending upon the pathology encountered.



**Figure 1: Steps of endoscopic thyroid surgery. (Clockwise from left upper corner) Port Position (A), Dissection(B), Specimen Extraction (C) and post-operative suture and drain placement (D).**

All patients post operatively were shifted to surgery ward and no patient post operatively needed ventilator. All patients received adequate analgesia for post-operative pain and antibiotics and majority of the patients were discharged within 3-5 day of postoperative period. Patients were followed up at

1mth, 3mth, 6mth for those who have complication with indirect laryngoscopy and thyroid function test and serum calcium level. The statistical analysis was done using SSPE 21.0 software. P value less than 0.05 was taken as statistically significant.

**Inclusion criteria:**

- Patients having benign thyroid lesions and having normothyroid status.
- Age above 18 years.
- Ready to give informed written consent.
- Thyroid size up to 5 cm in size
- Adequate follow up.

**Exclusion criteria**

- Age less than 18 years.
- Gland size > 5cm
- Malignant lesion
- History of Previous neck surgery or Cervical irradiation
- Thyroiditis
- Bleeding diathesis.
- Patients unfit for general anesthesia and not giving consent for endoscopic thyroidectomy.
- Patients lost to follow up

**RESULTS**

This was a hospital based prospective observational study done in department of general surgery in tertiary care center ,39 patients with s benign thyroid nodule were included on the basis of a predefined inclusion and exclusion criteria. Out of 39 studied cases there were 35 (89.74%) females and 4 (10.26%) males with a M:F ratio of 1:8.75.

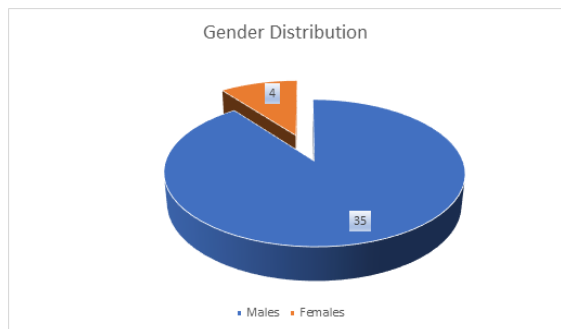


Figure 2: Gender Distribution of the studied cases.

The analysis of the age groups of the patients showed that the most common affected age group was 30-40 years (56.41%) followed by 40-50 years (20.51%) and 18-30 years (23.09%).

**Table 1: Age distribution of the affected cases.**

Age	No Of Cases	Percentage
18 to 30 yrs	09	23.08%
30 to 40 yrs	22	56.41%
40 to 50 yrs	08	20.51%
Total	39	100%

The distribution of the cases on the basis of lobe involved showed that out of 39 patients' right lobe was involved in 27 cases (69.23%) whereas left lobe

was involved in 12 cases (30.77%). There was no patient with involvement of isthmus or bilateral involvement.

In our study total 39 cases were operated out of which 27 cases were operated on right side and 12 cases were operated on left lobe.

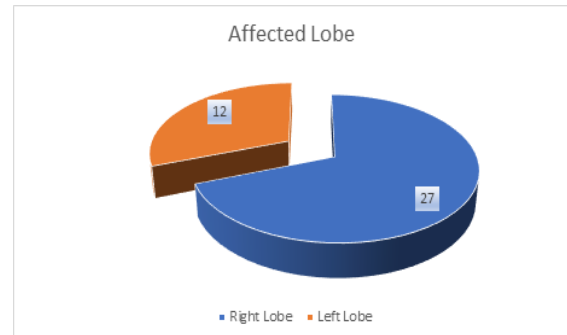


Figure 3: Affected Lobe in studied cases.

The analysis of the removed nodules showed that the size of thyroid nodules in studied cases ranged from 2-5 cms with a mean thyroid size of 3.2 cms. The mean size of thyroid nodule in male and female patients was found to be 3 and 3.4 cms respectively.

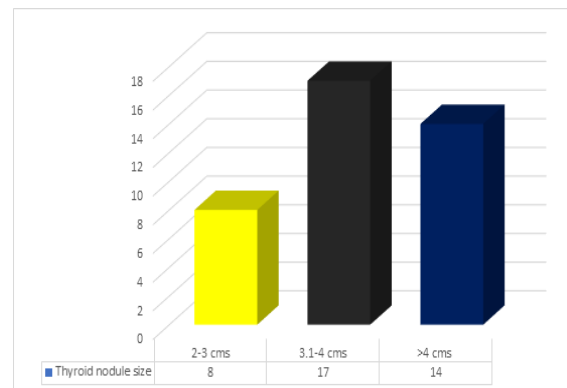


Figure 4: Thyroid Nodule size in studied cases.

There was no statistically significant difference in thyroid nodule size in male and female patients (P = 0.829 (Not Significant) 95% CI= -1.6635 to 2.0635)

**Table 2: Gender-Wise comparison of thyroid nodule size**

Thyroid Nodule Size	Mean	Standard Deviation
Males	3.0 cms	1.72
Females	3.4 cms	1.98

P = 0.829 (Not Significant) 95% CI= -1.6635 to 2.0635

The analysis of fine needle aspiration cytology in studied cases showed that out of 39 studied cases 28 cases (71.79%) had colloid goiter, 8 cases (20.51%) were found to have adenoma, 3 cases (7.69%) were having hurtle cell lesions. Malignant lesions being an exclusion criterion were not seen in any cases.

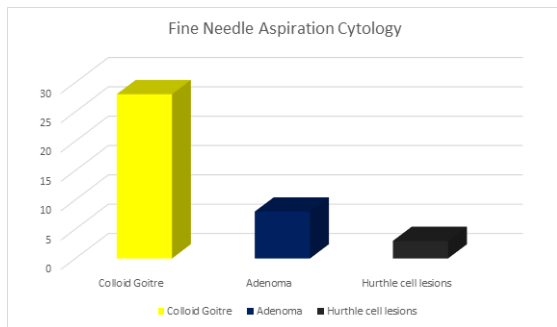


Figure 5: Fine Needle Aspiration Cytology of the studied cases.

The average duration of surgery was found to be 68 min. Out of 39 studied cases in initial 5 cases the mean duration of surgery was 105 min, in next 10 cases mean duration of surgery was 81 min and in next 24 cases mean duration of surgery was 55 min. Maximum surgery time was 110 minute and minimum time was 40 minute. We observed that in initial cases duration of surgery was longer and in subsequent surgeries the duration of surgery was comparatively shorter. So endoscopic thyroidectomy has learning curve. Surgeons experience is important for endoscopic thyroidectomy.

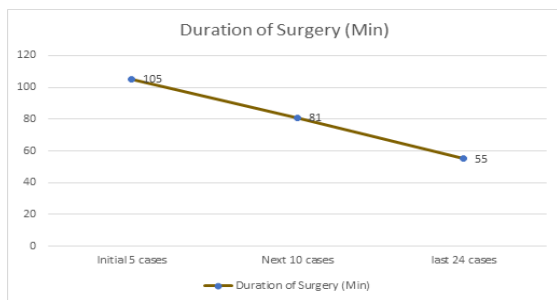


Figure 6: Duration Of Surgery In Studied Cases.

In our study we used axillary breast approach. Hemithyroidectomy was the most common surgery and was done in 33 cases (84.62%). Total thyroidectomy and completion thyroidectomy were done in 4 (10.16%) and 2 (5.13%) cases respectively.

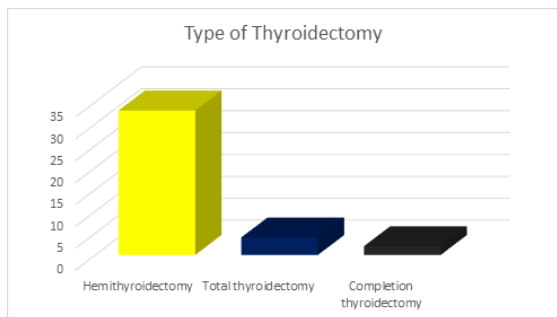


Figure 7: Type of thyroidectomy in studied cases.

We observed that in 36 (92.31%) cases recurrent laryngeal nerve visualized during operation. In all 39 (100%) cases parathyroid gland visualized. It is due

to magnified vision by endoscope. This reduces accidental injury nerve and blood vessel.

Table 3: Intraoperative Component in studied cases.

Intraoperative Component	Number Of Cases	Percentage
Recurrent Laryngeal Nerve	36	92.30%
Parathyroid gland	39	100%

Average intraoperative blood loss was found to be 23 ml. Intraoperative maximum blood loss was 35 ml and minimum blood loss was 16 ml. Mean post-operative blood loss was 13 ml. Maximum blood loss was 20 ml and minimum blood loss was 10 ml during post-operative period. Average total blood loss was 36 ml. None of the patients required re-exploration due to bleeding.

Table 4: Blood loss in operated cases.

Mean Blood Loss	Quantity
Intra operative	23ml
Post-operative	13ml
Total	36ml

We found that all patients had moderate post-operative pain. We used visual analogue scale for assessment of pain. post-operative pain was managed by adequate analgesics. We observed pain at post-operative 6 hour, 24 hours and 48 hours. Maximum mean VAS scores were seen at post-operative 6 hours. Mean Visual analogue score at 6, 24 and 48 hours was found to be 4.73, 4.14 and 2.85 respectively. intensity of pain decreased gradually with time.

Table 5: Visual Analogue Scale in post-operative period.

Post-Operative Duration	Visual Analogue Scale (Average)
6 hours	4.73
24 hours	4.14
48 hours	2.85

Mean hospital stay for our surgery was 3.3 days. Maximum hospital stay was 7 days. Minimum hospital stay was 2 days. Out of 39 patients 26 (66.6%) patients were discharged within 3 days whereas 13 (33.3%) had to remain in hospital for more than 3 days.

Table 6: Duration of hospital stay in studied cases.

Discharge	Number Of Patients	Percentage
Within 3 days	26	66.6%
After 3 days	13	33.3%

Since we used deltopectoral, axillary line, areola for insertion of ports the scar formed was usually covered by clothing thereby the results were cosmetically acceptable for most of the patients. 35 (89.75%) patients were extremely happy with scar. And 4 (10.25%) patients were satisfied. There was no patient

who expressed dissatisfaction with cosmetic results during follow up.

**Table 7: Cosmetic results in operated cases.**

Cosmetic Effect	Number Of Patients	Percentage
Extremely satisfied	35	89.75%
satisfied	4	10.25%
dissatisfied	0	0%

## DISCUSSION

The present study was hospital based prospective observational study done in department of general surgery in a tertiary care government medical college and hospital in which patients with benign thyroid nodule were selected from general surgery OPD. Out of 39 studied cases there were 35 (89.74%) males and 4 (10.26%) females with a M:F ratio of 1:8.75. This is supported by Liu and Zhou et al who in a study of patients with benign thyroid swelling found female to male ratio was 9.5 to 1.<sup>[18]</sup> In another study Nirav et al studied 35 cases of benign thyroid nodule and found female to male ratio of 7.7.<sup>[19]</sup>

In present study maximum number of cases (56.41%) were between 31 to 40 years followed by patients between 18 to 30 years (23.08%) and between 40 to 50 yrs (20.51%). These findings were supported by Naz Akhtar et al who found that majority of the patients (42.7%) were between 31-40 years age group.<sup>[20]</sup>

In our study mean size nodule removed by axilla breast approach was 3.2 cm. In studies of endoscopic thyroidectomies conducted by Ikeda et al,<sup>[21]</sup> and Puntambekar et al the mean size of thyroid nodule was found to be 4.2 cms and 4.8 cms respectively.<sup>[22]</sup> The sized of thyroid nodule was determined by high frequency ultrasound of the neck.

In our study out of 39 cases 28 cases was found to be having colloid goitre, 8 cases were having adenoma and 3 cases were hurthle cell lesions. Gyanchand et al conducted a study of benign thyroid lesions and found that out of 41 patients 33 patients were having colloid goiter, 5 patients were having adenoma and 3 patients were hurthle cell lesion.<sup>[23]</sup> Similar results were reported by Yoo C et al.<sup>[24]</sup>

In our study we did thyroidectomy by remote access axillary breast approach. The first endoscopic thyroid surgery for 5 to 7 cm adenoma was performed by Ohgami et al using three port technique, two in circum-areolar and one in parasternal position, in this technique there was a scar in anterior chest wall and then Ikeda et al.<sup>[25]</sup> Applied chest and axillary approach for thyroid adenoma, Grave's disease, and papillary micro carcinoma. Shimazu et al modified this approach to axillary- bilateral breast approach for endoscopic thyroidectomy.<sup>[26]</sup> Present study composed of endoscopic thyroid surgery for clinically euthyroid benign goiters, out of 39 patients, majority had solitary thyroid nodule. The basic principle of thyroid surgery was same during this technique of

endoscopic surgery, such as capsular dissection, identification and preservation of parathyroid gland and recurrent laryngeal nerves so the operation can be performed safely.

In our study mean duration of surgery was found to be 68 min. First 5 cases required a mean operating time of 105 min. In next 10 cases mean time of surgery was 81 min and in last 24 cases mean duration of surgery was 54 min. Endoscopic thyroidectomy was found to have learning curve. In a similar study by Gyan Chand et al the mean duration of surgery was found to be 136 minutes. In present study blood loss intra operative was 23 ml. And post-operative was 13 ml. Our study was found to be comparable to El Labban et al who reported the mean blood loss to be approximately 39 ml.<sup>[27]</sup>

In our study we found that due dissection and use of CO2 6 patients developed subcutaneous emphysema and erythema surrounding operative field. 2 patients developed erythema up to neck due to dissection by energy sources and 2 patients has subcutaneous emphysema up to neck. These complications resolved spontaneous without any intervention. In our study we found that patients have post-operative pain up to 2 days and pain according visual analogue score was moderate and pain intensity gradually decreased. VAS scores in postoperative period in our study was found to be comparable to the study conducted by Miccoli et al.<sup>[16]</sup>

Mean hospital stay in our patients was 3.3 days. Maximum hospital stay was 7 days. Minimum hospital stay was 2 days. Out of 39 patients 26 (66.6%) patients were discharged within 3 days whereas 13 (33.3%) had to remain in hospital for more than 3 days. Mean hospital stay in our study was comparable to the study conducted by Melhelm T et al, Nakajo A and Berber E et al.<sup>[8,29,30]</sup> In this study we found that 35 patients were extremely satisfied with cosmetic results whereas 4 patients were satisfied. So it can be concluded that endoscopic thyroidectomy has excellent cosmetic results.

## CONCLUSION

Endoscopic thyroidectomy for Benign thyroid lesion is associated with less blood loss during surgery, comparatively less severe pain, decreased mean duration of hospital stay and satisfactory cosmetic results and hence considered to be operative procedure of choice particularly in thyroid nodules up to 5 cms size.

## REFERENCES

1. Inabnet WB 1999 Follicular and Hürthle cell neoplasms. In: Staren ED, Prinz RA (eds) The Manual of Endocrine Surgery, 1999
2. Wang C, Feng Z, Li J, Yang W, Zhai H, Choi N, et al. Endoscopic thyroidectomy via areola approach: Summary of 1,250 cases in a single institution. SurgEndosc 2015;29: 192-201.

3. Yan H, Wang Y, Wang P, Xie Q, Zhao Q. "Scarless" (in the neck) endoscopic thyroidectomy (SET) with ipsilateral levels II, III, and IV dissection via breast approach for papillary thyroid carcinoma: A preliminary report. *SurgEndosc* 2015; 29:2158–2163.
4. Esposito C. One-trocar appendectomy in pediatric surgery. *SurgEndosc* 1998;12:177–178.
5. Ng WT, Tse S. One-trocar appendectomy. *SurgEndosc* 2003;17:1162– 1163; author reply 1164.
6. Lim RB, Blackburn GL, Jones DB. Benchmarking best practices in weight loss surgery. *CurrProblSurg* 2010;47: 79–174.
7. Huscher CS, Chiodini S, Napolitano C, Recher A. Endoscopic right thyroid lobectomy. *SurgEndosc* 1997;11:877.
8. Ikeda Y, Takami H, Sasaki Y, Kan S, Niimi M. Endoscopic resection of thyroid tumors by the axillary approach. *J CardiovascSurg (Torino)* 2000;41:791–792.
9. Schardey HM, Barone M, Portl S, von Ahnen M, von Ahnen T, Schopf S. Invisible scar endoscopic dorsal approach thyroidectomy: A clinical feasibility study. *World J Surg* 2010;34:2997–3006.
10. Ohgami M, Ishii S, Arisawa Y, Ohmori T, Noga K, Furukawa T, et al. Scarless endoscopic thyroidectomy: Breast approach for better cosmesis. *SurgLaparoscEndosc Percutan Tech* 2000;10:1–4.
11. Shan YZ, Zhou LM, Yu ZF, Wang SG, Gao GL, Shen Y, et al. Comparison between transareolar single-site endoscopic thyroidectomy and minimally invasive video-assisted thyroidectomy. *J Int Med Res* 2012;40:2213–2219.
12. M. Gagner, "Endoscopic subtotal parathyroidectomy in patients with primary hyperparathyroidism," *The British Journal of Surgery*, vol. 83, no. 6, p. 875, 1996.
13. C. S. Huscher, S. Chiodini, C. Napolitano, and A. Recher, "Endoscopic right thyroid lobectomy," *Surgical Endoscopy*, vol. 11, no. 8, p. 877, 1997.
14. Y. Ikeda, H. Takami, Y. Sasaki, S. Kan, and M. Niimi, "Endoscopic neck surgery by the axillary approach," *Journal of the American College of Surgeons*, vol. 191, no. 3, pp. 336–340, 2000.
15. M. Ohgami, S. Ishii, Y. Arisawa et al., "Scarless endoscopic thyroidectomy: breast approach for better cosmesis," *Surgical Laparoscopy and Endoscopy*, vol. 10, no. 1, pp. 1–4, 2000.
16. P. Miccoli, P. Berti, M. Raffaelli, M. Conte, G. Materazzi, and D. Galleri, "Minimally invasive video-assisted thyroidectomy," *American Journal of Surgery*, vol. 181, no. 6, pp. 567–570, 2001.
17. Bae JS, Cho YU, Sung GY, Oh SJ, Jung EJ, Lee JB, et al. The current status of endoscopic thyroidectomy in Korea. *Surg Laparosc Endosc Percutan Tech*. 2008 Jun;18(3):231-5.
18. Liu W, Zhou M. A Comparative Study on the Transareola Single-Site Versus Three-Port Endoscopic Thyroidectomy. *J Laparoendosc Adv Surg Tech A*. 2017 Mar;27(3):242-246.
19. Nirav Priyadarshini, Dhaval Mistry NK. Study of Management of Solitary Thyroid Nodule. *IJSR*. 2(3):181–4.
20. Naz Akhtar, Majeedullahbuzdar MA. Frequency of Malignancy in Solitary thyroid Nodule. *PJMHS*. 2015;9:983.
21. Ikeda Y, Takami H, Sasaki Y, Takayama J, Kurihara H (2004) Are there significant benefits of minimally invasive endoscopic thyroidectomy? *World J Surg* 28:1075–1078 .
22. Puntambekar SP, Palep RJ, Patil AM, et al. Endoscopic thyroidectomy: Our technique. *J Minim Access Surg*. 2007;3(3):91–97.
23. Gyan Chand, SK Mishra, Ashok Kumar and Suman Vimal Endoscopic Thyroidectomy: Experience of Breast and Axillary Approach *Journal of Universal Surgery* Vol. 5 No. 3: 18.
24. Yoo C, Choi HJ, Im S, et al. Fine needle aspiration cytology of thyroid follicular neoplasm: cytohistologic correlation and accuracy. *Korean J Pathol*. 2013;47(1):61–66.
25. Ohgami M, Ishii S, Arisawa Y, Ohmori T, Noga K, Furukawa T, et al. Scarless endoscopic thyroidectomy: Breast approach for better cosmesis. *SurgLaparoscEndosc Percutan Tech* 2000;10:1–4.
26. Shimazu K, Shiba E, Tamaki Y, Takiguchi S, Taniguchi E, et al. (2003) Endoscopic thyroid surgery through the axillo-bilateral breast approach. *Surg Laparosc Endosc Percutan Tech* 13:196-201.
27. El-Labban GM. Minimally invasive video-assisted thyroidectomy versus conventional thyroidectomy: A single-blinded, randomized controlled clinical trial. *J Minim Access Surg*. 2009;5(4):97–102.
28. Wilhelm T, Metzger A. Endoscopic minimally invasive thyroidectomy (eMIT): a prospective proof-of-concept study in humans. *World J Surg* 2011;35:543–551.
29. Nakajo A, Arima H, Hirata M, et al. Trans-oral video-assisted neck surgery (TOVANS). A new transoral technique of endoscopic thyroidectomy with gasless premandible approach. *SurgEndosc* 2013;27:1105–1110.
30. Berber E, Bernet V, Fahey TJ 3rd, et al. American Thyroid Association statement on remote-access thyroid surgery. *Thyroid* 2016;26:331–337.

**How to cite this article:** Pal S, Khare R, Gajbhiye R. Endoscopic Thyroidectomy for Benign Thyroid Lesions: A Prospective Study. *Ann. Int. Med. Den. Res.* 2019; 5(3):SG39-SG44.

**Source of Support:** Nil, **Conflict of Interest:** None declared