

Comparison of Acute Toxicities and Locoregional Control of Intracavitary Brachytherapy With or Without Concurrent Weekly Cisplatin in Patients of Locally Advanced Cervical Carcinoma Following Concurrent Chemoradiation.

Swapan Kumar Mallick¹, Bidisha Ghosh Naskar², Amit Saklani³, Harris Mahammad Sepai⁴, Kaustav Chatterjee³, Ghafran Nahid⁴

¹Associate Professor, Department of Radiotherapy, Malda Medical College and Hospital, Malda, West Bengal.

²Associate Professor, Department of Radiotherapy, IPGMER and SSKM Hospital, Kolkata, West Bengal.

³Senior Resident, Department of Radiotherapy, IPGMER and SSKM Hospital, Kolkata, West Bengal.

⁴RMO Cum Clinical Tutor, Department of Radiotherapy, Malda Medical College & Hospital, Malda West Bengal.

Received: June 2019

Accepted: June 2019

Copyright: © the author(s), publisher. It is an open-access article distributed under the terms of the Creative Commons Attribution Non-Commercial License, which permits unrestricted non-commercial use, distribution, and reproduction in any medium, provided the original work is properly cited.

ABSTRACT

Background: Cervical cancer is one of the leading causes of cancer-related deaths in developing countries. Between 80% and 90% of cervical carcinomas are squamous cell carcinomas. Concurrent chemo radiation with Inj. Cisplatin given every week followed by intracavitary Brachytherapy has become the standard of treatment in locally advanced cervical carcinoma. **Methods:** 60 biopsy proven cases of locally advanced cervical cancer attending the Out Patient Department of Radiotherapy from November 2017 to April 2019, meeting specified Inclusion and Exclusion Criteria, willing to participate in the study were included. Acute toxicities and locoregional control were assessed using the common terminology criteria for adverse events (CTCAE) version 4.0. During treatment patients will be reviewed weekly. After treatment completion, patients will be reviewed monthly for six months. And after that, they will be reviewed every 3 months for 9 months. **Results:** The median age was 50 years (range: 40–60 years) in both the arms. On analysing the pattern of response, in Arm A the number of patients having complete response was 29 (96.66%), partial response was 1 (3.34%). In the Arm B all patients have complete response. The incidence of Emesis, Dermatitis, Neutropenia, and Vaginal Mucocytis were more in Arm B as compared to Arm A. **Conclusion:** In locally advanced squamous cell carcinoma of uterine cervix, addition of concurrent injection Cisplatin to ICRT did not significantly improve loco regional response but increases incidence of haematological and mucosal toxicity, which being manageable, were not associated with increased mortality.

Keywords: Cervical cancer, Concurrent chemoradiation, Cisplatin, external-beam radiotherapy, high dose rate intracavitary brachytherapy.

INTRODUCTION

Carcinoma of the Uterine Cervix is one of the leading causes of cancer-related deaths in developing countries.^[1] Between 80% and 90% of cervical carcinomas are squamous cell carcinomas.^[2] More than 90% cases cervical cancer are related to HPV.^[2,3] The early stages of cervical cancer may be completely asymptomatic.^[6,7] Symptoms of advanced disease may include loss of appetite, weight-loss, fatigue, pelvic pain, back pain, leg pain, single swollen leg, heavy bleeding from vagina,

leaking of urine or faeces from the vagina.^[8] Punushapai et al.^[17] found in their study that concurrent chemoradiotherapy with weekly cisplatin 40 mg/m² in locally advanced cervical cancer gives good outcomes.

Concurrent chemo radiation with radio-sensitizer like Inj. Cisplatin given every week followed by Intracavitary Brachytherapy(ICRT) has become the standard of treatment in locally advanced cervical carcinoma. To achieve good local response, the radiation dose can be escalated. But the addition of concurrent Cisplatin to brachytherapy following concurrent chemoradiation has not been much evaluated. This study is based on comparing the treatment with concurrent chemoradiation followed by ICRT with or without concurrent Cisplatin, by randomising the patients attending SSKM Radiotherapy OPD within study period and fulfilling

Name & Address of Corresponding Author

Dr. Bidisha Ghosh Naskar
111 Roy Mallick colony,
Debalay 2nd floor, Kundu Bagan,
P.O. – Ghughudanga,
Kolkata – 700030.

the selection criteria into 2 arms; 1 receiving concurrent Cisplatin with ICRT and other without concurrent Cisplatin during ICRT.

Cervical carcinoma in early stages is quite radiosensitive, however, in locally advanced stages, the long-term outlook has consistently remained grim on account of central or peripheral failures. According to recent published literature approximately half of locally advanced disease fails in treated pelvic area.^[9,10] Standard treatment regimen for such cases has remained external beam radiation with concurrent chemotherapy followed by brachytherapy wherever possible.^[11] Cure is interlinked with radiation dose escalation however; such ingredients to improve local control by increasing radiation dose are hampered by the limited tolerance of surrounding critical organs. Attempts have been made to improve the local control and survival in the advanced stages of the disease by combination of radio-sensitizer like Cisplatin with external beam radiation.

This study aims to evaluate the acute toxicities and local control of concurrent chemotherapy with brachytherapy, for locally advanced cervical carcinoma (LACC). Several authors have claimed overall improvement of disease-free survival as compared to treatment with radiation alone.^[12-16] Strauss et al. treated 27 patients with stage IIB-IIIB cervical cancers with concurrent Cisplatin and brachytherapy in Germany.^[18] Complete response rate was 92.3%, and 80% of the patients were disease free in 20 months follow-up. Acute effects including grade III hematological toxicities and late effects were seen in 29.6% and 7.4% of cases, respectively. The study aims to quantify objectively the potential to improve the loco regional control and acute toxicities.

MATERIAL AND METHODS

Patients with locally advanced cervical cancer attending the Radiotherapy Out Patient Department (OPD), SSKM and Institute of Postgraduate Medical Education and Research, Kolkata. from November 2017 to April 2019 , meeting specified Inclusion and Exclusion Criteria, willing to participate in the study were randomized into two groups or arms. Patients in (ARM A) were treated with EBRT, 50 Gy in 25 fractions over 5 weeks, with concurrent chemotherapy (Injection cisplatin 50mg weekly on the day of EBRT) followed by HDR brachytherapy(7 Gy/3 fraction) .Patient in ARM B were treated with EBRT,50 Gy in 25 fractions over 5 weeks, with concurrent chemotherapy (Injection cisplatin 50mg weekly on the day of EBRT) followed by HDR brachytherapy(7 Gy/3 fraction) with concurrent injection cisplatin 50 mg. Response was assessed using the Response Assessment Criteria in solid tumours. Resist (RECIST) version 1.1. Acute and late toxicities were assessed using the

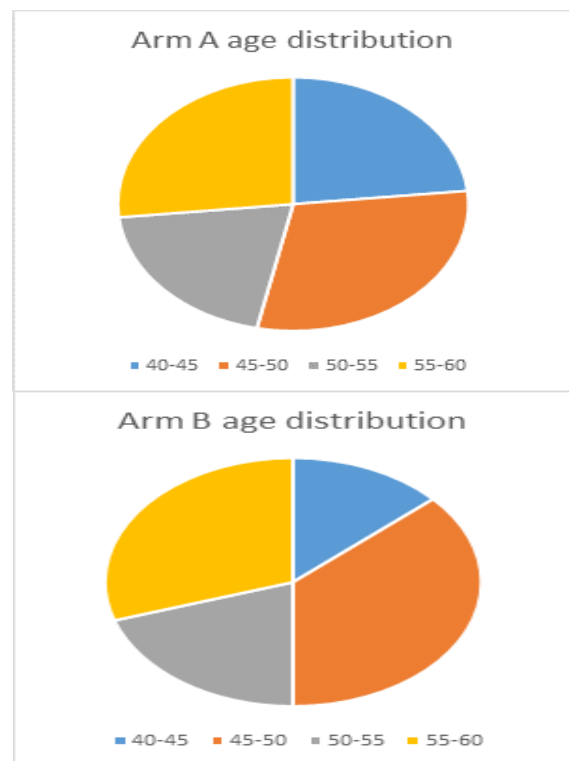
common terminology criteria for adverse events (CTCAE) version 4.0. During treatment patients will be reviewed weekly. After treatment completion, patients will be reviewed monthly for six months. And after that, they will be reviewed every 3 months for 9 months.

RESULTS

Comparison between distributions of age of patients between two arms

Table 1: ?.

Age Group	Arm A	Arm B	P value
40-45 yrs	7	4	0.277 (not significant)
45-50 yrs	9	11	
50-55 yrs	6	6	
55-60 yrs	8	9	



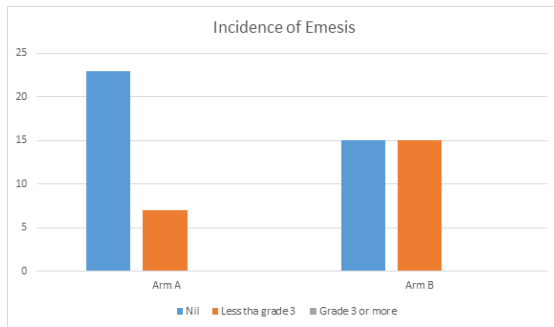
This single institution study was conducted from November 2017 to April 2019. Total 85 patients were assessed for eligibility. Ultimately, 60 patients were included in the study and randomised into Arm A and Arm B. Study algorithm is summarised in CONSORT 2010 flow chart.

Patient tolerated the treatment well with few side effects like nausea, vomiting during the treatment in the study arm specially during the ICRT.

The age distribution was compared between two arms. Then toxicities, namely, neutropenia, thrombocytopenia, anemia, mucositis, dermatitis, cystitis, proctitis, nephropathy were compared between two arms. Finally, we compared outcome in the form of complete response, Partial response, Stable disease and Progressive disease between two arms.

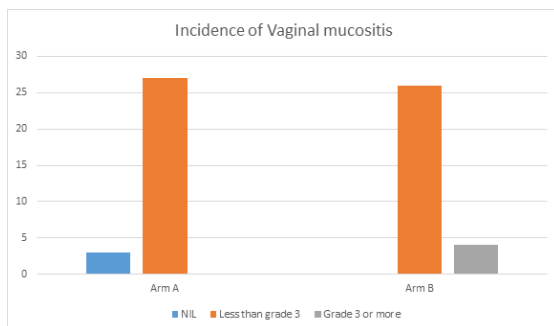
Incidence of highest grade of Emesis at any point of treatment

Grade	Arm A	Arm B	P value
NIL	23	15	0.740(not significant)
Less than Grade 3	7	15	
Grade 3 or more	0	0	



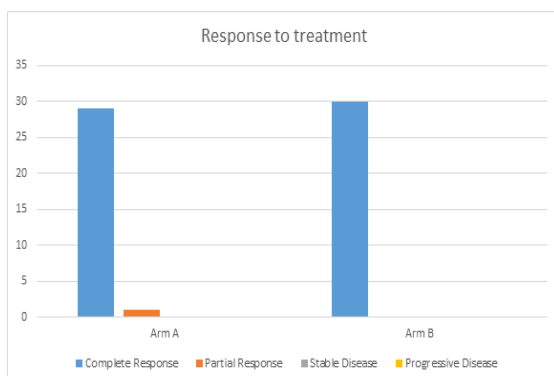
Incidence of highest grade of Vaginal Mucositis at any point of time during treatment

Grade	Arm A	Arm B	P value
NIL	3	0	0.576 (not significant)
Less than Grade 3	27	26	
Grade 3 or more	0	4	



Response to treatment

Type of response	Arm A	Arm B	P value
Complete response	29	30	0.999(not significant)
Partial Response	1	0	
Stable disease	0	0	
Progressive disease	0	0	



DISCUSSION

Squamous cell carcinoma of uterine cervix is one of the commonest gynaecological malignancy in females of India. In our present study we tried to compare the toxicity and locoregional control between two arms with one comprising of concurrent EBRT followed by ICRT, and the other concurrent EBRT followed by concurrent ICRT with injection Cisplatin.

The study included locally advanced CA cervix. As age distribution is concerned there was no significant difference (p value).

On comparing individual toxicity, it was seen that incidence of Grade 3 or more neutropenia although was higher in Arm B is not statistically significant. Similar is the result for Anaemia, thrombocytopenia and vaginal mucositis. There was statistically significant difference in the renal dysfunction in both arms during treatment which was temporary and subsided during follow up. There were also no grade 3 nephropathy in the Arm B. All nephropathies occurred in both groups were grade 1 and 2. On comparing incidence of emesis, there were no grade 3 or more incidences of emesis in both the arms although the incidence of Emesis (Grade 1 or 2) is more in the Arm B. During the follow up for six months there were no cases of proctitis or cystitis found in any arm.

The incidence of Dermatitis was more in Arm B as compared to Arm A. Grade 3 or more neutropenia is not seen in any patients in both arms. There were fewer cases of neutropenia in Arm A while in Arm B there were more neutropenic cases though only one patient had grade 3 neutropenia (Afebrile).

On comparing vaginal mucositis Arm B had more incidence of vaginal mucositis as expected. In Arm A there was no incidence of grade 3 mucositis while in Arm B there were 4 incidences of vaginal mucositis due to which interruption of treatment occurred. Arm B patients had more RT interruptions than Arm A, probably due to more incidences of side effects specially vaginal mucositis. On analysing the pattern of response, it was noted that in Arm A the number of patients having complete response was 29 (96.66%), partial response was 1(3.34%), and in the Arm B all patients have complete response. During follow-up residual necrotic mass is seen in 5 patients in Arm A and 3 patients in Arm B which was histologically proven to be non-malignant.

CONCLUSION

In the present study it was observed that in locally advanced squamous cell carcinoma of uterine cervix, addition of concurrent injection Cisplatin to ICRT did not significantly improve locoregional response and was associated with increased incidence of haematological and mucosal toxicity(not statistically significant), which being manageable, were not associated with increased mortality.

REFERENCES

1. Perez and Brady's Principles and Practice of Radiation Oncology, 6th Ed: p. 1355.
2. DeVita, Hellman, and Rosenberg's Cancer Principles & Practice of Oncology, 9th Ed: p. 1315. DeVita, Hellman, and Rosenberg's Cancer Principles & Practice of Oncology, 9th Ed: p. 1319.
3. Bruni L, Barrionuevo-Rosas L, Albero G, Aldea M, Serrano B, Valencia S, Brotons M, Mena M, Cosano R, Muñoz J, Bosch FX, de Sanjosé S, Castellsagué X. ICO Information Centre on HPV and Cancer (HPV Information Centre). Human Papillomavirus and Related Diseases in India. Summary Report 2014-12-18.
4. Mohar A, Frias-Mendivil M. Epidemiology of cervical cancer. *Cancer Invest* 2000; 18:584-590.
5. Kumar, Vinay; Abbas, Abul K.; Fausto, Nelson; & Mitchell, Richard N. (2007). Robbins Basic Pathology ((8th ed.) ed.). Saunders Elsevier. p. 718–721. ISBN 978-1-4160-2973-1.
6. Canavan TP, Doshi NR (2000). "Cervical cancer". *AmFam Physician* 61 (5): 1369–76. PMID 10735343. <http://www.aafp.org/afp/20000301/1369.html>. Retrieved 2007-12-01.
7. Nanda, Rita (2006-06-09). "Cervical cancer". *MedlinePlus Medical Encyclopedia*. National Institutes of Health. <http://www.nlm.nih.gov/medlineplus/ency/article/000893.htm>. Retrieved 2007-12-02.
8. Vasishtha S, Varghese A, Ragheb A (2007) Patterns of failure in cervical carcinoma and outcome of salvage therapy: a retrospective study. *Gulf J Oncolog* 1: 43-49.
9. Perez CA, Breaux S, Madoc-Jones H, Bedwinek JM, Camel HM, et al. (1983) Radiation therapy alone in the treatment of carcinoma of uterine cervix. I. Analysis of tumor recurrence. *Cancer* 51: 1393-1402.
10. Perez CA (1998) Uterine cervix. In: Perez CA, Brady LW (eds) Principles and practice of radiation oncology. (3rd edn), Lippincott- Raven Publishers, Philadelphia.
11. Keys HM, Bundy BN, Stehman FB, Muderspach LI, Chafe WE, et al. (1999) Cisplatin, radiation, and adjuvant hysterectomy compared with radiation and adjuvant hysterectomy for bulky stage IB cervical carcinoma. *N Engl J Med* 340: 1154-1161.
12. Whitney CW, Sause W, Bundy BN, Malfetano JH, Hannigan EV, et al. (1999) Randomized comparison of fluorouracil plus cisplatin versus hydroxyurea as an adjunct to radiation therapy in stage IIB-IVA carcinoma of the cervix with negative para-aortic lymph nodes: a Gynecologic Oncology Group and Southwest Oncology Group study. *J Clin Oncol* 17: 1339-1348.
13. Morris M, Eifel PJ, Lu J, Grigsby PW, Levenback C, et al. (1999) Pelvic radiation with concurrent chemotherapy compared with pelvic and para-aortic radiation for high-risk cervical cancer. *N Engl J Med* 340: 1137-1143.
14. Peters WA, Liu PY, Barrett RJ, Stock RJ, Monk BJ, et al. (2000) Concurrent chemotherapy and pelvic radiation therapy compared with pelvic radiation therapy alone as adjuvant therapy after radical surgery in high-risk early-stage cancer of the cervix. *J Clin Oncol* 18: 1606-1613.
15. Rose PG, Bundy BN, Watkins EB, Thigpen JT, Deppe G, et al. (1999) Concurrent cisplatin-based radiotherapy and chemotherapy for locally advanced cervical cancer. *N Engl J Med* 340: 1144-1153.
16. Punushapai U, Yuenyao P, Chumworathayi B, Luanratanakorn S, Udomthavornsuk B (2010) Weekly cisplatin 20 mg/m2 in patients with carcinoma of cervix receiving pelvic radiotherapy at Srinagarind Hospital: a randomized controlled trial. *Asian Pac J Cancer Prev* 11: 201-207.
17. Strauss HG, Kuhnt T, Laban C, Puschmann D, Pigorsch S, et al. (2002) Chemoradiation in cervical cancer with cisplatin and high-dose rate brachytherapy combined with external beam radiotherapy. Results of a phase- II study. *Strahlenther Onkol* 178: 378-385.
18. Chandel SS, Jain RK (2016) Evaluation of Role of Concurrent Chemotherapy and Brachytherapy in Locally Advanced Cervical Cancer Patients. *J Cancer Sci Ther* 8: 010-014

How to cite this article: Mallick SK, Naskar BG, Saklani A, Sepai HM, Chatterjee K, Nahid G. Comparison of Acute Toxicities and Locoregional Control of Intracavitary Brachytherapy With or Without Concurrent Weekly Cisplatin in Patients of Locally Advanced Cervical Carcinoma Following Concurrent Chemoradiation. *Ann. Int. Med. Den. Res.* 2019; 5(4):RT01-RT04.

Source of Support: Nil, **Conflict of Interest:** None declared