

Renal Pathologies in Medicolegal Autopsies (150 Cases).

Mohini Garg¹, Harpal Singh Seemar², Ramesh Kundal³, Akashdeep Aggarwal⁴

¹Junior Resident Pathology GMC Patiala.

²Professor, Dept. of Pathology Govt. Medical College Patiala.

³Professor & Head, Department of Pathology Govt. Medical College, Patiala.

⁴Associate Professor, Department of Forensic Medicine and Toxicology, GMC Patiala.

Received: March 2019

Accepted: April 2019

Copyright: © the author(s), publisher. It is an open-access article distributed under the terms of the Creative Commons Attribution Non-Commercial License, which permits unrestricted non-commercial use, distribution, and reproduction in any medium, provided the original work is properly cited.

ABSTRACT

Background: The autopsy has for long been regarded as the gold standard as the most important tool for retrospective quality assessment of clinical diagnosis as well as a key education tool. In autopsy the kidneys are examined for disease, injury and other findings suggesting cause of death or related changes. Grossly some of the diseases may be easily noted on autopsy. Since kidney biopsy is usually avoided in critically ill patient, histologic evaluation of autopsy of kidneys may be the first and the only opportunity to identify these diseases. **Objectives:** 1) To study the pattern of histological findings in kidney in minimum 150 autopsy cases based on the material received in Pathology department, GMC, Patiala. 2) To study the latent form of the disease, which couldn't be diagnosed in lifetime, whenever full data is available. 3) To establish the exact cause of death on renal autopsy findings, wherever possible. 4) To find discrepancy with clinical diagnosis if the data are available. **Methods:** The present study is an observational study that was conducted over a period of two years. Postpartum renal specimens were received from August, 2016 onwards with a total of 150 cases. The specimens were preserved in 10% formalin immediately after autopsy and were received in fully sealed jars. A thorough gross examination of renal specimens including measurements, weights, consistency, cut surface, details of any lesions if preserved were recorded. Subsequently samples were processed for histopathology. The sections were thoroughly examined microscopically on 4x, 10x, and 40x power of the microscope for any pathology and the results were recorded. **Results:** In 57 cases (38%) microscopic findings were close to normal histology with no nephropathological diagnosis. 68 cases with tubular and interstitial pathology included 43 cases of acute tubular necrosis (28.6%), 3 cases with acute pyelonephritis (2%), 2 cases with chronic pyelonephritis (1.3%) and 20 cases were noted to have cloudy swelling in the tubule (13.3%). **Conclusion:** In the present study majority of renal autopsies revealed histopathological pattern suggestive of tubular pathologies of which most common was acute tubular necrosis as a cause of sudden collapse of patient leading to death.

Keywords: Renal autopsy, Biopsy, Gross & Microscopy, Histopathology.

INTRODUCTION

The autopsy has for long been regarded as the gold standard as the most important tool for retrospective quality assessment of clinical diagnosis as well as a key education tool. The benefits of autopsy include evaluating the accuracy of diagnosis and the outcome of therapy. Findings on autopsy can enable the pathologist to alert the infection control unit of a hospital on possible nosocomial infections especially contagious infections. The pathologist can also identify a hereditary condition that would require genetic counselling. Findings at autopsy also generate vital statistics needed for research as well as the provision of materials for the teaching of

anatomy, histology, and pathology. Medico-legal investigation of death focuses on the establishment of the cause of death, the time and the circumstances of death.^[1] Furthermore, our understanding of the natural history and pathogenesis of kidney disease will improve with accurate recognition and reporting of kidney diseases at autopsy.

MATERIALS AND METHODS

The study was an observational study that was conducted over a period of two years in the department of Pathology, Govt. Medical College, Patiala. The material for the study were postpartum renal specimens received from August, 2016 onwards with a total of 150 cases. These specimens were usually from medicolegal cases including custodial deaths, road traffic accidents, poisoning, cardiovascular disorders, septicemia and renal failure. The post-partum specimens included were preserved in 10% formalin immediately after

Name & Address of Corresponding Author

Dr Harpal Singh Seemar,
Professor,
Department of Pathology
Govt. Medical College
Patiala.

autopsy and were received in fully sealed jars. A thorough gross examination of renal specimens including measurements, weights, consistency, cut surface, details of any lesions if preserved were recorded. Subsequently samples were taken from representative areas of the specimen and were processed for histopathology. Haematoxylin and Eosin (H & E) staining were done for the prepared samples according to the standard technique.^[2] The sections were thoroughly examined microscopically on 4x, 10x, and 40x power of the microscope for any pathology and the results were recorded. The data was compiled and the various pathological diagnosis were analyzed statistically among total 150 cases studied.

RESULTS

A total of 232 renal specimens were examined in the department of Pathology over the given span of time. Out of these, 82 specimens were autolyzed and hence excluded. The remaining 150 cases were selected for the present study. In this study minimum age of the deceased was 11 months and the maximum age was 89. Mean age was 40.7 years with a standard deviation of 17.66 years. Maximum number of subjects were in the age group 41-50 years (22.67%) followed by 51-60 years (18.67%). Of the 150 subjects 72% were male and 28% were female. Among the males, maximum number of subjects were in the age group of 41-50 (22.22%) followed by 51-60 years (19.44%). Among the females, maximum females were in the age group 41-50 years (23.80%) followed by 31-40 years (21.40%).

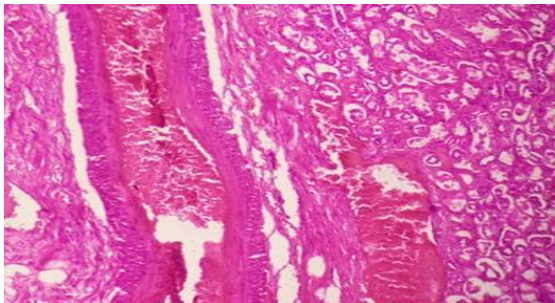


Figure 1: Section of Kidney suggestive of Benign Nephrosclerosis (H&E x 400)

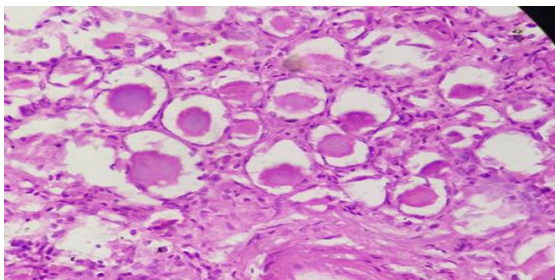


Figure 2: Section of Kidney showing dilated tubule with flattened epithelium filled with casts resembling thyroid colloid and interstitial infiltration by chronic inflammatory infiltrate. Features are suggestive of chronic pyelonephritis. (H&E x 400)

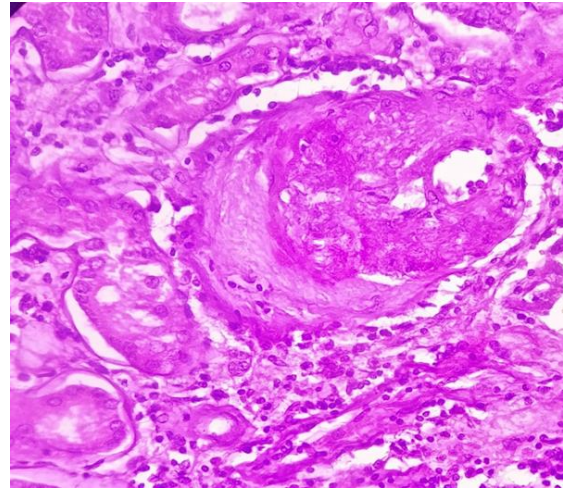


Figure 3: Section of Kidney showing renal parenchyma exhibiting diffuse and nodular glomerulosclerosis, tubular atrophy, interstitial fibrosis, thickened blood vessels and focal chronic inflammatory infiltrate. Features are suggestive of Diabetic Nephropathy. (H&E x 400)

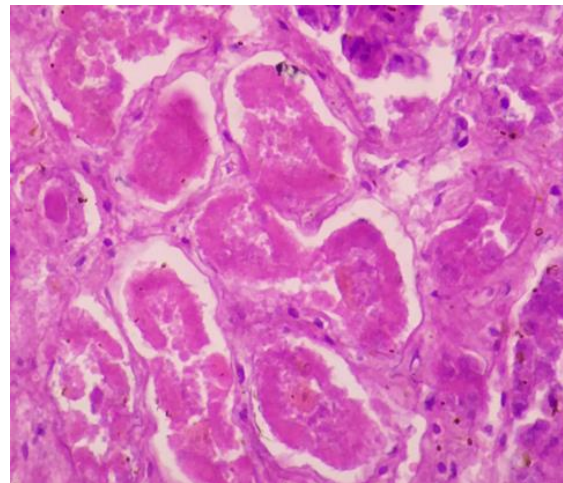


Figure 4: Section of Kidney showing enlarged individual tubular lining cells and filled with eosinophilic granules in cytoplasm. Features are s/o cloudy swelling in tubules

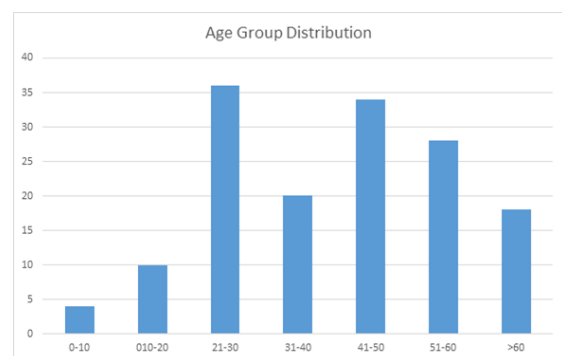


Figure 5: Number of study cases distributed in different age groups as depicted in above table.

In this study, in 57 cases (38%) microscopic findings were close to normal histology with no nephropathological diagnosis. Remaining 93 cases

(62%) cases had nephropathological findings in which the percentage of non-glomerular pathologies (45.3%) were higher as compared to glomerular lesions (16.6%). 25 cases with glomerular pathology included 8 cases of diabetic nephropathy and 17 cases with benign nephrosclerosis. 68 cases with tubular and interstitial pathology included 43 cases of acute tubular necrosis (28.6%), 3 cases with acute pyelonephritis (2%), 2 cases with chronic pyelonephritis (1.3%) and 20 cases were noted to have cloudy swelling in the tubule (13.3%).

Table 1: Distribution of cases as per the Pathological diagnosis made after gross and microscopic examination of autopsy specimen.

Renal Pathology	Frequency	Percentage
Acute Tubular Necrosis	43	28.60
Cloudy Swelling In Tubule	20	13.30
Acute Pyelonephritis	03	02.00
Chronic Pyelonephritis	02	1.33
Diabetic Nephropathy	08	5.33
Benign Nephrosclerosis	17	11.33
Unremarkable	57	38.00
Total	150	100.00

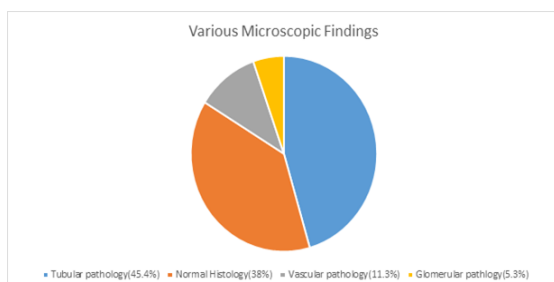


Figure 6: Distribution of various microscopic findings among 150 autopsy cases studied.

In the present study acute tubular necrosis was seen most commonly in the age group of 41-50 years (39.5%). Benign nephrosclerosis was seen in elderly age group majority being diagnosed between 51-60 years of age. Majority of acute pyelonephritis cases were seen at greater than 60 years of age. 2 cases of chronic pyelonephritis were seen in the age group of 41-50 years and >60 years. Cloudy swelling in the tubule were noted mainly between age groups of 21-30 years and 31-40 years. 20 cases of cloudy swelling in tubule had 14 males and 6 females.

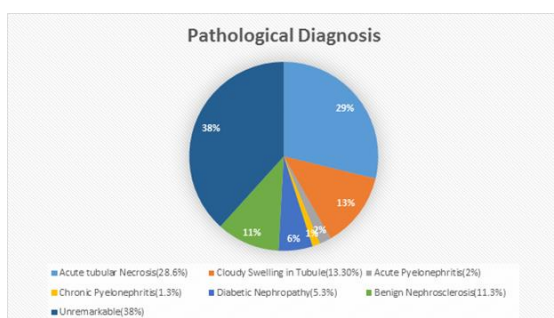


Figure 7: Distribution Of various diseases diagnosed on the basis of microscopic findings of autopsy cases studied.

DISCUSSION

Renal autopsy helps to identify likely pathological cause of death and helps to understand the disease process and sequence of events following an insult.^[3] In the present study, autopsy findings showing normal histology (38%) were in close concordance with the study done by Usta et al.^[4] where 23 cases out of 55 renal autopsies were close to normal histology.(41.8%). Similarly study done by Sandhu et al.^[5] had 27 cases out of 120 renal(22.5%) autopsies where findings were close to normal histology with no specific pathology seen.

Table 2: Comparison of normal histology among various studies

S.No	Various Studies	Results
1.	Sandhu et al. (5) (2017)	27 cases out of 120 (22.5%)
2.	Usta et al. (3) (2014)	23 cases out of 55 (41.8%)
3.	Present Study	57 cases out of 150 (38%)

Tubular lesions in renal autopsy most commonly include acute tubular necrosis.^[6] Acute tubular necrosis (ATN) is a syndrome of intrinsic renal failure secondary to ischemic or toxic insults. The histopathologic findings of ATN are inconstant. When present, they are limited to the tubulo-interstitium and often subtle despite profound dysfunction. The syndrome of acute renal failure (ARF) is common, particularly in hospitalized patients. In diabetic nephropathy tubular basement membrane thickening of non-atrophic tubules is apparent from the development of class II glomerular diabetic lesions and becomes more conspicuous in class III and IV, which is best seen in PAS or silver stains. Interstitial fibrosis and tubular atrophy (IFTA) follow glomerular changes in type 1 DN that ultimately lead to ESRD.^[7-10] In the present study 46% autopsies noted to have tubular pathology which was in close similarity to previous studies like Usta et al,^[3] Sandhu et al.^[5] and Chetan et al.^[11] where incidence of tubular pathology was 41.80%, 34.16% and 32.14% respectively.

Table 3: Comparison of incidence of tubular pathologies diagnosed in various studies.

S. No.	Various Studies	Results
1.	Sandhu et al. (5) (2017)	41 cases out of 120 cases (34.16%)
2.	Chethan et al. (11) (2016)	09 cases out of 28 cases (32.14%)
3.	Usta et al. (3) (2014)	23 cases out of 55 cases (41.80%)
4.	Present study	69 cases out of 150 cases (46.00%)

In the present study most common tubular pathology was acute tubular necrosis (28.60%) which had close similarity with Chethan et al.^[4] and Sandhu et al.^[5] where incidence of acute tubular necrosis accounted for 35.71% & 22.16% respectively.

Table 4: Comparison of incidence of Acute tubular necrosis with various other studies.

S.No.	Various Studies	Acute Tubular Necrosis
1.	Chethan et al. ^[11] (2016)	10 OUT OF 28 Cases (35.71%)
2.	Sandhu et al. ^[5] (2017)	27 OUT OF 120 Cases (22.16%)
3.	Present Study	43 out of 150 Cases (28.60%)

Glomerular pathologies found in renal autopsy includes rapidly progressive glomerulonephritis which is the most serious of all glomerulonephritis with the potential to destroy renal function within days. Although causes are heterogeneous, they are united by the histological finding of extensive crescents (a proliferation of parietal epithelial cells and mononuclear phagocytes with possible fibroblasts in Bowman's capsule) affecting more than 50% of glomeruli.^[12-13] In diabetic nephropathy, although tubular, interstitial and arteriolar lesions are ultimately present in type 1 diabetes, as the disease progresses, the most important structural changes involve the glomerulus. In contrast, a substantial subset of type 2 diabetic patients, despite the presence of microalbuminuria or proteinuria, have normal glomerular structure with or without tubulo-interstitial and/or arteriolar abnormalities.^[14]

In the present study glomerular pathologies were 6% of the total cases studied with a similar lower incidence of glomerular pathology (16.6%) noted by Sandhu et al.^[5] In contrast a higher incidence of glomerular pathologies was noted in Usta et al.^[3] equating to 40% of the total cases studied. In this study 25 cases with glomerular pathology included 8 cases of diabetic nephropathy and 17 cases with benign nephrosclerosis.

Table 5: Comparison of incidence of Glomerular pathologies with various other studies.

S.No.	Various Studies	Results
1.	Sandhu et al. ^[5] (2017)	20 cases out of 120 (16.66%)
2.	Usta et al. ^[3] (2014)	22 cases out of 55 (40%)
3.	Present Study	09 cases out of 150 (6%)

Hyalinosis of the efferent arteriole is relatively specific for DN, but hyalinosis of the afferent arteriole occurs in numerous other settings. Chronic cyclosporine nephropathy is a typical example in which arteriolar hyalinosis occurs outside DN. Efferent arteriolar hyalinosis is an important lesion by which DN is distinguished from hypertensive nephropathy.^[15]

18 autopsy cases in this study revealed vascular lesions equating to 12% of total cases studied contrast to a slightly higher incidence of vascular pathologies were observed by Sandhu et al.^[5] & Usta et al.^[3] Being 25% and 27% respectively which included moderate to severe intimal thickening and subintimal hyaline depositions as well.

Nephrosclerosis was seen predominantly in elderly population with 58.5% cases having age > 50 years with a similar finding in Usta et al.^[3]

Table 6: Comparison of incidence of Vacular pathology among various studies.

S.No	Various Studies	Results
1.	Sandhu et al. ^[5] (2017)	30 cases of 120 (25%)
2.	Usta et al. ^[3] (2014)	15 cases of 55 (27%)
3.	Present Study	25 cases of 150(16%)

CONCLUSION

In the present study majority of renal autopsies revealed histopathological pattern suggestive of tubular pathologies of which most common was acute tubular necrosis as a cause of sudden collapse of patient leading to death.

REFERENCES

- Kandy NC, Pai MR, Reba PT. Role of Histopathology on autopsy study: An Audit. SAS J Med. 2015;1(1):7-15.
- Clayden EC. Practical Section cutting and staining. (5th edn.) Churchill Livingstone 1971;115.
- Usta U, Tastekin E, Isler E, Kutlu AK, Puyan FO. Histopathological and immune alterations in autopsied kidneys. Saudi Med J. 2014;35(11):1331-38.
- Chethan K, Shashikala P, Pruthvi D, Kavita GU. Histomorphological spectrum of kidney lesions in nephrectomies and autopsies. Int J Sci res.2016;5(4):2277-8179.
- Sandhu VK, Puri A, Singh N. Histomorphological Spectrum of Renal Lesion in An Autopsy Study. Ann Pathol Lab Med.2017;4(4).
- Rosen S, Stillman IE. Acute Tubular Necrosis is a Syndrome of Physiological and Pathological Dissociation. J Am Soc Nephrol.2008;19(5):871-875.
- Horlyck A, Gundersen HJ, Osterby R. The cortical distribution pattern of diabetic glomerulopathy. Diabetologia. 1986;29:146-50.
- Najafian B, Caramori ML, Mauer M. Clustering of type 1 and type 2 diabetic patients based on diabetic nephropathy structural-functional relationships. J Am Soc Nephrol. 2005;16:679A.
- Cohen Tervaert WT et al. Pathologic Classification of Diabetic Nephropathy. J Am Soc Nephrol.2010;21(4): 556-63.
- Mauer SM, Steffes MW, Ellis EN, Sutherland DE, Brown DM, Goetz FC. Structural-functional relationships in diabetic nephropathy. J Clin Invest. 1984;74:1143-55.
- Chethan K, Shashikala P, Pruthvi D, Kavita GU. Histomorphological Spectrum Of Kidney Lesions In Nephrectomies & Autopsies. Int J Sci res.2016;5(4):2277-8179.
- Tipping PG, Kitching AR, Cunningham MA. Immunopathogenesis of crescentic glomerulonephritis. Curr Opin Nephrol Hypertens.1999;8:281-6.
- D'Amico G, Fornasieri A. Cryoglobulinaemic glomerulonephritis: a membranoproliferative glomerulonephritis induced by hepatitis C virus. Am J Kidney Dis.1995;25:361-9.
- Qian Y, Feldman E, Pennathur S, Kretzler M, Brosius FC. From fibrosis to sclerosis: Mechanisms of glomerulosclerosis in diabetic nephropathy. Diabetes. 2008;57:1439-45.

15. Harris RD, Steffes MW, Bilous RW. Global glomerular sclerosis and glomerular arteriolar hyalinosis in insulin-dependent diabetes. *Kidney Int.* 1991;40:107–14.

How to cite this article: Garg M, Seemar HS, Kundal R, Aggarwal A. Renal Pathologies in Medicolegal Autopsies (150 Cases). *Ann. Int. Med. Den. Res.* 2019; 5(3):PT28-PT32.

Source of Support: Nil, **Conflict of Interest:** None declared