

# Histopathological Patterns of the Testicular Biopsies and its Role in the Evaluation of Infertility Among Azoospermic Male Patients: A Hospital Based Study From Northern India.

Mahmood Ali Sayed<sup>1</sup>, Abha Mathur<sup>2</sup>, Narayani Joshi<sup>2</sup>, Deepak Juyal<sup>3</sup>, Ajit Thakur<sup>4</sup>

<sup>1</sup>Assistant Professor, Department of Pathology, Jaipur National University Institute Of Medical Sciences & Research Centre, Jaipur, Rajasthan – 302017.

<sup>2</sup>Professor, Department of Pathology, Mahatma Gandhi Medical College and Hospital, Sitapura, Jaipur, Rajasthan – 302022.

<sup>3</sup>Assistant Professor, Department of Microbiology, Govt. Doon Medical College, Dehradun, Patelnagar, Dehradun, Uttarakhand – 248001.

<sup>4</sup>Assistant Professor, Department of Biochemistry, Jaipur National University Institute Of Medical Sciences & Research Centre, Jaipur, Rajasthan – 302017.

Received: May 2019

Accepted: May 2019

**Copyright:** © the author(s), publisher. It is an open-access article distributed under the terms of the Creative Commons Attribution Non-Commercial License, which permits unrestricted non-commercial use, distribution, and reproduction in any medium, provided the original work is properly cited.

## ABSTRACT

**Background:** To identify and categorize various pathological patterns seen in testicular biopsies of azoospermic males along with their Johnson's score and to evaluate the importance of the histological examination of testicular biopsies for further clinical planning. **Methods:** The study was conducted in the Department of Pathology of Mahatma Gandhi Medical College and Hospital, Jaipur, India. Slides prepared from testicular biopsies either unilateral or bilateral (received between January 2003 to December 2012), of 135 patients who had azoospermia on routine semen analysis were retrospectively retrieved and reviewed. Various histopathological patterns were evaluated and categorized and were graded according to the Johnson's scoring. If more than one histological pattern was noted in the same testicular biopsy it was called as 'Mixed pattern' whereas if the right and left testes showed different histological pattern it was called as 'Discordant pattern'. **Results:** A total of 152 testicular biopsies were collected from 135 patients (118 patients with unilateral and 17 patients with bilateral testicular biopsies). All the patients had azoospermia on routine semen analysis. The age of the patients ranged from 20 to 51 years. The most common histological pattern observed was Normal spermatogenesis (35.56%) followed by Sertoli cell only syndrome (23.70%) and Germ cell maturation arrest (20%). Hypospermatogenesis and Seminiferous tubule hyalinization was seen only in 2.96% and 2.22% of the cases respectively. **Conclusion:** This study has shed some light on the possible underlying etiologies of primary male infertility and emphasizes the need for bilateral testicular biopsies and on meticulous pathological examination of all seminiferous tubules in order to identify mixed and discordant patterns. The data extrapolated from our study can serve as a template for better management of primary male infertility and will optimize the advanced therapeutic modalities for the infertile couples.

**Keywords:** Intra cytoplasmic sperm injection, In vitro fertilization, Johnson's score, Spermatogenesis, Testicular sperm extraction.

## INTRODUCTION

Infertility, a common problem worldwide is a cause of emotional and medical distress for the infertile couples.<sup>[1]</sup> Infertility is defined as inability to conceive after 12 months of regular unprotected intercourse.<sup>[2]</sup> Despite of the fact that male infertility is a major cause of infertility among couples contributing to more than half of such cases, it is a

common practice in our social setup to stigmatize only the female partner in cases of infertility.<sup>[3]</sup> Even the investigations of couple infertility have always been concentrated on female pathological causes, while male clinical conditions leading to infertility are generally ignored, underrated and under diagnosed. Therefore, a complete evaluation of the male partner, especially of the status of spermatogenesis becomes more imperative and important.

Evaluation of male infertility includes a thorough clinical history taking, physical examination, semen analysis and hormonal assay. Additional tests include detection of antisemen antibodies, transrectal ultrasonography, vasography, hormonal profile, genetic studies and testicular biopsy, providing a

### Name & Address of Corresponding Author

Dr. Ajit Thakur,  
Assistant Professor,  
Department of Biochemistry,  
Jaipur National University Institute Of Medical Sciences &  
Research Centre,  
Jaipur, Rajasthan – 302017.

## Sayed et al; Histopathological Patterns of the Testicular Biopsies in Azoospermic Male Patients

bewildering array of diagnostic options available. Although these tests are not always conclusive but testicular biopsy in particular can be very helpful in definitive diagnosis of variety of testiculopathies, and can be a cornerstone in diagnosing male primary infertility. Evaluation of testicular biopsy in case of azoospermia or oligospermia provides reliable information regarding spermatogenesis, which can further be categorized into various pathological patterns.<sup>[4]</sup> It can predict the sperm output and differentiate between obstructive and non-obstructive azoospermia, and can also provide significant prognostic information for assisted reproductive techniques like in vitro fertilization (IVF), testicular sperm extraction (TESE) and intra cytoplasmic sperm injection (ICSI).<sup>[5,6]</sup> The valuable information thus gained can be helpful to clinician for prognostic and therapeutic purposes.

Infertility is a common problem observed in our daily clinical practice. Testicular biopsies from infertile man with azoospermia or oligospermia usually show different pathological patterns. The aim of the present study was to identify and categorize various pathological patterns seen in testicular biopsies of males with infertility and were categorized on the basis of Johnson's scoring. The results obtained were used to reappraise the value of testicular biopsies in the management of male infertility.

### MATERIALS AND METHODS

The study was conducted in the Department of Pathology of Mahatma Gandhi Medical College and Hospital, Jaipur. Slides prepared from testicular biopsies either unilateral or bilateral (received between January 2003 to December 2012), of 135 patients who had azoospermia on routine semen analysis were retrospectively retrieved and reviewed. Clinical details and semen analysis results were also retrieved from the patient's medical records. The hematoxylin and eosin (H and E) stained slides previously prepared from the testicular biopsies were reexamined histologically by light microscopy and various histopathological patterns were evaluated and categorized and were graded according to the Modified Johnson's scoring (which was not done in initial evaluation). Histological uniformity within the same testis as well as between the right and left testes was noted. If more than one histological pattern was noted in the same testicular biopsy it was called as 'Mixed pattern' whereas if the right and left testes showed different histological pattern it was called as 'Discordant pattern'. All testicular biopsies were categorized histologically and tabulated [Table 1] into seven categories as follows.<sup>[7]</sup>

1. **Normal Spermatogenesis (NS):** The seminiferous tubules are lined by thin basement membrane and the germinal epithelium shows normal progression from spermatogonia to

spermatocytes along with spermatids and spermatozoas. [Figure 1]

2. **Hypospermatogenesis (HS):** The germinal epithelium shows all the stages of germ cells but the number is reduced. [Figure 2a]
3. **Germ cell maturation arrest (GCMA):** At a specific cell stage the process of spermatogenesis is arrested usually at the level of primary or secondary spermatocytes. [Figure 2b]
4. **Sertoli cell only syndrome (SCOS):** The tubules contain only Sertoli cells and no other cells of spermatogenesis. [Figure 2c]
5. **Seminiferous tubule hyalinization (STH):** The tubules have much thickened basement membrane with a smaller diameter along with tubular collagenization. There is no germinal epithelium. [Figure 2d]
6. **Mixed pattern:** There is variation in the histopathological pattern in the same testicular biopsy
7. **Discordant pattern:** There is variation in the histopathological pattern of right and left testes.

The number of the cases and their percentages for various histopathological patterns were calculated.

In addition to categorizing the cases according to the histopathological patterns, they were also graded according to the Johnson's scoring system.<sup>[8]</sup> According to this scoring system the testicular biopsies were further evaluated and given a score from 1 to 10. Johnson scoring is given as follows:

**Score 10:** There is full spermatogenesis

**Score 9:** Incomplete spermatogenesis with many late spermatids

**Score 8:** There are less than 5 spermatozoa per tubules and a few late spermatids

**Score 7:** There are many early spermatids but no spermatozoa or late spermatids.

**Score 6:** There are few early spermatids but no spermatozoa or late spermatids

**Score 5:** there are many spermatocytes but no spermatozoas or spermatids

**Score 4:** There are few spermatocytes but no spermatozoas or spermatids

**Score 3:** There are only spermatogonia

**Score 2:** Only presence of Sertoli cells and no germinal epithelial cells

**Score 1:** There is no seminiferous epithelium

In each case the findings were recorded on a proforma

### RESULTS

A total of 152 testicular biopsies were collected from 135 patients (118 patients with unilateral and 17 patients with bilateral testicular biopsies). All the patients had azoospermia on routine semen analysis. The age of the patients ranged from 20 to 51 years and the most common age group of 26 to 35 years comprised around 71% (96) of the patients.

Out of 118 (87.41%) patients with unilateral biopsies, 104 (77.04%) showed uniform pattern i.e.

same pattern in all seminiferous tubules, whereas 14 (10.37%) showed heterogeneous (mixed) pattern i.e. more than one pattern in different seminiferous tubules. Out of 17 (12.59%) patients with bilateral biopsies, 10 (7.41%) showed uniform pattern in both the biopsies, whereas 4 (2.96%) showed discordant pattern. In 3 (2.22%) cases of the bilateral testicular biopsies, there was insufficient biopsy material in either of the two biopsies. Histopathological classification of the testicular biopsies of all the 135 patients is enumerated in Table 1. The most common histological pattern seen was NS (35.56%) followed by SCOS (23.70%) and GCMA (20%). HS and STH was seen only in 2.96% and 2.22% of the cases respectively.

**Table 1: Histopathological classification of the testicular biopsies (n=135)**

S.no	Histopathological classification	Number of cases (%)
1.	Normal Spermatogenesis (NS)	48 (35.60%)
2.	Sertoli Cell Only Syndrome (SCOS)	32 (23.70%)
3.	Germ Cell Maturation Arrest (GCMA)	27 (20.00%)
4.	Mixed Pattern	14 (10.30%)
5.	Hypospermatogenesis (HS)	04 (02.96%)
6.	Seminiferous Tubule Hyalinization (STH)	03 (02.22%)
7.	Discordant pattern (B/L Testicular Biopsies)	04 (03.00%)
8.	Insufficient Biopsies	03 (02.22%)
	Total	135 (100%)

**Table 2: Unilateral testicular biopsies with mixed histopathological patterns (n=14)**

Mixed Histopathological Pattern	Number
Sertoli Cell Only Syndrome + Germ Cell Maturation Arrest (Figure 3a)	05
Sertoli Cell Only Syndrome + Hypospermatogenesis (Figure 3b)	05
Sertoli Cell Only Syndrome + Seminiferous Tubule Hyalinization (Figure 3c)	01
Sertoli Cell Only Syndrome + Normal Spermatogenesis (Figure 3d)	01
Germ Cell Maturation Arrest + Normal Spermatogenesis	02
Total	14

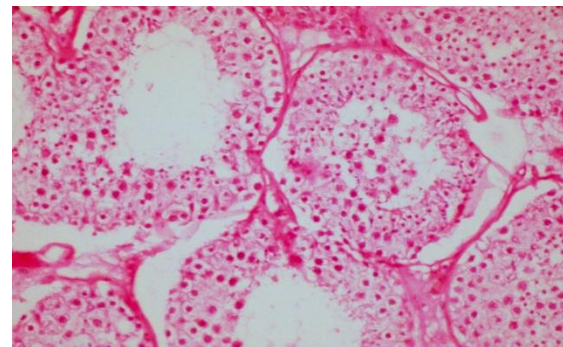
**Table 3: Histopathological classification of bilateral testicular biopsies (n=17)**

Histopathological Pattern	Number
Similar pattern in both right and left biopsies	10
Discordant Pattern	
GCMA + SCOS	01
SCOS + (SCOS + GCMA)	02
HS + NS	01
Insufficient Biopsy	
SCOS + STH (LTB) and only epididymal tissue (RTB)	01
SCOS + GCMA (LTB) and only epididymal tissue (RTB)	01
SCOS + HS (LTB) and only epididymal tissue (RTB)	01
Total	17

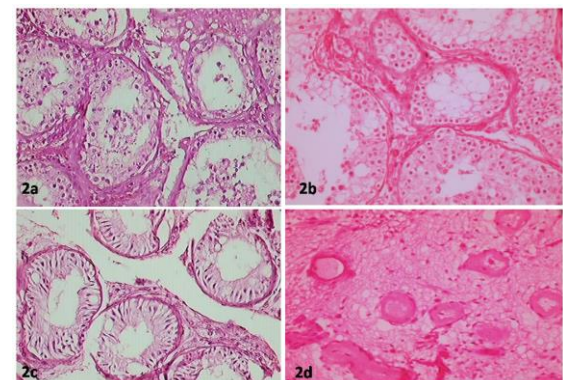
GCMA: Germ Cell Maturation Arrest; SCOS: Sertoli Cell Only Syndrome; HS: Hypospermatogenesis; NS: Normal Spermatogenesis; STH: Seminiferous Tubule Hyalinization; LTB: Left testicular biopsy; RTB: Right testicular biopsy

**Table 4: Characterization of Testicular biopsies according to Johnson's Scoring system (n=149)**

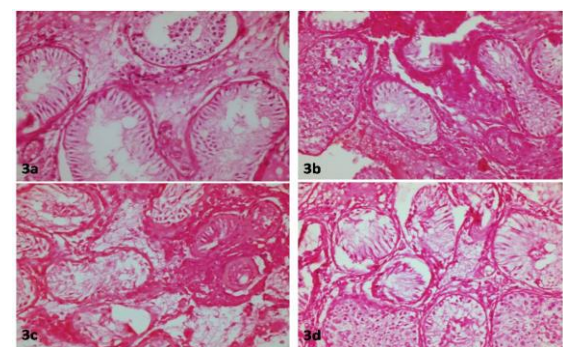
Johnson's Score	Number of biopsies (%)
10	48 (32.20%)
09	04 (2.68%)
08	05 (3.36%)
07	02 (1.34%)
06	05 (3.36%)
05	25 (16.78%)
04	05 (3.36%)
03	04 (2.68%)
02	45 (30.20%)
01	06 (04.03%)



**Figure 1: Normal Spermatogenesis (H & E x 400)**



**Figure 2: a) Hypospermatogenesis; b) Germ cell maturation arrest; c) Sertoli cell only syndrome; d) Seminiferous tubule hyalinization (H & E x 400)**



**Figure 3: Showing mixed histopathological patterns in unilateral testicular biopsies, a) Sertoli cell only syndrome + Germ cell maturation arrest; b) Sertoli cell only syndrome + Hypospermatogenesis; c) Sertoli cell only syndrome + Seminiferous tubule hyalinization; d) Sertoli cell only syndrome + Normal Spermatogenesis (H & E x 400)**

The histopathological classification of 14 unilateral testicular biopsies, which showed mixed pattern, and 17 bilateral testicular biopsies is depicted in [Table 2 & Table 3] respectively.

Johnson's scoring was done for quantitatively describing spermatogenesis, by assessing atleast 100 tubules. Scoring for each testicular biopsy was carried out separately. Out of total 152 testicular biopsies, 149 were considered for Johnson's scoring, excluding the three insufficient biopsies. Scoring for these 149 testicular biopsies is depicted in [Table 4].

## DISCUSSION

Male infertility is a reproductive health problem, which contributes to significant number of cases of infertility. However due to various social reasons and stigma associated with it, the problem is often under reported and undertreated. Causes of male infertility are divided into three major categories viz. pre-testicular, testicular and post-testicular. The pre-testicular causes include extragonadal etiologies such as endocrine disorders originating in hypothalamus, pituitary or adrenals, chronic illnesses including diabetes mellitus and hypertension, as well as certain medications. The testicular causes include defects in the process of spermatogenesis and post-testicular causes include obstructions of ducts draining the testes, related to trauma, surgery or orchitis.<sup>[9]</sup> The distinction between post-testicular obstructive and pre-testicular or testicular non-obstructive causes of male infertility is important since men with obstructive etiologies may have other cost-effective options for treatment, such as microsurgical reconstruction of the reproductive tract.<sup>[9]</sup>

Although semen analysis is considered as one of the most important investigation in the evaluation of male infertility, testicular biopsy remains the key investigation for all testicular causes of infertility.<sup>[10]</sup> It is helpful at reaching the definitive diagnosis as well as therapeutic management of primary male infertility. With the advent of micromanipulation techniques in the field of fertility management, now even a single viable sperm can be used to fertilize an ovum. As the name implies testicular biopsy consists of an operative removal of a small bit of tissue from the testis, small enough to have no deleterious effects on the normal functioning of the gland, yet large enough to include a representative sample of the whole gland. Since the nature of various lesions may differ from one testis to another and mixed histopathological patterns are common, it is recommended to obtain bilateral testicular biopsies when studying male infertility.<sup>[5,6]</sup>

In the present study we outlined the different patterns of testicular biopsies in cases of primary male infertility and scored them as per the modified Johnson's scoring system. The most common age group in our study was 26 to 35 years (96 cases),

which comprised of around 71% of all the cases. Our finding was in tandem with the previous studies by Purohit et al. and Parikh et al.<sup>[11,12]</sup> who reported it to be 76% and 70% respectively in the same age group. We also found that 20.74% of the patients were below 25 years of age. Similar finding was reported by Parikh et al. who reported 25% of the cases below 25 years of age.<sup>[12]</sup> The probable reason is the early age of marriage in India. In contrast Purohit et al.<sup>[11]</sup> in their study reported only 8% of the cases below 25 years of age.

Out of the total 135 cases studied the most common histopathological pattern seen was normal spermatogenesis (NS) and was identified in 35.6% of cases, suggesting possible post testicular obstructive etiologies. Similar findings were reported in previous studies from India (36.25%), Pakistan (35%), Nigeria (38%),<sup>[12-14]</sup> However various other studies observed a lower incidence of NS.<sup>[8,9,15,16]</sup> NS suggests obstruction of some part of the ductal system such as varicocele and obstruction of the rete testes, but has a good prognosis with assisted reproductive technologies (ART).

Second most common histopathological pattern seen in the present study was SCOS and was identified in 23.7% of the cases. Similar findings were reported in previous studies by Purohit et al. and Parikh et al. from India who observed the incidence of SCOS in 26% and 18.75% of cases respectively.<sup>[11,12]</sup> A much higher incidence of 39% was reported in a study from Saudi Arabia.<sup>[17]</sup> In contrast to our findings, a study from Pakistan reported a lower incidence of 7.5% in their study.<sup>[13]</sup> SCOS is an irreversible change that can be associated with various underlying conditions viz. cryptorchid testes, orchitis, post radiation or chemotherapy, estrogen or androgen therapy and chronic hepatopathology.<sup>[7]</sup> More recently structural abnormalities of the Y chromosome, particularly deletions of a gene called human azoospermia factor (AZF) located in the long arm of Y chromosome have been identified as the underlying cause for disturbed spermatogenesis and azoospermia.<sup>[18]</sup>

The incidence of GCMA in the present study was 20%, the finding that is in contrast with several previous studies where GCMA has been reported to range from 1.75 to 12%.<sup>[11-16]</sup> A study from Egypt reported the incidence of GCMA to be 28%,<sup>[9]</sup> which is in parallel to our findings. GCMA is characterized by a block in the maturation to spermatids hence there are no mature spermatids present. The underlying etiologies may be genetic (trisomy, balanced autosomal anomalies or deletions in the Y chromosome e.g. YqII) or secondary influences (chronic alcoholism, consumption of toxic agent, chronic marijuana use, cytotoxic chemotherapy and hypogonadotropic hypogonadism).<sup>[7,18]</sup>

Hypospermatogenesis (HS) was seen only in 3% of the cases in present study, a finding which is in parallel with previous studies by Thomas et al,

## Sayed et al; Histopathological Patterns of the Testicular Biopsies in Azoospermic Male Patients

Parikh et al. and Ahmad et al., who reported it in 3.7%, 7.5% and 10% of cases respectively.<sup>[12,13,19]</sup> In contrast to our findings some previous studies have reported a higher incidence of HS. Haddad et al from Jordan and Jamali et al. from Iran in their studies reported HS in 55.8%, and 36.6% of cases.<sup>[15,20]</sup> HS in particular is defined as an equivalent decrease in the numbers of spermatogonia and primary spermatids. In other words all elements of spermatogenesis are present but decreased in number.<sup>[7]</sup> Clinically HS can be associated with normal dysregulation, congenital germ cell deficiency, androgen insensitivity, chemical exposure and exposure to heat and radiation.<sup>[21]</sup> Difference in the values reported in various studies can be explained by the different criterion used for patient selection for biopsies. Some centers consider testicular biopsies only for patients with azoospermia, while others perform it for patients with either azoospermia or oligospermia. In the current study testicular biopsy was performed for patients with azoospermia.

STH was reported only in 2.2% cases of our study. A much higher incidence has been reported by various other studies,<sup>[14,18-20,22]</sup> however similar to our findings some other studies have reported a lower incidence.<sup>[8,9,17]</sup> Although the reason behind this discrepancy is unknown, we speculate that the biopsy selection criterion followed by different urologists may be one of the reasons.

Among the unilateral testicular biopsies, mixed pattern was seen in 10% of the cases and among the bilateral testicular biopsies the discordant pattern was seen in 2.96% of cases. The incidence of mixed pattern within the same biopsy and the presence of discordant patterns in bilateral testicular biopsies are common.<sup>[23]</sup> These findings substantiate the use of bilateral testicular biopsies for comprehensive evaluation of male infertility and the importance of meticulous pathological evaluation and reporting of all the observed patterns. Moreover there is an important therapeutic benefit in performing bilateral testicular biopsies when ICSI is being considered as an option for management of male infertility. ICSI depends on the sperm retrieval and subsequent injection into a female ovum. The absence of sperm in one testis in such cases does not rule out their presence in another.

The present study outlines the different patterns of testicular biopsy in cases of primary male infertility. We identified 'post testicular obstruction' as the most common cause of primary infertility in our region as 35.6 of cases showed NS. Obstructive etiology, although one of the major causes responsible for male infertility, has a good prognosis. The obstruction may occur at the level of epididymis or vas deferens.<sup>[24]</sup> In case of obstruction at the level of epididymis, the semen volume is normal, fructose is present, the PH is alkaline and no sperm precursor cells are seen on semen analysis.<sup>[24]</sup>

On clinical examination they typically have normal sized firm testes, but epididymis is full and turgid.<sup>[24]</sup> In case of obstruction at the level of vas deference, the semen volume is low (0.5 ml or less), fructose is absent and the PH is acidic. The non-obstructive azoospermia is commonly associated with HS, GCMA, SCOS or STH on testicular biopsies. Previously it was assumed that male infertility with non-obstructive azoospermia is irreversible but in the early studies of quantitative analysis of spermatogenesis it was observed that azoospermic men with germinal failure often have minute foci of spermatogenesis.<sup>[25]</sup> Therefore testicular histopathological patterns are useful for further workup of infertile males and for therapeutic sperm retrieval in assisted reproductive techniques.<sup>[25]</sup>

### CONCLUSION

Histopathological examination of the testis gives a correct assessment of the spermatogenesis and allows a rational choice for the future management by reconstructive surgery, hormonal therapy, artificial donar insemination or adoption. This study has shed some light on the possible underlying etiologies of primary male infertility and emphasizes the need for bilateral testicular biopsies and on meticulous pathological examination of all seminiferous tubules in order to identify mixed and discordant patterns. The data extrapolated from our study can serve as a template for better management of primary male infertility and will optimize the advanced therapeutic modalities for the infertile couples. A multidisciplinary approach involving the pathologist, gynecologist and the urologist can be helpful in management of such cases effectively and efficiently provided that the diagnostic and prognostic measures available are used to their fullest extent.

### REFERENCES

1. HU Na'aya, HA Nggada, D Dogo. Testicular Biopsy In The Evaluation Of Male Infertility In Maiduguri North-Eastern Nigeria. Highland Medical Research Journa 2004;2(1): 37-40
2. Gnoth C, Godehardt E, Frank-Herrmann P, Friol K, Tigges J, Freundl G. Definition and prevalence of subfertility and infertility. Hum Reprod 2005;20(5):1144-7
3. A Ahmed, A Bello. Role of Testicular Biopsy in the Evaluation of Male Infertility. African Journal of Urology 2007;13 (2):107-111
4. Rosai J. Rosai and Ackerman's Surgical Pathology. Abdullah and Bondagji: Histopathological patterns of testicular biopsy in male infertility. 9 th ed. Vol. 1. p.1260-5.<sup>[1]</sup>
5. Glina S, Soares JB, Antunes N Jr, Galuppo AG, Paz LB, Wonchockier R. Testicular histopathological diagnosis as a predictive factor for retrieving spermatozoa for ICSI in non-obstructive azoospermic patients. Int Braz J Urol 2005;31(4):338-41
6. Cerilli LA, Kuang W, Rogers D. A practical approach to testicular biopsy interpretation for male infertility. Arch Pathol Lab Med 2010;134(8):1197-204.<sup>[1]</sup>

*Sayed et al; Histopathological Patterns of the Testicular Biopsies in Azoospermic Male Patients*

7. Nistal M, Paniagua R. Testicular biopsy. Contemporary interpretation. *Urol Clin North Am* 1999;26(3):555-93
8. Nagpal BL, Manjari M, Kapoor K, Dhaliwal US. Testicular biopsy in cases of male infertility: A retrospective study. *J Indian Med Assoc* 1993;91:171-4.
9. Rashed M, Ragab N, Shalaby A, Ragab W. Patterns of testicular histopathology in men with primary infertility. *Int J Urol* 2008;5:1-5
10. Oranusi C, Onyiaorah IV, Ukah CO. Pattern of testicular biopsies as seen in a tertiary institution in Nnewi, Southeast Nigeria. *Niger J Surg* 2014;20:55- 8.
11. Purohit TM, Purohit MB, Dabhi BJ. Study of semen analysis and testicular biopsy in infertile male. *Indian J. Pathol Microbiol* 2004; 47(4): 486-490.
12. Parikh UR, Goswami HM, Deliwala KJ, Shah AM, Barot HP. Testicular biopsy in male infertility: Study of 80 cases. *Journal International Medical Sciences Academy* 2012; 25: 75-77.
13. Ahmad M, Ahmad M, Ahmad R, Khan N. Role of testicular biopsy in male infertility. *Pak armed Forces Med J* 2002; 52(1): 66-71.
14. Thomas JO. Histological pattern of testicular biopsies in infertile males in Ibadan, Nigeria. *East Afr Med J* 1990;67:578-84.
15. Haddad FH, Omari AA, Malkawi OM, Ajour WK, Izat A, Khasrof H, et al. Patterns of testicular cytology in men with primary infertility: Any change since the Gulf War? *Acta Cytol* 2004;48:807-12.
16. Abdullah L, Bondagji N. Histopathological patterns of testicular biopsy in male infertility: A retrospective study from a tertiary care center in the western part of Saudi Arabia. *Urol Ann* 2011;3(1):19-23
17. Al-Rayess MM, Al-Rikabi AC. Morphologic patterns of male infertility in Saudi patients. A University Hospital experience. *Saudi Med J* 2000;21:625-8.
18. Al-Samawi AS, Al-Malas NA, Jibrel SO. Histologic pictures of male infertility in Yemeni patients. *Saudi Med J* 2009;30(5):652-5
19. Thomas JO, Jamal A. Primary testicular causes of infertility. Do environmental and socio-cultural factors have a role? *Trop Geogr Med* 1995;47:203-5.
20. Jamali M, Haeri H. Histopathologic findings in 848 testicular biopsies of infertile males. *Acta Med Iran* 1999;37:176-8.
21. Greenhall E, Vessey M. The prevalence of subfertility: A review of the current confusion and a report of two new studies. *Obstet Gynecol Surv* 1991;46:3978.
22. Jamal A, Mansoor I. Morphological profile of testicular biopsies associated with infertility. *Saudi Med J* 2001;22:992-4.
23. McLachlan RI, Rajpert-De Meyts E, Hoesli-Hansen CE, de Kretser DM, Skakkebaek NE. Histological evaluation of the human testis-approaches to optimizing the clinical value of the assessment: Mini review. *Hum Reprod* 2007;22:2-16.
24. Anne M. Jeouier, S.C. Holmes. Primary testicular diseases presenting as azoospermia or oligospermia in an infertility clinic. *British Journal of Urology* 1993;71:731-735.
25. Albasri AM, Hussainy AS. Histopathological pattern of testicular diseases in western Saudi Arabia. *Saudi Med J* 2018;39(5):476-480

**How to cite this article:** Sayed MA, Mathur A, Joshi N, Juyal D, Thakur A. Histopathological Patterns of the Testicular Biopsies and its Role in the Evaluation of Infertility Among Azoospermic Male Patients: A Hospital Based Study From Northern India. *Ann. Int. Med. Den. Res.* 2019; 5(4):PT11-PT16.

**Source of Support:** Nil, **Conflict of Interest:** None declared