

# A Clinico- Pathological Study of Lesions of Gastrointestinal Tract

Nimisha Gupta<sup>1</sup>, Deepak Mittal<sup>2</sup>, Farhana<sup>1</sup>

<sup>1</sup>Assistant Professor, Department of Pathology, FH Medical College Agra.

<sup>2</sup>Associate Professor, Department of Pathology, FH Medical College Agra.

Received: August 2019

Accepted: August 2019

**Copyright:** © the author(s), publisher. It is an open-access article distributed under the terms of the Creative Commons Attribution Non-Commercial License, which permits unrestricted non-commercial use, distribution, and reproduction in any medium, provided the original work is properly cited.

## ABSTRACT

**Background:** The disorders of gastrointestinal tract are responsible for a great deal of morbidity and mortality. The present study was conducted to determine lesions of gastrointestinal tract. **Methods:** This present study was conducted on 62 specimens of GIT tract. Biopsies from the gastrointestinal sites such as esophagus, pharynx, stomach, duodenum, liver, small intestine, colon, rectum and anal canal were obtained. **Results:** Maximum specimens were obtained from age group 21-30 years (24), followed by 11-20 years (16), 31-40 years (10), 41-50 years (8) and >50 years (4). 50 lesions were non-neoplastic and 12 were neoplastic. Most common non-neoplastic lesions were seen in gall bladder followed by esophagus (10) and small intestine (5). In neoplastic lesions, most common organ involved was gall bladder (5) followed by esophagus (3). In non-neoplastic lesions, chronic inflammatory lesion of oesophagus was seen in 10, appendicular lesions in 3, gall bladder lesions in 26, colonic perforation in 4, crohn's disease of small intestine in 5 and peptic ulcers in 2. Neoplastic lesions were SCC of esophagus in 3, adenocarcinoma of small intestine in 1, adenocarcinoma of large intestine in 1, SCC of stomach in 2 and adeonma of gall bladder in 5 cases. **Conclusion:** Authors found that most commonly non-neoplastic lesions were seen involving gall bladder and in age group 21-30 years.

**Keywords:** Gastrointestinal tract, neoplastic lesions, Gall bladder.

## INTRODUCTION

The disorders of gastrointestinal tract are responsible for a great deal of morbidity and mortality and are one of the most commonly encountered problems in clinical practice.<sup>[1]</sup> Specimens obtained from gastric and duodenal mucosa, appendicectomies, cholecystectomies and colonoscopic biopsies, colectomies etc are read after histopathology. Endoscopy and colonoscopy guided biopsies are the preferred forms of investigation in the surgical department which provides critical information for diagnosis and hence treatment.<sup>[2]</sup>

Histopathological diagnosis is essential in cases of polypoid lesions, ulcerative lesions and in dubious lesions on endoscopy. Upper GI endoscopy in combination with biopsy plays an important role in the early diagnosis of GI neoplasms and provides an opportunity for a broad range of treatment options as well as potential for possible cure.<sup>[3]</sup>

Cancer is a major public health problem all over the world, accounting for almost one in every four

deaths. The definitive diagnosis of gastrointestinal lesions largely depends on the histopathological confirmation and is one of the bases for planning proper treatment regimen. Gastrointestinal (GI) cancers account for 20% of estimated new cancer cases and 15% of estimated death worldwide.<sup>[4]</sup>

The large intestine and Anal canal are sites for broad array of non-neoplastic and neoplastic diseases, which at times, can lead to serious complications. They can be sites for infections, vascular disorders, ulcers, various inflammatory conditions and neoplasms. Epithelial tumours are major cause of morbidity & mortality.<sup>[5]</sup> Colorectal cancer is the fourth ranking cancer worldwide, accounting for approximately 9% of all cancers. Adenocarcinomas are the commonest malignancies arising in the colorectal region, other being carcinoid, anal zone carcinoma & melanoma. Non neoplastic polyps are classified as hyperplastic, hamartomatous, juvenile & Peutz jehgers polyp, inflammatory & lymphoid polyp. Other benign conditions are adenoma, lipoma, neuroma, angioma, etc.<sup>[6]</sup> The present study was conducted to determine lesions of gastrointestinal tract.

## MATERIALS AND METHODS

This present study was conducted in the department of general pathology. It comprised of 62 specimens

### Name & Address of Corresponding Author

Dr. Deepak Mittal  
Associate Professor,  
Department of Pathology,  
FH Medical College  
Agra.

of digestive tract. Ethical clearance was taken from institutional ethical committee.

Information such as name, age, gender etc. was recorded in case history performa. Biopsies from the gastrointestinal sites such as esophagus, pharynx, stomach, duodenum, liver, small intestine, colon, rectum and anal canal were obtained. These biopsies are fixed in 10% buffered formalin and routinely processed and paraffin embedded sections are taken and stained with hematoxylin and eosin. Results were tabulated and subjected to statistical analysis. P value less than 0.05 was considered significant.

## RESULTS

**Table 1: Age wise distribution of patients**

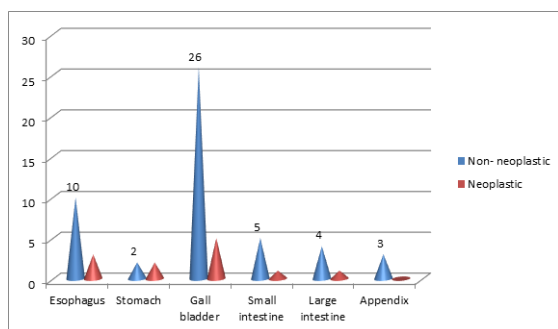
Age group (Years)	Number	P value
11-20	16	0.01
21-30	24	
31-40	10	
41-50	8	
>50	4	

[Table 1] shows that maximum specimens were obtained from age group 21-30 years (24), followed by 11-20 years (16), 31-40 years (10), 41-50 years (8) and >50 years (4). The difference was significant ( $P < 0.05$ ).

**Table 2: Distribution of lesions according to site**

Site	Non-neoplastic	Neoplastic	P value
Esophagus	10	3	0.01
Stomach	2	2	
Gall bladder	26	5	
Small intestine	5	1	
Large intestine	4	1	
Appendix	3	0	
Total	50	12	

[Table 2 & Figure 1] shows that 50 lesions were non- neoplastic and 12 were neoplastic. Most common non- neoplastic lesions were seen in gall bladder followed by esophagus (10) and small intestine (5). In neoplastic lesions, most common organ involved was gall bladder (5) followed by esophagus (3). The difference was significant ( $P < 0.05$ ).

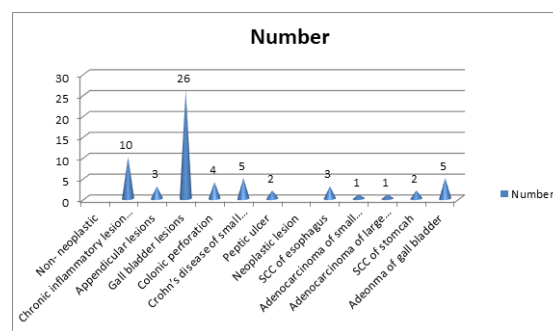


**Figure 1: Distribution of lesions according to site**

**Table 3: Histopathology of lesions**

Lesions	Number	P value
Non- neoplastic		0.01
Chronic inflammatory lesion of oesophagus	10	
Appendicular lesions	3	
Gall bladder lesions	26	
Colonic perforation	4	
Crohn's disease of small intestine	5	
Peptic ulcer	2	
Neoplastic lesion		
SCC of esophagus	3	
Adenocarcinoma of small intestine	1	
Adenocarcinoma of large intestine	1	
SCC of stomach	2	
Adeonma of gall bladder	5	

[Table 3 & Figure 2] shows that in non- neoplastic lesions, chronic inflammatory lesion of oesophagus was seen in 10, appendicular lesions in 3, gall bladder lesions in 26, colonic perforation in 4, crohn's disease of small intestine in 5 and peptic ulcers in 2. Neoplastic lesions were SCC of esophagus in 3, adenocarcinoma of small intestine in 1, adenocarcinoma of large intestine in 1, SCC of stomach in 2 and adeonma of gall bladder in 5 cases.



**Figure 2: Histopathology of lesions**

## DISCUSSION

Hirschsprung disease, enterocolitis & various ulcers like amoebic and inflammatory bowel disease (IBD), can cause septicaemia, perforation peritonitis & electrolyte imbalance. Inflammatory bowel diseases like Crohn's disease & Ulcerative colitis are premalignant conditions, hence their early diagnosis is necessary to avoid further consequences & for proper treatment.<sup>[7]</sup> Bowel infarction is a grave disorder that imposes 50-70% death rate. If not detected early patient may progress to shock & vascular collapse.<sup>[8]</sup> The present study was conducted to determine lesions of gastrointestinal tract.

In present study, maximum specimens were obtained from age group 21-30 years (24), followed by 11-20 years (16), 31-40 years (10), 41-50 years (8) and >50 years (4). Caliskan et al,<sup>[9]</sup> found that the upper GI endoscopic biopsies constituted 0.93% of all surgical

pathology specimens. Stomach was the most common biopsied site (55%), followed by esophagus (39%), and duodenum (6%). In esophagus, squamous cell carcinoma (82.60%) was more common as compared to adenocarcinoma (17.40%). Amongst gastric carcinoma, most common histological pattern noted was tubular adenocarcinoma (61.90%), followed by poorly cohesive carcinoma. All the duodenal biopsies showed chronic non-specific duodenitis. Overall, 91% concordance was noted between endoscopic and histopathological diagnosis.

We found that 50 lesions were non- neoplastic and 12 were neoplastic. Most common non- neoplastic lesions were seen in gall bladder followed by esophagus (10) and small intestine (5). In neoplastic lesions, most common organ involved was gall bladder (5) followed by esophagus (3). Shah et al,<sup>[10]</sup> found that out of 196 endoscopic biopsies studied, 129 were from male patients and 67 were from female patients. An age range of 19- 90 years was observed. There were 50 (25.5%) cases from esophagus, 15 (7.65%) cases from GE junction, 127 (64.8%) cases from stomach and 4 (2.04%) cases from duodenum. 45 (23%) cases were non - neoplastic, 52 (26.5%) cases were benign neoplasms while 99 (50.5%) were malignant neoplasms. Histopathology revealed gastritis (38 cases) (84.4%) as the most frequently diagnosed inflammatory lesion while adenocarcinoma stomach (45 cases) (45.9%) comprised the most frequently diagnosed malignant lesion.

We observed that in non- neoplastic lesions, chronic inflammatory lesion of oesophagus was seen in 10, appendicular lesions in 3, gall bladder lesions in 26, colonic perforation in 4, crohn's disease of small intestine in 5 and peptic ulcers in 2. Neoplastic lesions were SCC of esophagus in 3, adenocarcinoma of small intestine in 1, adenocarcinoma of large intestine in 1, SCC of stomach in 2 and adeonna of gall bladder in 5 cases. Vaidehi et al,<sup>[11]</sup> found that the most common specimen received was appendix (64.7%). The next common specimen was cholecystectomy specimens (24.4%). We had 74 large intestinal specimens (7.6%) and 25 small intestinal specimens (2.5%). The other specimens studied are 3 oesophageal biopsies (0.3%) and 3 gastric biopsies (0.3%).

Rashmi et al,<sup>[12]</sup> found that out of the 124 cases of large intestine 38 were non-neoplastic, 77 were neoplastic and 9 were inadequate biopsies. Sixty four cases from Anal canal included 55 non-neoplastic and 9 neoplastic lesions. The non-neoplastic conditions included congenital anomalies, infective and ischaemic lesions while neoplastic included benign and malignant lesions. Most of the cases presented with symptoms like abdominal pain, vomiting and constipation.

## CONCLUSION

Authors found that most commonly non- neoplastic lesions were seen involving gall bladder and in age group 21-30 years.

## REFERENCES

1. P, Quaglia A, Tavilla A, Shack L, Brenner H, Janssenheijnen M, Allemani C. et al Eurocare Working Group. The cancer survival gap between elderly and middle-aged patients in Europe is widening. *Eur J Cancer* 2009; 45: 1006-1016
2. Francisci S, Capocaccia R, Grande E, Santaquilani M, Simonetti A, Allemani C. et al. Eurocare Working Group. The cure of cancer: a European perspective. *Eur J Cancer* 2009; 45: 1067-1079
3. Chhanda Das, Namrata Maity, Madhumita Mukhopadhyay, Bedabrata Mukhopadhyay, Keya Basu, Madhukumari, A Histopathological Spectrum of Gastrointestinal Tract Lesions In A Tertiary Care Hospital: An Epidemiological Study For Four Years, *IOSR-JDMS* 2016; 15: 74-77.
4. Priavadhana Rajan Prasaad, Bheema Rao, Histopathological spectrum of gastrointestinal lesions - an experience in a tertiary care centre in South India. *Int J Res Med Sci.* 2016;4(8):3407-3412.
5. Dajani YF, Kamal MF. Colorectal juvenile polyps. An epidemiological and histopathological study of 144 cases in Jordanians. *Histopathology* 1984; 8(5):765-79.
6. Konishi F, Morson BC. Pathology of colorectal adenomas. A colonoscopic survey. *J Clin Pathol.* 1982;35(8): 830-41.
7. Tony J, Harish K, Ramachandran TM, Sunilkumar K, Thomas V. Profile of colonic polyps in a southern Indian population. *Indian J Gastroenterol.* 2007; 26(3):127-29.
8. Williams GT, Arthur JF, Bussey HJ, Morson BC. Metaplastic polyps and polyposis of the colorectum. *Histopathology.*1980;4(2):155-70.
9. Caliskan C, Guler N, Karaca C, Makay O, Firat O, Korkut MA. Negative prognostic factors in colorectal carcinoma: an analysis of 448 patients. *Indian J Surg.* 2010;72:243-48.
10. Shah A, Wani NA. A study of colorectal adenocarcinoma. *Indian J Gastroenterol.* 1991;10(1):12-3.
11. Vaidehi Patel, Meeta Parikh, Nikunj Suthar. Histopathological evaluation of gastrointestinal lesions- An experience in a tertiary care centre in west India. *Med Pulse International Journal of Pathology.* March 2018; 5(3): 89-93.
12. Rashmi K, Karar A, Mangala G. A study on histopathological spectrum of upper gastrointestinal tract endoscopic biopsies. *Int J Med Res Heal Sci.* 2013;2(3):418-24.

**How to cite this article:** Gupta N, Mittal D, Farhana. A Clinico- Pathological Study of Lesions of Gastrointestinal Tract. *Ann. Int. Med. Den. Res.* 2019; 5(5):PT12-PT14.

**Source of Support:** Nil, **Conflict of Interest:** None declared