

Histopathological Study of Lymph Node Biopsy at a Tertiary Care Center.

Harshita Vaibhaw¹, E. Girikumar², Dilip Hari Mandke³, Ravi Nandan Prasad Sinha⁴

¹Assistant Professor, Department of Pathology, Great Eastern Medical School & Hospital, Srikakulam, Andhra Pradesh.

²Professor & Head, Department of Pathology, Great Eastern Medical School & Hospital, Srikakulam, Andhra Pradesh.

³Professor, Department of Pathology, Great Eastern Medical School & Hospital, Srikakulam, Andhra Pradesh.

⁴Professor, Department of Pathology, Darbhanga Medical College, Darbhanga, Bihar.

Received: January 2019

Accepted: February 2019

Copyright: © the author(s), publisher. It is an open-access article distributed under the terms of the Creative Commons Attribution Non-Commercial License, which permits unrestricted non-commercial use, distribution, and reproduction in any medium, provided the original work is properly cited.

ABSTRACT

Background: Lymphadenopathy is a common symptom seen in outpatient department. Knowledge about spectrum of illnesses is helpful for the clinician. **Methods:** The present cross-sectional study was conducted upon 96 patients. History of patients including age, clinical features, provisional diagnosis and findings of histopathology were noted. **Results:** The most common age group was 40-49 years (22.9%). 62.5% were males and 37.5% were females Cervical lymph nodes were most commonly involved. 49% specimen showed tubercular changes, 29.2% chronic nonspecific lymphadenitis, 7.3% Hodgkin's lymphoma, 6.3% Non-Hodgkin's lymphoma and 9.4% metastatic lesions. **Conclusion:** that lymph node biopsy is useful in arriving at accurate diagnosis.

Keywords: Biopsy, Histopathology, Lymph nodes.

INTRODUCTION

Lymphadenopathy is the condition in which lymph nodes are abnormal in size, consistency or number, caused by the invasion or propagation of either inflammatory cells or neoplastic cells into the nodes.^[1] It is a common symptom seen in outpatient department of any hospital. It can be peripheral or visceral. Peripheral lymphadenopathies are easily detectable by palpation and are often biopsied.^[2] Clinical examination, laboratory investigations and imaging help in diagnosis. Lymph node biopsy is a gold standard method.^[3]

Causes of lymph node enlargement are different in different age groups. Knowledge about spectrum of illnesses is helpful for the clinician to make provisional diagnosis. Hence, this study was conducted.

Aims & objectives

The present study was conducted to identify the histopathological spectrum of lymphadenopathies in a tertiary care hospital.

Name & Address of Corresponding Author

Dr. Harshita Vaibhaw,
Assistant Professor,
Department of Pathology,
Great Eastern Medical School & Hospital,
Aditya Educational Society,
Ragolu Village,
Srikakulam,
Andhra Pradesh, PIN-532484

MATERIALS AND METHODS

The present cross-sectional study was conducted at a medical college hospital. All the excised lymph node specimens received in the department were included in the present study. Badly handled and poorly preserved lymph node specimens were excluded were excluded. A total of 96 patients were included in the present study.

History of patients was noted including age, clinical features and provisional diagnosis. The received specimens were examined for size, appearance, matting and consistency. It was fixed in 10% formalin and routine hematoxyline-eosin stained sections were examined. Diagnosis was made on the basis of morphology.

Data was recorded in pretested proforma, entered in Microsoft Excel and analyzed by SPSS v 16.0. Appropriate statistical tests were done. p-value of less than 0.05 was considered to be statistically significant.

RESULTS

Table 1: Age distribution

Age (in years)	Frequency (n=96)	%	95% CI
20-29	20	20.8	13.9-30
30-39	16	16.7	10.5-25.4
40-49	22	22.9	15.6-32.3
50-59	18	18.8	12.2-27.7
>59	19	19.8	13.1-28.9

A total of 96 patients were included in the present study. [Table 1] shows that the most common age group was 40-49 years (22.9%).

[Table 2] shows the sex distribution of study subjects. 62.5% were males and 37.5% were females.

Table 2: Sex distribution

Sex	Frequency (n=96)	%	95% CI
Male	60	62.5	52.5-71.5
Female	36	37.5	28.5-47.5

[Table 3] shows the findings of histopathological examination. It was seen that 49% specimen showed tubercular changes, 29.2% chronic nonspecific lymphadenitis, 7.3% Hodgkin's lymphoma, 6.3% Non-Hodgkin's lymphoma and 9.4% metastatic lesions.

Table 3: Findings of histopathological examination

Histopathology	Frequency (n=96)	%	95% CI
Tuberculous lymph node	47	49	39.2-58.8
Hodgkin Lymphoma	7	7.3	3.6-14.3
Non Hodgkin Lymphoma	6	6.3	2.9-13
Metastasis	9	9.4	5-16.9
Chronic nonspecific lymphadenitis	28	29.2	21-38.9

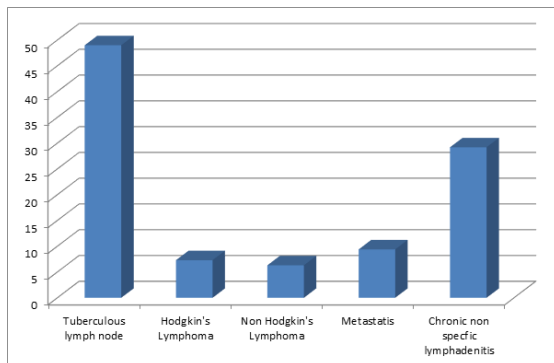


Figure 1: showing findings of histopathology

DISCUSSION

In the present study, the most common age group was 40-49 years (22.9%). 62.5% were males and 37.5% were females. Damle et al found that the age of patients ranged from 4 to 81 years with male to female ratio of 1:1.4.^[4] Rani et al found the male to female ratio of 1.2:1. The age of the patients ranged from 3 to 71 years with a mean age of 40-49 years.^[5] Gupta et al observed that the age range was 1-82 years with the mean age of 35years. Maximum numbers of cases were in the 3rd and 5th decade. Male to female ratio was 1.1:1.^[6]

Cervical lymph nodes were most commonly biopsied group of lymph nodes in the present study

similar to the findings of Vachhani et al, Rani et al and Gupta et al.^[5-7]

In the present study, 49% specimen showed tubercular changes, 29.2% chronic non specific lymphadenitis, 7.3% Hodgkin's lymphoma, 6.3% Non-Hodgkin's lymphoma and 9.4% metastatic lesions. Damle et al found that non-neoplastic lesions comprised of 80.1% cases and neoplastic lesions were present in 19.93% cases. Reactive lymphadenitis was the predominant non-neoplastic finding followed by granulomatous lymphadenitis. Neoplastic lesions were included 3.61% cases of lymphoma and 16.31% cases of metastatic lesions.^[4] Vachhani et al observed that 51% cases were of non specific reactive hyperplasia, 24% cases were granulomatous lymphadenitis, 2% cases were lymphoma and 23% cases were of metastatic lymph node. Most common type of metastasis was found out to be squamous cell carcinoma, followed by infiltrating ductal carcinoma and metastatic adenocarcinoma.^[7] Rani et al found that 31.9% cases were tuberculous lymphadenitis, 27.6% were malignant lymphoma while metastasis was found in 21.2% cases and reactive hyperplasia in 10.6% cases, suppurative lymphadenitis in 4.2% cases.^[5] Suba et al found that 85.4% were non-neoplastic lesions and 14.6% were neoplastic lesions. Tuberculosis was the most common condition in 42.7% followed by reactive hyperplasia in 39.8%. Of the cases of malignancy (14.6%), 9.7% were metastatic deposits and 4.9% were lymphomas.^[8] Krishnatreya et al found that 55 % were reactive hyperplasia, 43% were granulomatous lesions and Castleman's disease in 1 case. Tubercular lymphadenitis was the most frequent entity among granulomatous lesions. Of the malignant lesions, 55% were non-hodgkin's lymphoma 26% were hodgkin's lymphoma and 19% were metastatic.^[9] Gupta et al reported that 36.2% were tubercular lymphadenitis, 21.3% were metastatic tumours followed by 17.1% of Non-Hodgkin Lymphoma (NHL) and 12.7% each of Hodgkin lymphoma & chronic non specific lymphadenitis.^[6]

Lymph node biopsy remains a useful diagnostic tool to assess the architecture of the gland and gives an accurate diagnosis with minimal risk to the patient.

CONCLUSION

It is concluded from the present study that lymph node biopsy is useful in arriving at accurate diagnosis. It is less expensive than other tests when investigating the cause of enlarged lymph nodes.

REFERENCES

1. Rosai J. Lymph nodes. In: Rosai and Ackerman's Surgical Pathology. 9th edn. St. Louis: Elsevier Mosby, 2004: 1878-1888.

2. Ferrer R. Lymphadenopathy: differential diagnosis and evaluation. *Am Fam Physician* 1998; 58(6): 1313-1320.
3. Moore SW, Schneider JW, Schaaf HS. Diagnostic aspects of cervical lymphadenopathy in children in the developing world: A study of 1877 surgical specimens. *Pediatr Surg Int* 2003;19:240-4.
4. Damle RP, Suryawanshi KH, Dravid NV, Newadkar DV, Deore PN. A Descriptive Study of Histopathological Patterns of Lymph Node Biopsies In A Tertiary Care Hospital. *Annals of Pathology and Laboratory Medicine* 2017; 04 (02):131-6.
5. Rani VP, Kumar NS, Ravinder T. Evaluation of pathologic lesions in superficial lymph node biopsies. *International Journal of Biomedical Research* 2016; 7(5): 289-294.
6. Gupta D, Thaker BD, Suri J. Pattern of lymphadenopathies in a tertiary care hospital in Jammu, India. *Global Journal for Research Analysis* 2017;6(7):9-11.
7. Vachhani A, Bhuva K, Jasani J, Patel D, Savjian N, Patel K et al. Histopathological study of lymph node biopsy. *International Journal of Biomedical And Advance Research* 2013; 04 (11): 790-5.
8. Suba G, Jayaprakash HT, Shradha A. Morphological spectrum of peripheral lymphadenopathy – A hospital based study. *Indian Journal of Pathology and Oncology* 2017;4(2):278-281.
9. Krishnatreya K, Borgohain M, Das JK. Pattern of histopathological diagnosis of lymph node biopsies at a tertiary care hospital in Northeast India. *Panacea Journal of Medical Sciences* 2017;7(3):112-116.

How to cite this article: Vaibhaw H, Girikumar E, Mandke DH, Sinha RNP. Histopathological Study of Lymph Node Biopsy at a Tertiary Care Center. *Ann. Int. Med. Den. Res.* 2019; 5(2):PT36-PT38.

Source of Support: Nil, **Conflict of Interest:** None declared