

# Outcome of Arthroscopic Repair of Soft Tissue Bankart Lesion in Recurrent Anterior Shoulder Dislocation: A Prospective Observational Study

John Mohd<sup>1</sup>, Manish Singh<sup>2</sup>, Zubair A. Lone<sup>3</sup>

<sup>1</sup>Senior Resident, Department of Orthopaedics, Government Medical College, Jammu, India.

<sup>2</sup>Lecturer, Department of Orthopaedics, Government Medical College, Jammu, India.

<sup>3</sup>Junior Resident, Department of Orthopaedics, Government Medical College, Jammu, India.

Received: June 2019

Accepted: June 2019

**Copyright:** © the author(s), publisher. It is an open-access article distributed under the terms of the Creative Commons Attribution Non-Commercial License, which permits unrestricted non-commercial use, distribution, and reproduction in any medium, provided the original work is properly cited.

## ABSTRACT

**Background:** Shoulder joint is the most commonly dislocated joint of our body, accounting for 50% of all dislocations. Recurrent dislocation of the shoulder tends to occur more frequently in younger patients, patients with hyperlaxity, bony defect in glenoid or humeral head and immediate return to the contact supports after dislocation. Previously, open surgical repair was considered as the gold standard. Recently, the arthroscopic repair of the Bankart's lesion has been widely used with good outcome. **Methods:** 20 patients with soft tissue Bankart lesion were managed with arthroscopic repair, in this prospective observational study with a minimum follow up of 6 months. Outcome was studied using Rowe scoring system. **Results:** In our study out of 20 patients, 16 patients (80%) had excellent outcome, 3 patients (15%) had good outcome, one patient (5%) had fair outcome and no patient had poor outcome. So overall 95% patients had excellent to good results. Mean Rowe score in our patients at final follow up postoperatively was 92.8. **Conclusion:** We conclude that arthroscopic repair of soft tissue Bankart lesion is an effective mode of treatment for recurrent shoulder dislocations of shoulder with anterior instability in view of the promising outcome and minimal soft tissue compromise.

## INTRODUCTION

Shoulder joint is the most commonly dislocated joint of our body, accounting for 50% of all dislocations.<sup>[1]</sup> The incidence in general population is around 2%.<sup>[1]</sup> Most of the shoulder dislocation occur as a result of trauma.<sup>[2]</sup> Recurrent dislocation of the shoulder tends to occur more frequently in younger patients, patients with hyperlaxity, bony defect in glenoid or humeral head and immediate return to the contact supports after dislocation. Most anterior shoulder dislocations are associated with tear in capsule and labrum, usually called as a capsule-labral injury. This was described initially by Bankart and has been referred as Bankart lesion. In about 85-90% of the patients, Bankart lesion may be present after the initial dislocation.<sup>[3]</sup> Anterior band of the inferior glenohumeral ligament and middle glenohumeral ligament, at the

anteroinferior portion of the glenoid rim is typically involved.<sup>[4]</sup> As a result of the lack of resistance anteriorly, the joint is predisposed to anterior translation and hence recurrent dislocation.

Multitude of options are available for repair of the Bankart lesion. Previously, open surgical repair was considered as the gold standard. Recently, the arthroscopic repair of the Bankart lesion has been widely used with good outcome.<sup>[5]</sup>

## MATERIALS AND METHODS

### Study Design

This prospective observational study, was conducted in the department of Orthopaedics, Government Medical College Jammu, Hospital from November 2017 to November 2018. This study included 28 patients with soft tissue Bankart lesion, managed with arthroscopic repair. Eight patients were lost to follow-up and were excluded from the study. Hence, the final number of patients included in our study was 20. (n = 20)

### Inclusion Criteria

1. Age  $\geq$ 20 years
2. Either sex

### Name & Address of Corresponding Author

Dr. Manish Singh  
Lecturer,  
Department of Orthopaedics,  
Government Medical College, J  
ammu, India.

3. Shoulder Instability Severity Score Index (SISS)  $\leq 6$

#### **Exclusion Criteria**

1. Instability associated with fractures around shoulder
2. Instability severity score index  $> 6$
3. Single episode of shoulder instability
4. Comorbid medical conditions contra-indicating surgery or anaesthesia.

The patients were assessed clinically to confirm instability and all the patients underwent MRI and CT scan to confirm the clinical findings. [Figure 2] shows an MRI cut showing soft tissue Bankart lesion. The patients were included after a proper informed consent. Due clearance for study was taken from the hospital ethical committee.

#### **Operative Technique**

Surgery was done under general anaesthesia. Examination under anaesthesia was performed to confirm and measure the extent of instability. The patient was placed on the operating table in the lateral decubitus position with adequate support and pressure areas of the body were protected. The area of surgical interest was prepared and draping was done so that there is wide exposure to the anterior, posterior, and superior aspects of the shoulder. The arm was placed in 45° abduction and 20° forward flexion using 5 kg of traction.

#### **Steps of surgery:**

##### **1. Marking and making of portals**

Bony landmarks were marked around the shoulder, and the potential portals on the skin were marked. The standard posterior portal was placed 2 cm inferior to the posterolateral edge of the acromion. Thorough examination of the shoulder was done through the posterior portal to identify the most appropriate sites for placement of the anterior portals and for any additional posterior portals that may be necessary.

##### **2. Diagnostic Arthroscopy**

Diagnostic arthroscopy was done using standard portals to confirm clinical and radiological findings.

##### **3. Glenoid and Soft Tissue Preparation**

An arthroscopic tissue liberator was used to elevate and free up the torn and scarred labrum from the anterior glenoid for mobilization and hence anatomical repair. The glenoid neck was abraded to stimulate healing. Visualizing through anterosuperior portal an elevator was used to free up the capsule down to the subscapularis muscle. Using a rasp, we freshen the soft tissue and the intended area of plication to incite some inflammation without damaging the tissue.

##### **4. Anchor Placement and Capsulolabral Plication**

While viewing from the posterior portal, the drill guide for the suture anchor was introduced through

the inferior cannula and was positioned onto the face of the glenoid as close to the 6 o'clock position as possible. A drill was used to create a pilot hole, and the anchor was then tapped into the glenoid. A suture retrieving grasper was used to grasp one limb of suture from the anchor and pulled out through the 5 mm cannula. A curved suture passer loaded with a no. 1 polydioxanone (PDS) suture was used to pierce the capsule and advanced under the capsule and labrum in one pass. The PDS was advanced out of the passer and into the joint, where it was grasped and pulled out of the 5 mm cannula. The suture passer was removed from the shoulder. A simple loop was then made with the PDS that was pulled out of the 5 mm cannula. This loop was loaded with the anchor suture and cinched down. The PDS limb that was in the 8 mm cannula was pulled, shuttling the suture limb through the tissue and out of the cannula.

##### **5. Knot Tying and Sequential Anchor Placement**

Knots were tied arthroscopically using low-profile sliding locking knots followed by half hitches. The knots were kept away from the glenoid face to prevent articular cartilage injury from the suture. Suture tails were cut with the arthroscopic cutters. Subsequent anchors were placed in similar fashion, working superiorly on the glenoid. A minimum of 3 to 4 anchors were used depending on the size of the patient.

##### **6. Skin Closure and Shoulder immobilization**

Nonabsorbable sutures were used to close the skin. Sterile dressings were applied to the surgical incisions and a shoulder immobilizer applied. Intravenous antibiotics and analgesics were given for 3 days followed by oral antibiotics for 1 week. Dressings were changed on the 2<sup>nd</sup> post-operative day and the patient was discharged on oral antibiotics and analgesics. The intraoperative pictures are depicted in [Figure 1A-F].

#### **Postoperative Care**

A sling immobilizer was applied after surgery and worn for 4 to 6 weeks. Physical therapy was started 2 to 3 weeks after surgery. Active-assisted range of motion was performed from weeks 2 to 8, and isometric strengthening was performed from weeks 8 to 12. The athlete was allowed to return to preinjury conditioning programs and weight training at 12 weeks, and at 6 months was allowed to participate in contact sports.

#### **Follow UP**

Follow-up was done at two weekly intervals till 3 months postoperatively, then thrice weekly thereafter, with final follow up at a minimum of 6 months. Stitches were removed at 2 weeks and physiotherapy started as per S Terry's rehabilitation protocol.<sup>[6]</sup> At each visit shoulder motion was checked. Range of motion around the shoulder was assessed at 3 months and 6 months. Functional

evaluation was done using Rowe's scoring system which was done pre-operatively and compared with the post-operative outcome at 3 months and 6 months follow-up.<sup>[7]</sup>

## RESULTS

**Table 1: Table showing age distribution**

S.No.	Age (in Years)	No. of Cases	Percentage
1	20-25	6	30 %
2	26-30	7	35%
3	31-35	3	15%
4	36-40	2	10%
5	41-45	2	10%
	Total	20	100%

**Table 2: Table showing side involvement**

S.No.	Side Involved	No. of Cases	Percentage
1	Right	16	80%
2	Left	4	20%
	Total	20	100%

**Table 3: Table showing mechanism of injury in patients**

S.No.	Mode of Injury	No. of Patients	Percentage
1	Fall on affected shoulder	7	35%
2	RTA	4	20%
3	Overhead Throwing activity	3	15%
4	Lifting of Heavy Weight	2	10%
5	Fall on Outstretched limb	1	5%
6	Mild Trauma and others	3	15%
	Total	20	100%

**Table 4: Table showing pre-operative Rowe score**

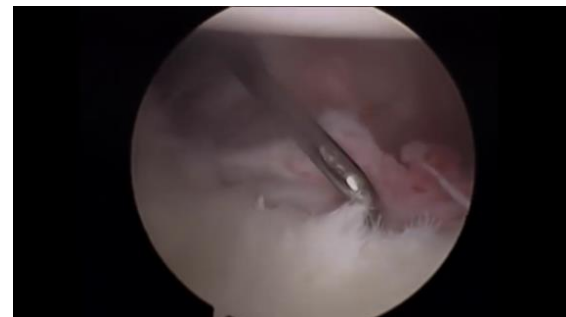S.No.	Rowe Score	Description	No. of Patients	Percentage
1	≥ 90	Excellent	0	0%
2	75-89	Good	0	0%
3	51-74	Fair	0	0%
4	≤ 50	Poor	20	100%
	Total		20	100%

**Table 5: Table showing post-operative Rowe score and outcome**

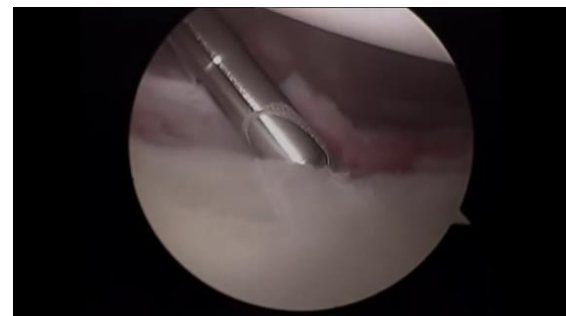S.No.	Rowe Score	Description	No. of Patients	Percentage
1	≥ 90	Excellent	16	80
2	75-89	Good	3	15
3	51-74	Fair	1	5
4	≤ 50	Poor	0	0
	Total		20	100

The mean age in our series was 29.4 years. Age distribution is depicted in [Table 1]. 65% of our patients were in age group of 20- 30 years. Male to female ratio in our study was 5.66:1. Males predominated our study with 85% patients being males. [Figure 3] Right side involvement was more common than Left in our study with right side involvement in 80% of patients. Right to Left side involvement ratio was 4:1. [Table 2] Dominant side was involved in majority of our patients with

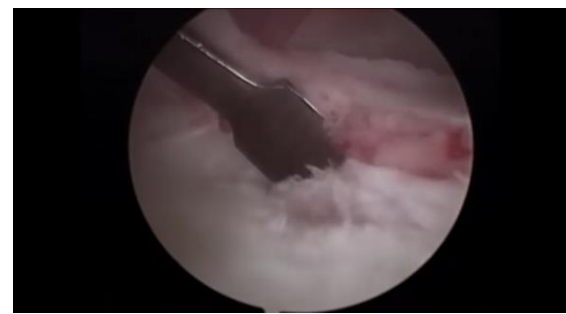dominant versus non-dominant ratio of 4:1. Direct trauma to shoulder caused by fall on affected shoulder or RTA accounted for 55% of cases and indirect trauma like fall on outstretched limb or lifting of heavy weight or overhead throwing activity accounted for 30% of cases. [Table 3] depicts mechanism of injury in our patients. Mild trauma accounted for 15% of cases. So, major traumatic event was a cause in majority of cases. Mean age at primary dislocation in our patients was 26.2 Years. Mean interval from primary dislocation to recurrence was 11.3 months. Mean time interval since first dislocation to surgery was 3.2 years. Majority of the patients were operated between 1-6 years since first dislocation. 70% of the patients had 2-5 dislocations before surgery. Average number of dislocations before surgery was 4.7. 60% of the patients had a history of trauma, other than athletic activity. Mean shoulder injury severity score in our patients was 3.9. Mean stability score in our patients preoperatively was 0. Mean preoperative Motion score in our patients was 18.8. Mean preoperative Function score in our patients was 20.3. Mean preoperative Total Rowe Score in our patients was 39. [Table 4]



**Figure 1A: Intra-operative arthroscopic images**



**Figure 1B: Intra-operative arthroscopic images**



**Figure 1C: Intra-operative arthroscopic images**

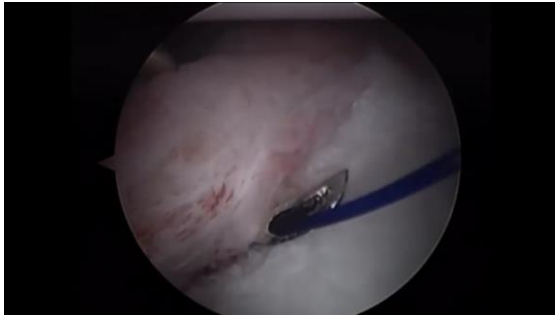


Figure 1D: Intra-operative arthroscopic images

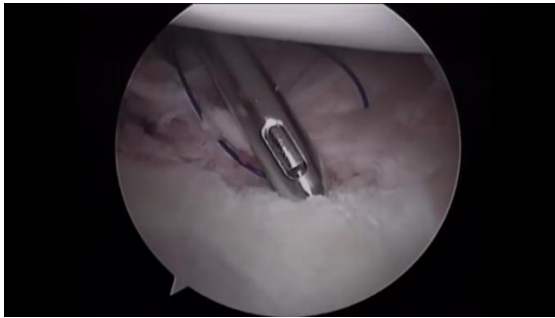


Figure 1E: Intra-operative arthroscopic images

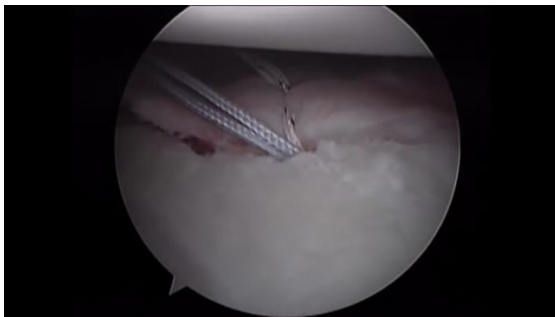


Figure 1F: Intra-operative arthroscopic images

During diagnostic arthroscopy, soft tissue Bankart and Hill Sachs lesions were most commonly encountered, usually in combination. Multiple lesions were found in a single patient, on most instances. Glenoid bone loss was seen in 4 patients and in all the four patients it was < 20%. Average duration of surgery in our patients was 87.0 minutes. Mean hospital stay in our patients was 2.4 days.

Mean abduction at 3 months postoperatively was 126.5°. Mean Forward flexion at 3 months postoperatively was 125.9°. Mean External rotation at 3 months postoperatively was 25.6°. Mean Internal rotation at 3 months postoperatively was 31.38°. Mean stability score at 3 months postoperatively in our patients was 50. Mean motion score at 3 months postoperatively in our patients was 12.5. Mean function score at 3 months postoperatively in our patients was 15.3°. Mean Rowe score in our patients at 3 months postoperatively was 77.3. Figure 4 depicts comparison of pre-operative and post-operative Rowe score. In our study, 16 patients (80%) had excellent outcome, 3 patients (15%) had good

outcome, one patient (5%) had fair outcome and no patient had poor outcome. [Table 5]

Mean abduction at final follow up postoperatively was 165°. Mean Forward flexion at Final Follow Up postoperatively was 161.3°. Mean External rotation (in abduction) at final follow up postoperatively was 78.5°. Mean External rotation (in Neutral) at final follow up postoperatively was 52.3°. Mean Internal rotation at final follow up postoperatively was 60.3°. Mean stability score at final follow up postoperatively in our patients was 50. Mean motion score at final follow up postoperatively in our patients was 17.5. Mean function score at final follow up postoperatively in our patients was 25.5. Mean Rowe score in our patients at final follow up postoperatively was 92.8. Mean duration of follow up in our patients was 8.6 months.

In our study, we encountered three complications, one patient had superficial wound infection, one had stiffness, and one had axillary neuropraxia. There was not a single case of re-dislocation after surgery.

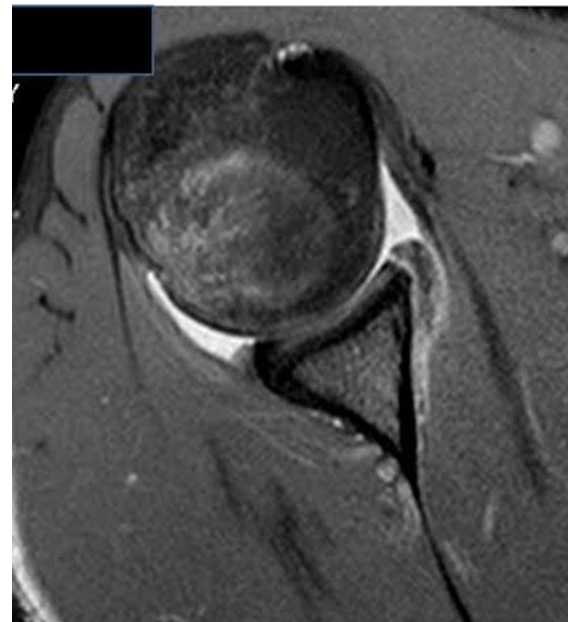


Figure 2: MRI cut showing soft tissue Bankart lesion

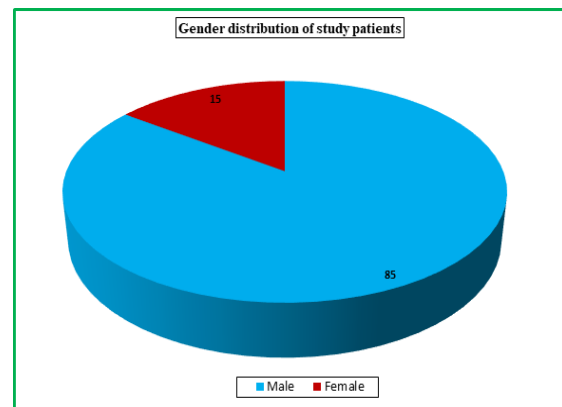


Figure 3: Pie diagram showing gender distribution



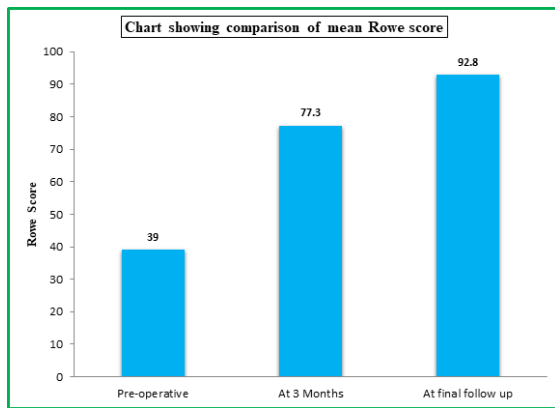


Figure 4: Bar chart showing comparison of mean Rowe score

## DISCUSSION

The age group involved in our patients ranged from 20-45 years with a mean of 29.4 years. Majority of our patients (65%) belonged to age group of 20-30 years with 30% of patients belonging to age group of 20-25 years. Youngest patient in our series was 21 years old. Milchteim C et al observed a mean age in their series of 21.9 years, with a range of 15-43 years.<sup>[8]</sup> Szyluk K et al observed a mean age of 25.6 years with a range of 19-40 years.<sup>[9]</sup> Castagna A et al observed a mean age of 26.3 years with a range of 17-46 years.<sup>[10]</sup>

Male to female ratio in our study was 5.56:1 with 85% patients being males. Milchteim C et al evaluated results of arthroscopic Bankart repair in 94 patients with anterior shoulder dislocation. Male to female ratio observed by Milchteim C et al in their series was 43.5:1.<sup>[8]</sup> Szyluk K et al in their study group comprised of 18 (19.6%) women and 74 (80.4%) men.<sup>[9]</sup> The study by Castagna A et al comprised of 26 men and 4 women.<sup>[10]</sup>

Right side was involved in 16 (80%) patients. In 18 patients (90%) right side was dominant. In a study by Szyluk K et al, a total of 84 (91.3%) patients were right-handed and 8 patients (8.7%) were left-handed.<sup>[9]</sup> The dominant arm was involved in 21 cases (67.7%) in a study by Castagna A et al.<sup>[10]</sup>

In our series majority of patients (90%) sustained significant trauma at the time of primary dislocation and 10% patients sustained trivial trauma at the time of primary dislocation. In a study by Szyluk K et al all patients had sustained their initial dislocation as a result of an injury. In 60.8% cases, these were sports injuries, and in 39.2%, the causes were various types of high-energy injuries.<sup>[9]</sup>

In our study, mean age at primary dislocation was 26.2 years. Szyluk K et al observed a mean age of 22.5 years with a range of 15-37 years on the day of initial dislocation.<sup>[9]</sup> In our series the mean number of dislocations prior to surgical intervention was 4.7. In the study by Castagna A et al, the mean number of recurrences between the first injury and surgery was 5 episodes.<sup>[10]</sup>

In our study out of 20 patients, 16 patients (80%) had excellent outcome, 3 patients (15%) had good outcome, one patient (5%) had fair outcome and no patient had poor outcome. So overall 95% patients had excellent to good results. Mean Rowe score in our patients at final follow up postoperatively was 92.8. Milchteim C et al observed a mean Rowe score of 84.3 with 82% good and excellent scores.<sup>[8]</sup> Szyluk K et al obtained excellent to good results in 94.1% patients.<sup>[9]</sup> At final follow-up, Castagna A et al had 58% excellent results, 19.3% good results, 3.3% fair and 19.4% poor outcomes.<sup>[10]</sup> The average Rowe score at final follow up, observed by Westerheide KJ et al in their study was 85.<sup>[11]</sup> Marquardt B et al, in their study achieved excellent results in 72.2%, good results in 11.1%, fair results in 5.6% and poor results in 11.1% patients.<sup>[12]</sup>

Hence, the results achieved in our study are comparable to the previous studies.

## CONCLUSION

We conclude that arthroscopic repair of soft tissue Bankart lesion is an effective mode of treatment for recurrent shoulder dislocations of shoulder with anterior instability in view of the promising outcome and minimal soft tissue compromise.

## REFERENCES

- Burkhart SS, Morgan CD, Kibler WB. The disabled throwing shoulder, spectrum of pathology part I: pathoanatomy and biomechanics. *Arthroscopy* 2003;19(4):404-20.
- Rowe CR. Prognosis in dislocations of the shoulder. *J Bone Joint Surg Am.* 1956;38:957-77.
- Matsen FA III, Chebli C, Lippitt S. Principles for the evaluation and Management of shoulder instability. *J Bone Joint Surg Am* 2006;88(3):647-659.
- Liu SH, Henry MH. Anterior shoulder instability. Current review. *Clinical orthopaedics and related research.* 1996;323:327-378
- Angst F, Schwyzer HK, Aeschlimann A, Simmen BR, Goldhahn J. Measures of adult shoulder function: Disabilities of the Arm, Shoulder, and Hand Questionnaire (DASH) and its short version (QuickDASH), Shoulder Pain and Disability Index (SPADI), American Shoulder and Elbow Surgeons (ASES) Society standardized shoulder assessment form, Constant (Murley) Score (CS), Simple Shoulder Test (SST), Oxford Shoulder Score (OSS), Shoulder Disability Questionnaire (SDQ), and Western Ontario Shoulder Instability Index (WOSI). *Arthritis Care Res (Hoboken).* 2011;63(Suppl-11):S174-88.
- S Terry Canale, James H Beaty: *Campbell's Operative Orthopaedics.* 12th edition. Philadelphia Mosby. 2013;2:2467-2534.
- Rowe C, Patel D, Southmayd W. The Bankart procedure: a long-term end result Study. *J Bone Joint Surg Am.* 1978; 60:1-16.
- Milchteim C, Tucker SA, Nye DD, Lamour RJ, Liu W, Andrews JR, et al. Outcomes of Bankart repairs using modern arthroscopic technique in an athletic population. *Arthroscopy.* 2016;32:1263-1270.

9. Szyluk K, Jasiński A, Widuchowski W, Mielnik M, Koczy B. Results of Arthroscopic Bankart Lesion Repair in Patients with Post-Traumatic Anterior Instability of the Shoulder and a Non-Engaging Hill-Sachs Lesion with a Suture Anchor after a Minimum of 6-Year Follow-Up. *Medical Science Monitor : International Medical Journal of Experimental and Clinical Research*. 2015;21:2331-2338.
10. Castagna A, Markopoulos N, Conti M, Rose GD, Papadakou E, Garofalo R. Arthroscopic Bankart suture-anchor repair: radiological and clinical outcome at minimum 10 years of follow-up. *Am J Sports Med*. 2010;38(10):2012–6.
11. Westerheide KJ, Dopirak RM, Snyder SJ. Arthroscopic anterior stabilization and posterior capsular plication for anterior glenohumeral instability: A report of 71 cases. *Arthroscopy*. 2006;22:539-54
12. Marquardt B, Witt KA, Goetz C, Liem D, Steinbeck J, Pötzl W. Longterm results of arthroscopic Bankart repair with a bioabsorbable tack. *Am J Sports Med*. 2006;34:1906-1910.

**How to cite this article:** Mohd J, Singh M, Lone ZA. Outcome of Arthroscopic Repair of Soft Tissue Bankart Lesion in Recurrent Anterior Shoulder Dislocation: A Prospective Observational Study. *Ann. Int. Med. Den. Res*. 2019; 5(4):OR42-OR47.

**Source of Support:** Nil, **Conflict of Interest:** None declared