

Functional Outcome of Intra-Articular Proximal Tibia Fractures (41C) Treated with Dual Plate Osteosynthesis.

Sudipta Dasgupta¹, Samiran Dey², Anup Barman², SK Moinuddin², Pranay Chatterjee², Nazir Hasan²

¹Associate Professor, Department of Orthopaedics, Burdwan Medical College, West Bengal, India

²Junior Resident, Department Of Orthopaedics, Burdwan Medical College, West Bengal, India.

Received: May 2019

Accepted: May 2019

Copyright: © the author(s), publisher. It is an open-access article distributed under the terms of the Creative Commons Attribution Non-Commercial License, which permits unrestricted non-commercial use, distribution, and reproduction in any medium, provided the original work is properly cited.

ABSTRACT

Background: The fractures of proximal tibia particularly plateau fractures are more difficult to treat due to complexity of configuration and associated soft tissue injuries. AO 41C fractures are high energy fractures often accompanied by other injuries and complications, such as postoperative inflammation, wound problems and infections. Aim and objectives: functional outcome of intra-articular proximal tibia fractures (41C) treated with dual plate osteosynthesis. **Methods:** The study will be conducted over a period of 19 months in department of Orthopaedics, BMCH. All cases attending OPD and emergency >18 years of age with intra articular fracture proximal tibia (41C) will be assessed by clinically and radiologically. Clinically assessment will be done by Rasmussen's score treated with open reduction internal fixation with dual plate osteosynthesis of intra-articular proximal tibia fractures, and those followed up at 2,6,10,14,20,24 weeks for any complications and morbidity. **Results:** The mean age among patients was 31.38±11.37 years. The male: female ratio was 2.33. Among 10 patients; 2 had Diabetes Mellitus while 1 had hypertension. Mean duration of surgery from time of injury was 7.89 ±3.98 days. Mean hospital stay in patients was 18.16 ±3.69 days. Mean time for union in patients was 12.18±4.83 weeks. Radiographic results Rasmussen anatomic outcome (immediately postoperatively) was excellent in 6, good in 3, and fair in 1 patients. **Conclusion:** Dual plate osteosynthesis is the best, effective and simple procedure in treatment of complex intra-articular proximal tibia fractures (41C).

Keywords: Intra articular proximal tibia fractures (41C), Dual plate osteosynthesis.

INTRODUCTION

The knee joint is complex joint and is the commonly injured joint now a day because of increased vehicular trauma and sports related injuries. Being superficial joint and more exposed to external forces, this joint easily gets injured. Complex kinematics of its weight bearing position and complex ligamentous stability and articular congruency are the main reason why these fractures are concern to surgeon and cause disability to the patients. The fractures of proximal tibia particularly those that extended into the knee joint are termed as tibial plateau fractures.

The aim of surgical treatment of proximal tibial fractures is to restore and preserve normal knee function, which can be accomplished by anatomical

restoration of articular surfaces, maintaining mechanical axis, restoring ligamentous stability and preserving a functional pain free range of motion of knee.

In this present study we hereby study the functional outcome of intra-articular proximal tibial fractures (41C) treated with dual plating.

MATERIALS AND METHODS

The study has been conducted after obtaining clearance from institutional ethical committee with informed consent from participating patients.

Study Area

Burdwan Medical College & Hospital in department of orthopaedics and radiodiagnosis.

Study Population

Patients attending OPD and emergency in the age of >18 years with intra-articular fracture proximal tibia.

Inclusion criteria:

Name & Address of Corresponding Author

Dr. Anup Barman,
Junior Resident,
Department Of Orthopaedics, Burdwan Medical
College, West Bengal, India.

1. All patients with type 41C tibial plateau fractures as per Orthopaedic Trauma Association classification.
2. Closed Fractures.

Exclusion criteria:

- a) Polytrauma patients
- b) Head injury patients
- c) Fractures with vascular injury.
- d) Fractures with compartment syndrome.
- e) Fractures with severe soft tissue injury.
- f) Fracture in ipsilateral lower limb
- g) Medically unfit patient.

Study Period: June 2017-January 2019[19 months]

Sample Size: 10 patients

Sample Design: Selective sampling of cases meeting the inclusion criteria.

Study Design: It was a prospective study. The patients were examined thoroughly with emphasis on radiological, functional, socioeconomic status. Operative intervention was done on due course and post op follow up done at 2,6,10,14,20,24 weeks for any complications and morbidity. Pre and post operative radiological and functional outcome was compared.

Parameters Studied

- A) **Clinical Parameters:** Determined by score. Limb evaluation for extent of soft tissue damage, wounds and distal neurovascular status, skin condition.
- B) **Radiological Parameters**
 - AP, lateral and oblique views of knee joint ,
 - CT scan with 3D reconstruction.

Study technique:

Pre-operative regimen:

- a) Evaluation of the patient- Patients were evaluated according to the ATLS protocol.
- b) Evaluation of the limb-Limb evaluation for extent of soft tissue damage, wounds and distal neurovascular status, skin condition. Primary fracture stabilization was done with above knee slab and limb elevation.
- c) Radiological assessment: AP, lateral and oblique views of knee joint, CT scan with 3D reconstruction

Surgical Technique Used

- 1. Antero-lateral approach
- 2. Postero-medial approach

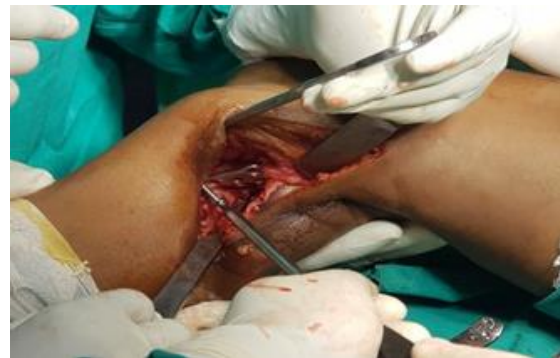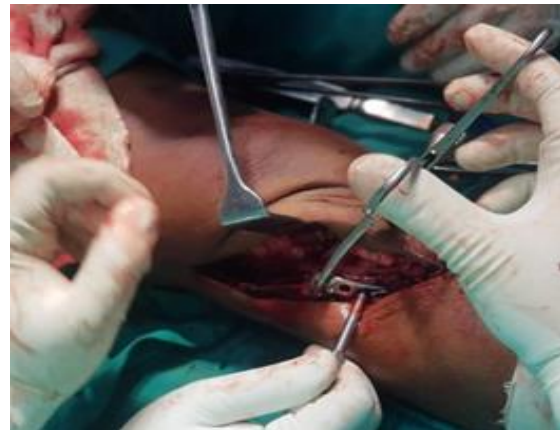Antero-Lateral Approach: Straight or slightly curvilinear anterolateral incision, starting 3 to 5 cm above the joint line proximally and extending distally below the inferior margin of the fracture site from just anterior to the lateral femoral epicondyle to Gerdy's tubercle.

Fascial incision parallel to the anterior border of the iliotibial tract is made. Underlying muscle is retracted laterally. The fragments are elevated and

reduced, followed by temporary fixation with multiple small Kirschner wires in reduction position. Hockey stick-shaped lateraltibial locking buttress plate for definitive fixation is then applied. Cortical screws (4.5-mm) are used to attach the plate to the shaft of the tibia.

Posteromedial approach: Skin incision is given just posterior and parallel to the posteromedial tibial border. Skin and subcutaneous tissue is sharply divided and mobilize the inferior border of pes anserinus tendon ,interval created with the medial head of the gastrocnemius. Reduction and internal fixation using a 3.5mm small fragment plate centered over the apex of the distal fracture extension.

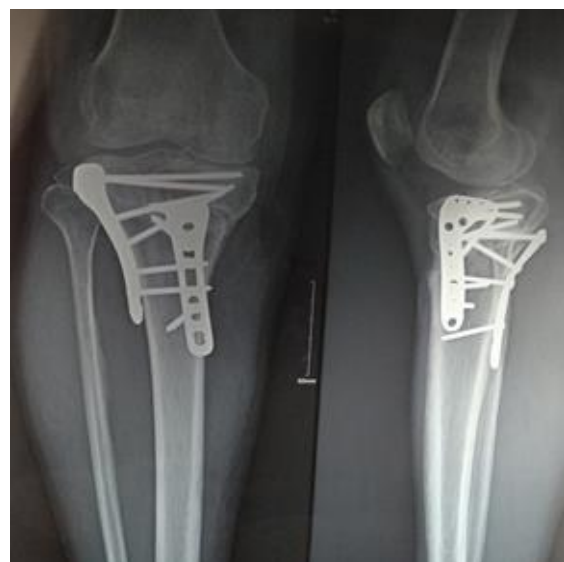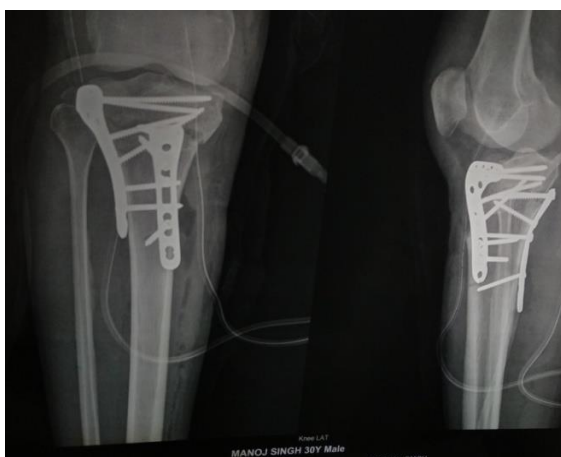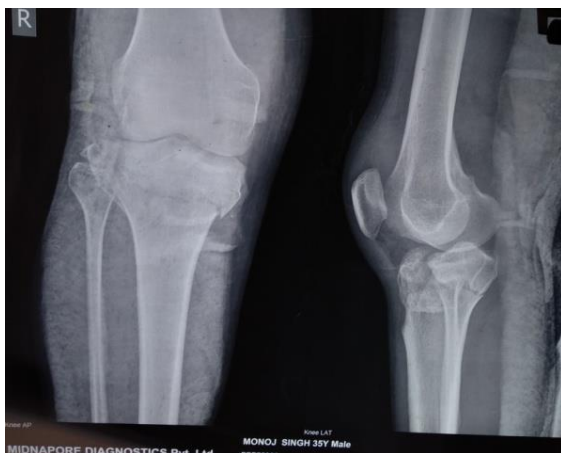
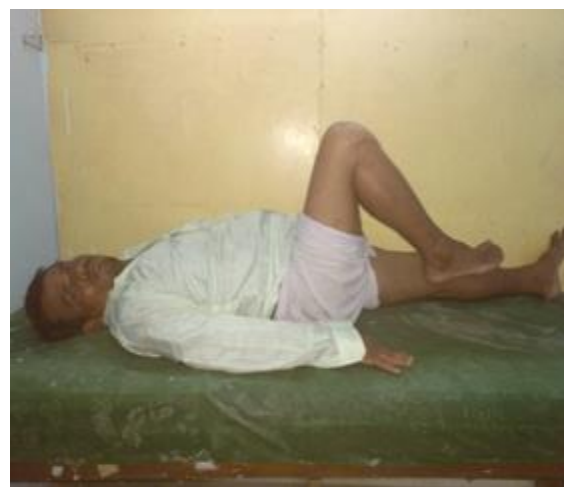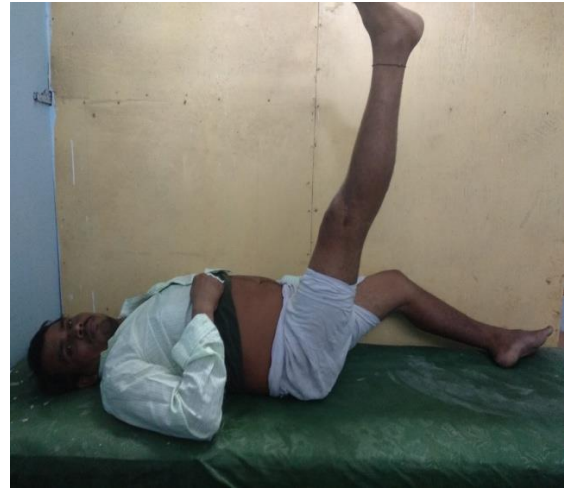Post-operative regimen: The knee is placed into a removable knee immobilizer. At 1 to 2 days postoperatively, physical therapy is initiated with quadriceps exercises and gentle active -assisted exercises are begun, or a passive motion machine can be used. Crutch walking is begun, but no weight bearing is permitted for 10-12 weeks.



RESULTS

Ten patients met the criterion in this study. All fractures in this study were classified according to the AO classifications. Based on the AO classification, there were 6 type C1 fracture, 3 type C2, and 1 type C3 fractures). It was observed that majority of patients were from age group 25-55. The mean age among patients was 31.38 ±11.37 years. . The male: female ratio was 2.33. Among 10

patients 7 (70%) had history of high velocity trauma. Of all 6(60%) had right sided fracture while 4(40%) had left sided fracture. It was observed that among 10 patients; 2 had Diabetes Mellitus while 1 had hypertension. Distribution of patients according to Comorbidity It was observed that among 10 patients; 6had no associated injuries while 4 had associated injuries. Mean duration of surgery from time of injury was 7.89 ± 3.98 days. .. Mean operating time was 108 ± 09 min (range, 90–140 min). Mean hospital stay in patients was 18.16 ± 3.69 days (range, 15–25 days). Mean time for union in patients was 12.18 ± 4.83 weeks. Complete follow-up was performed in 10 patients. Mean follow-up duration was 16 ± 2.2 months (range, 14–18 months). At final follow-up, two patients displayed loss of reduction loss but no loss of alignment. Clinical functional results were evaluated in 10 patients. Overall, clinical functional evaluation was satisfactory. Mean knee flexion at the end of treatment was 115 degrees; only one patients achieved flexion of less than 90 degrees. No patient had a fixed flexion deformity. Mean Rasmussen clinical score was 26.14 ± 3.80 (range, 10–29). Rasmussen functional outcome was excellent in 6, good in 3, and fair in 1 patient.. Overall rates of excellent and good outcomes were 95.5%, 86.2% and 55.6% for types C1, C2, and C3 fractures, respectively.



DISCUSSION

Compared with other fixation methods, dual buttress plates provide more stability and more convenient reduction. At a mean follow-up of 19 months, the overall outcomes were favourable, with no serious soft tissue complications and nonunion.

Rasmussen clinical score showed excellent and good outcomes in most patients. Two incisions and two plates method reduced soft tissue irritation, the infection rates in which ranged from 0 to 22.3% in recent literature. We believed that the selection of operation chance and limited soft tissue separation were the most important elements for preventing infection and tissue necrosis. We observed that postoperative wound exudation was appeared in that 2 patients. In this study, fracture healing and stability of limb alignment were satisfactory. In the present study two variables (AO fracture type and reduction quality), however, significantly influenced postoperative function and were found to be independent predictors of postoperative function. These results were not consistent with previous reports and may be attributable to differences in numbers of patients, types of fractures, durations of follow-up.]. The present study identified AO fracture type as an independent predictor of outcome. Difficulty reaching the anatomic diaphysis in 41 type C3 fractures, and unavoidable articular cartilage cataplasia resulting from high-energy trauma, may explain the influence of fracture type on outcome. This study has a number of limitations, including a relatively short follow-up period and a small number of cases. More complications may appear over a longer follow-up period. The limited number of cases may decrease statistical power as well as our ability to analyze the influences of infection, alignment, and other factors on function. Finally, serious open fractures (Gustilo grade III) were excluded, which may be related to the small number of complications in our study. In conclusion, dual buttress plates provided fracture reduction of reasonable quality and clinical function. Limited soft tissue stripping, appropriate selection for operation chance, and filling of osseous defects may lessen or prevent serious complications such as infection, wound skin necrosis, and loss of alignment. Fracture reduction quality and AO fracture type were independent predictors of clinical function. Anatomical reduction of fracture is still one of the treatment goals, and type of fracture, especially those resulting in serious damage to the cartilaginous surface, will affect joint function.

CONCLUSION

Dual plate osteosynthesis is the best , effective and simple procedure in treatment of complex intra-articular proximal tibia fractures (41C).

REFERENCES

1. Ricci, William,MD; et al. Treatment of complex proximal tibial fractures with LISS; Journal of orthopaedic trauma issue - : Vol 18(8) Sept 2004, D-521-527

2. Beck M, Gradl G, et al. Der Unfallchirurg [Unfallchirurg], ISSN: 0177-5537, 2008 Jul; Vol. 111 (7), pp. 493-8;
3. Kumar G, Peterson N, Narayan B. Bicondylartibial fractures: Internal or external fixation. Indian JOrthop. 2011;45(2): 116-124.
4. Zhang Y, Fan DG, Ma BA, Sun SG. Treatment of complicated tibial plateau fractures with dual plating via a 2-incision technique. Orthopedics 2012;35:e359-64.
5. Ebrahim Ghayem Hassankhani et al. Treatment of Complex Proximal Tibial Fractures (Types V & VI of Schatzker Classification) by Double Plate Fixation with Single Anterior Incision Open Journal of Orthopedics. doi:10.4236/ojo.2013.34038 Published Online August. 2013; 3:208-212.
6. G Thiruvengita Prasad et al. Functional outcome of Schatzker type V and VI tibial plateau fractures treated with dual plates, Indian J Orthop. Mar-Apr. Doi: 10.4103/0019-5413.108915. 2013; 47(2):188-194
7. Kye-Youl Cho et al. Treatment of Schatzker Type V and VI Tibial Plateau Fractures Using a Midline Longitudinal Incision and Dual Plating: Knee Surg Relat Res. 2013; 25(2):77-83. <http://dx.doi.org/10.5792/ksrr.2013.25.2.77>Pissn2234-0726eissn2234-2451
8. Khatri K, Lakhota D, Sharma V, Kiran Kumar GN, Sharma G, Farooque K. Functional Evaluation in High Energy (Schatzker Type V and Type VI) Tibial Plateau Fractures Treated by Open Reduction and Internal Fixation. International Scholarly Research Notices. 2014;2014:8.
9. Jaiswal A et al . Triple plating of tibia in a complex bicondylar tibial plateau fracture. Chin J Traumatol. 2014;17(3):183-6.
10. Neogi DS, Trikha V, Mishra KK, Bandekar SM, Yadav CS. Comparative study of single lateral locked plating versus double plating in type C bicondylar tibial plateau fractures. Indian J Orthop 2015;49:193-8
11. Kulkarni SG, Jain A, Shah PB, Negandi S, Kulkarni VS, Sawarkar A. A prospective study to evaluate functional outcome of staged management of complex bicondylar tibial plateau (Schatzker type V and VI) fractures treated using dual plates as internal fixation. Journal of Trauma and Orthopaedic Surgery. Jan-March 2017;12(1):16-22.
12. Watson T. T., Wiss D.A.: Fractures of proximal tibial add fibula: In Rockwood and Green's Vol2, 5th Edn, 1801- 1841, 2002.
13. Prasad GT, Kumar TS, Kumar RK, Murthy GK, Sundaram N. Functional outcome of Schatzker type V and VI tibial plateau fractures treated with dual plates. Indian J Orthop 2013;47:188-94 4. Cho KY, Oh HS, Yoo JH, Kim DH, Cho YJ, Kim KI.
14. Cho KY, Oh HS, Yoo JH, Kim DH, Cho YJ, Kim KI. Treatment of Schatzker Type V and VI Tibial Plateau Fractures Using a Midline Longitudinal Incision and Dual Plating. Knee Surg Relat Res 2013; 25(2): 77-83.
15. Dr. Kulwinder Singh, Dr. Manjeet Singh, Dr. RakeshGautam. Functional Outcome of Surgical Management of Tibial Plateau Fractures: Case Series of 30 Cases. International Journal of Science and Research (IJSR) 2015; 4 (9): 905-909.

How to cite this article: Dasgupta S, Dey S, Barman A, Moinuddin SK, Chatterjee P, Hasan N. Functional Outcome of Intra-Articular Proximal Tibia Fractures (41C) Treated with Dual Plate Osteosynthesis. Ann. Int. Med. Den. Res. 2019; 5(4):OR16-OR19.

Source of Support: Nil, **Conflict of Interest:** None declared