

MRI Spectrum of Symptomatic and Non –Symptomatic Tarlov Cyst: Series of Seven Cases in Orthopaedic Management Point of View.

Viney Kumar Govila¹, Naresh Chander Arora², Hira Lal Kakria³, Meghna Varma⁴, Nitish Virmani⁵, B B Sharma⁶

¹Assistant Professor, Department of Orthopedics, SGT Medical College, Gurugram (Haryana) 122505.

²Professor, Department of Orthopedics, SGT Medical College Budhera (Gurgaon) 122505.

³Professor & HOD, Department of Orthopedics, SGT Medical College Budhera (Gurgaon) 122505.

⁴Post Graduate MD Radiodiagnosis, Department of Radio-diagnosis, SGT Medical College Budhera (Gurgaon) 122505.

⁵Assistant Professor, Faculty of Allied Health Sciences, SGT University, Gurgaon (Haryana).

⁶Professor & Head, Dept.of Radio-diagnosis,SGT Medical College Budhera (Gurgaon) 122505.

Received: March 2019

Accepted: March 2019

Copyright: © the author(s), publisher. It is an open-access article distributed under the terms of the Creative Commons Attribution Non-Commercial License, which permits unrestricted non-commercial use, distribution, and reproduction in any medium, provided the original work is properly cited.

ABSTRACT

Background: Tarlov cysts are perineural cysts and are usually found in sacral region. The dorsal nerve root is encased in this type of the cyst. These may or may not be with any of the symptomatology. The entity is infrequently found as an incidental finding. These are cerebrospinal fluid (CSF) filled sacs which are diagnosed on cross sectional imaging modalities especially in magnetic resonance imaging (MRI). Tarlov cysts can cause different type of myelopathies as per their location and size. **Methods:** We present a series of seven cases where these perineural cysts were found during the routine imaging of lumbosacral spine. All these patients had undergone Magnetic Resonance Imaging (MRI) of lumbosacral spine for backache or some other pelvic complaints. In one case Computerized Tomography (CT) Myelography also helped in diagnosis and related bone remodeling.MR myelography adds to the delineation of CSF wrapping around the spinal cord. **Results:** Three patients were found to be symptomatic and the intensity of complaints corresponded to the size and location of the cysts. In our three cases, the etiopathogenesis also corresponded to the underlying development of these entities. Four patients were asymptomatic as the size of these cysts were small and not contributing to the complaints of the patient. **Conclusion:** MRI is the best modality to diagnose these perineural cysts which are responsible for different types of myelopathies .T2WI sequences in non contrast MRI studies are the best in delineating the size, shape, outline and location of these cysts. This also further elaborates their extension to the surrounding regions.MR myelography is adjuvant to more morphological features of these cysts.

Keywords: Tarlov cyst; CSF; MRI; CT Myelography; myelopathies.

INTRODUCTION

Tarlov cyst is a perineural CSF filled cyst which is having the nerve root within it. These are the meningeal dilatation with CSF present on the dorsal nerve root. These can be differentiated from pure meningeal cysts because of their nerve fibre walls. These are responsible for various

myelopathies depending upon size, shape, outline and their extension in the surrounding anatomical structures. These affects the dorsal roots and produce symptomatology accordingly. These cysts were named after the renowned neurologist Isadore M Tarlov. He studied thirty cadaveric filum terminale in 1938 at Montreal Neurological Institute to describe these type of perineural cysts.^[1]

Name & Address of Corresponding Author

Dr. B B Sharma
Professor & Head,
Department of Radio-diagnosis, SGT Medical College
Budhera (Gurgaon) 122505
C 35 First Floor,
Anand Niketan,
New Delhi - 110021

MATERIALS AND METHODS

There were seven patients (n=7) who were found to be having these perineural cysts during the MRI scanning of lumbosacral region. Five patients were male (71.4%) and two female (28.6%) in the age

group of 30- 64 years (mean age 48.3 years). Most of the patients reported with the vague low backache except one patient who had some weakness in both the lower limbs. This case was having additional finding of prolapsed intervertebral disc at L3-L4 vertebral level. The lumbosacral spine of this patient had also underlying degenerative changes. The female patients were of younger age group and had one or two normal deliveries.

Case Report 1

46-years old reported to the orthopedic department with chronic low backache of two years duration. The pain used to aggravate in bending movements. Plain Lumbosacral spine X-ray was unremarkable. Systemic examination was normal without any findings. Patient was subjected to MRI examination and found to be having incidental finding of Tarlov cyst [Figure 1 a,b and c]

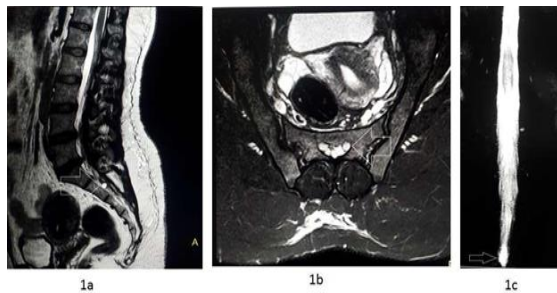


Figure 1: Case #1: MRI Lumbosacral spine of 46-years old male with low backache of two years duration. (a) T2W Sagittal section shows a hyperintense small round lesion as an incidental finding present on the dorsal aspect of S3 vertebral body (white arrow). (b) T2W axial section shows the same lesion as perineural cyst on left side (white arrow). (c) MR myelography shows subtle findings of prominence of the caudal end of the spinal cord (white arrow).

Case Report 2

63-years old male anaesthetist of our institute was having low backache of four years duration and urinary bladder disturbances of three months. There was no relief by symptomatic treatment. Systemic examination did not reveal anything. All the biochemical parameters were normal. Plain X-ray Lumbosacral spine was normal. He was subjected to MRI study of Lumbosacral spine and found to be having Tarlov cyst [Figure 2 a,b and c] Surgical fenestration had been advised as the symptomatic treatment was of no benefit.

Case Report 3

36-years old female medical doctor was having low backache of four years duration which was not getting relieved with the symptomatic treatment. She had six years old child who was delivered normally. The vague complaints started soon after the delivery and kept on increasing in severity.

Now for the last one year she is having additional problems of sexual dysfunctions. Plain x-ray of the Lumbosacral spine did not reveal anything. She had undergone MR examination of the Lumbosacral spine. MRI revealed bilateral multiple fingerlike perineural cysts at the sacral level. There was no abnormality in the intervertebral discs. There was mild erosion of the adjoining area of sacral vertebrae [Figure 3 a,b and c]

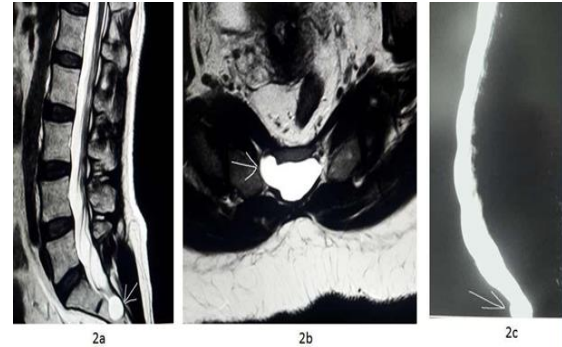


Figure 2: Case #2: MRI Lumbosacral spine of 63-years old male anaesthetist with low backache and urinary bladder disturbances. (a) T2W Sagittal section shows a well defined hyperintense lesion on the dorsal aspect of S2 vertebra (white arrow). (b) T2W axial section shows the same lesion on right side at the same level with some bony erosion (white arrow). (c) MR myelography shows a well defined rounded prominence at the caudal end of the spinal cord (white arrow).

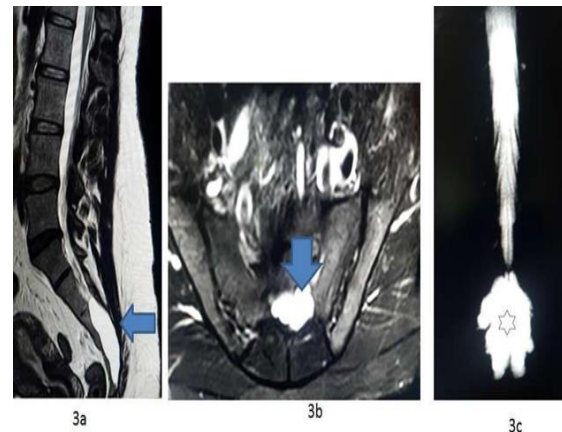


Figure 3: Case 3- MRI Lumbosacral spine of 36-years old female medical doctor with low backache and sexual dysfunction of increasing severity. (a) T2W Sagittal section shows a big vertically expanded hyperintense lesion against dorsal aspect of sacral vertebrae (horizontal blue arrow). (b) T2W axial section shows the expanded hyperintense lesion at mid sacral level (inverted blue arrow). (c) MR myelography shows multiple perineural cysts as finger like projections from the lower end of the cord (black star).

The case # 3 had been advised for surgical sleeving as the management because of the bigger size Other four cases were having very small size of the cysts which required no further management.

RESULTS & DISCUSSION

These perineural cysts were considered as asymptomatic initially but the symptoms have been noticed even in those patients where these have been found incidentally. The incidence is around 5% and more common in females. In our study the incidence was more in males as compared to females.^[2] These have also been associated with syndromes like Marfan, Ehlers-Danlos and Loeys-Dietz syndromes.^[3]

These are extradural in nature. These have got the potential communication with the subarachnoid space as compared to the meningeal cysts which have got free communication. Though the size is not related to the symptomatology but those which are more than 1 cm in size have been found to be of symptomatic in nature. MRI and CT myelography pick up these as an incidental findings. These can contain few milliliters to 2.5 liters of CSF within them.^[4] The increase in size has been attributed to check valve mechanism. The increase in size does not correlate with the symptomatology. The prominent factors for the etiology of the formation of these cysts are either post traumatic or child birth. In our case #3 the underlying factor appears to be related to child birth as the complaints started soon after the child birth. Nabors et al classify arachnoid cysts into:

Type I: Extradural without nerve roots

Type II: Extradural with nerve roots (Tarlov belongs to this category)

Type III: Intradural which are either of traumatic or congenital in origin

The outer wall of the cyst is composed of vascular connective tissue and the inner lining is that of flattened arachnoid tissue.

These cysts can be multiple and can enlarge in size to 3-4 cm. Our case #3 belongs to this category. Their intra abdominal extension has also been known. The large cysts can compress the adjoining organs and can cause symptoms accordingly. The bone erosion has also been noticed in some cases.^[5] These can also appear in the form of cluster of multiple as it was in our case #3. These can cause unilateral or bilateral symptoms. Infertility has been encountered in few cases.^[6] 15-30% cases have been reported with presentable symptoms. The commonest symptoms are pain, paresthesia, muscular weakness, spasticity and radiculopathy. There can be different grading of the symptomatology depending upon the location and the size of the cysts. Tarlov has described the formation of these cysts is due to the blockage of the venous drainage but Fortuna et al has advocated it because of congenital arachnoidal proliferation.^[7] These may increase in size with the passage of time but the size can remain unchanged over the years. The increase in size is because of systole push of

CSF in the cyst and inability of its going back in diastole. This leads to increase in the size. The symptoms keeps on increasing with the increase in size. MRI and CT myelography are the most effective examinations for the diagnosis of these entities. CT in addition can highlight the underlying status of the adjoining bone. CT myelography can also be the choice for the patients who are not fit for MRI.^[8] MRI has multiplanar, multisectional, non invasive nature capabilities and is also free of radiation hazards. MRI can further differentiate Tarlov cyst from other resembling pathologies like dermoids, epidermoids or teratomas. These can also be misdiagnosed and can be confused with conditions related to disc herniation. Tarlov cyst can rupture unnoticed by either fracture or other adjoining pathologies like aneurysms. Multiple cysts are more prone to get ruptured. This can lead to intracranial hypotension causing headache, nausea and vomiting. Biosynthetic dural patch is required to repair this rupture. These symptoms can be relieved in supine position. Micro fenestration and surgical sleeving of these cysts is the choice of treatment because of its innervations and compression features. Biopolymer plate is used to strengthen the adjoining bone if it is thinned out due to the cyst. The aspiration of the fluid and fibrin glue injection has always been with some risk. There are various complications like leakage of CSF and seepage of glue fibrin.^[9]

CONCLUSION

Tarlov cysts remain silent in majority of the cases but become symptomatic in a few cases. The management issue becomes the problematic issue for orthopedic surgeon until the morphological characteristics are evaluated by MRI. These have been found as incidental finding in most of the times. MRI lumbosacral spine evaluation is the hallmark in management decision making. The symptomatology ranges from simple pain to neurological deficit. The proper attention has to be paid to their location, size, number and extension to the adjoining structures. The management differs from case to case basis and MRI plays a great role in deciding the choice of surgical or other interventional remedial techniques. This also differentiates from other similar pathologies. Plain CT is very informative in large cysts to know about the erosion of the bone located in the vicinity. Follow up MRI after the treatment is utmost important because of the fear of re appearance by refilling of the cyst by CSF.

Acknowledgement

We are thankful to MRI and CT technicians: Mr Rohit and Miss Suzeen Mkroo and data entry operator Miss Jaya Jain of SGT University Gurugram for contributing the input.

REFERENCES

1. Nadler SF, Bartoli LM, Stitik TP, Chen BQ. "Tarlov cyst as a rare cause of S1 radiculopathy : a case report". Archives of Physical Medicine and Rehabilitation 2001;82(5):689-690.
2. Sharma BB, Sharma S, Ramachandran P, Jilowa S, Singh S. Symptomatic or Non Symptomatic Tarlov Cysts in MRI Imaging: Variety of Presentations. Asian Aca Res J Multid. April 2016; Vol 3(4):117-124.
3. Arnold PM, Teuber J. Marfan syndrome and asymptomatic sacral cyst report of two cases. J Spinal Cord Med. 2013;36(5):499-503.
4. Ishii K, Yuzurihara M, Asamoto S, Doi H, Kubota M. "A huge presacral Tarlov cyst-Case report". Journal of Neurosurgery-Spine 2007;7(2):259-263.
5. Tarlov IM. Spinal Perineural and Meningeal Cysts". J Neurol. Neurosurg. Psychiat 33:10.
6. Singh PK, Singh VK, Azam A, Gupta S. "Tarlov Cyst and Infertility". Journal of Spinal Cord Medicine 2009.;32(2):191-197.
7. Anaka M, Nakahara S, Nakinishi K, Sugimoto Y, Ikuma H; et al. "Surgical results of sacral Perineural (Tarlov) cysts". Acta Medica Okayama 2006; 60(1):65-70.
8. Lee JY, Impekoven P, Stenzel W, Lohr M, Ernestus RL, Klug N. "CT guided percutaneous aspiration of Tarlov cyst as a useful diagnostic procedure prior to operative intervention" 2004. Acta Neurochirurgica 146(7):667-670.
9. Feigenbaum F1, Handerson FC. Giant sacral meningeal diverticula: surgical implications of the "thecal tip" sign. Report of two cases. Neurosurg Spine. 2006 Nov;5(5):443-6.

How to cite this article: Govila VK, Arora NC, Kakria HL, Varma M, Virmani N, Sharma BB. MRI Spectrum of Symptomatic and Non –Symptomatic Tarlov Cyst: Series of Seven Cases in Orthopedic Management Point of View. Ann. Int. Med. Den. Res. 2019; 5(3):OR05-OR08.

Source of Support: Nil, **Conflict of Interest:** None declared