

# Importance of Hoffa's Pad Sign in MRI evaluation of various knee pathologies: a study conducted at SGT Hospital of SGT University of Gurugram Haryana.

Viney Kumar Govila<sup>1</sup>, Neeru Kapur<sup>2</sup>, Mir Rizwan Aziz<sup>3</sup>, Manav Sethi<sup>4</sup>, Nitish Virmani<sup>5</sup>, B B Sharma<sup>6</sup>

<sup>1</sup>Assistant Professor, Department of Orthopedics, SGT Medical College, Gurugram (Haryana) 122505.

<sup>2</sup>Assistant Professor, Department of Radio-diagnosis, SGT Medical College Budhera (Gurgaon).

<sup>3</sup>Senior Resident, Department of Radio-diagnosis, SGT Medical College Budhera (Gurgaon) 122505.

<sup>4</sup>Post Graduate MD Radiodiagnosis, Dept. of Radio-diagnosis, SGT Medical College Budhera (Gurgaon) 122505.

<sup>5</sup>Assistant Professor, Faculty of Allied Health Sciences, SGT University, GURGAON (Haryana).

<sup>6</sup>Professor & Head, Department of Radio-diagnosis, SGT Medical College Budhera (Gurgaon) 122505.

Received: March 2019

Accepted: March 2019

**Copyright:** © the author(s), publisher. It is an open-access article distributed under the terms of the Creative Commons Attribution Non-Commercial License, which permits unrestricted non-commercial use, distribution, and reproduction in any medium, provided the original work is properly cited.

## ABSTRACT

**Background:** Hoffa's fat pad is intracapsular and extra synovial structure present behind the patella and Infrapatellar tendon. This is delineated nicely in magnetic resonance imaging (MRI) by which it has become a modality of choice for its evaluation. The evaluation is by disruption of the outline of this region due to injury or other underlying pathologies. The indirect signs of this fat pad corresponds to the grading of associated trauma or underlying disease. **Methods:** We had conducted the MRI knee studies of fifty three patients which included both the genders from March 2018 to July 2018. They all were having complaints of knee pain because of different aetiologies. This cross sectional study included from 7-70 years of age group and patients were evaluated for the characteristics of Hoffa's pad in MRI. The morphological characters of the region were studied and correlated in relation to the corresponding pathology. **Results:** There was excellent delineation and intensity relationship of HFP in various MRI sequences. The most vulnerable group to the changes was in 21-30 years age group. The trivial trauma was the most common cause. The left knee was affected more than the right. **Conclusion:** Hoffa's fat pad sign is an excellent indicator in various knee pathologies during MR evaluation. This also helps to know the involvement of the associated surrounding structures. MRI evaluation is very helpful in the decision making for the line of management.

**Keywords:** fat pad; magnetic resonance imaging; pathology; trauma

## INTRODUCTION

Hoffa's fat pad is collection of fat between patella with the tendon on the anterior aspect and the synovium of the knee joint posteriorly. Infrapatellar fat pad of Hoffa is anatomical important landmark as the outline of this region get disturbed in many traumatic and pathological conditions.<sup>[1]</sup> Anterior knee pain is usually due to the impingement of this fat pad. This pain can be confused with patellar tendonitis. The pain is on the tendon in tendonitis

but fat pad impingement causes pain on both sides of the tendon.<sup>[2,3]</sup> This has got following relationships:

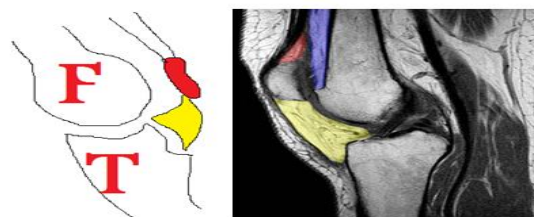
**Superior:** inferior pole of patella

**Inferior:** proximal tibia and deep Infrapatellar bursa

**Anterior:** Infrapatellar tendon and joint capsule

**Posterior:** synovium lined joint cavity.

All these relations are well understood in the diagrammatic presentation with the corresponding MRI images [Figure 1 and Figure 2].



**Figure 1: Diagrammatic representation of Infrapatellar fat pad in yellow color (Hoffa pad)**

### Name & Address of Corresponding Author

Dr. B B Sharma  
Professor & Head,  
Department of Radio-diagnosis, SGT Medical College  
Budhera (Gurgaon) 122505  
C 35 First Floor,  
Anand Niketan, New Delhi – 110021.

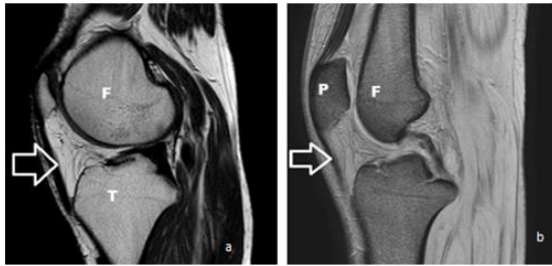


Figure 2: Sagittal sections of knee showing delineation of normal HFP with relation to femur (F) ,tibia (T) and patella(P).(a) T2WI shows hyperintense HFP(white arrow).(b) FFE depicts HFP in relation to the adjoining structures(white arrow).

**MATERIALS AND METHODS**

The study was conducted in the department of Radio-diagnosis of SGT Hospital Gurugram between March 2018 to July 2018. Total fifty three patients of both the genders [Figure 3] were included in the study who visited the orthopedic clinic with the pain in either of the knees. The group comprises of forty one male (77%) and twelve females (23%).This included the patients from seven to seventy years with the mean being 30.9 years. The most affected group constituted from 21 -30 years age group (33.9%) [Figure 4 and Figure 5]. All the patients were subjected to Magnetic resonance imaging of the knee as per the standard protocol. These were evaluated for the various inner structures like ligaments, menisci, joint capsule, joint space and surrounding neuromuscular structures. The main emphasis was laid on the morphology of the Hoffa's pad sign.

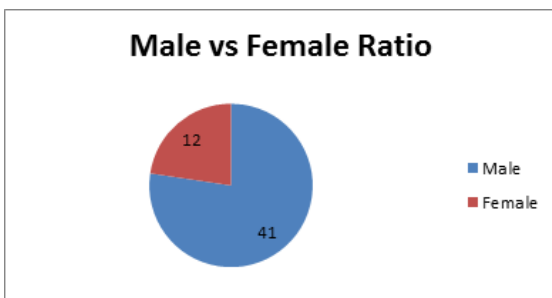


Figure 3: Pie chart showing the distribution of the cases as per the sex

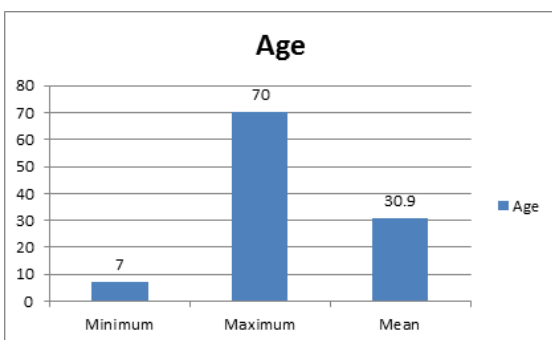


Figure 4: Bar chart depicting the mean age of the patients as per distribution.

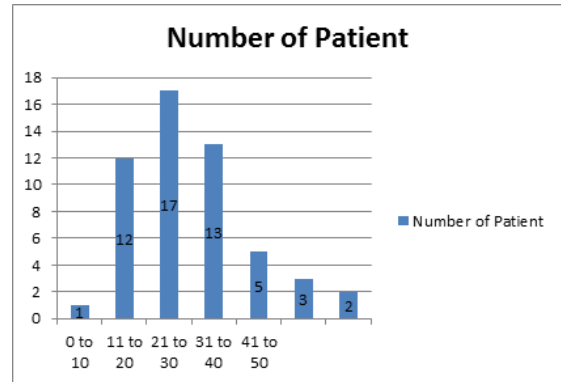


Figure 5: Bar chart showing the distribution of the patients in different age groups.

The incidence of affected knee was unilateral in all the cases. The left knee was affected more (53%) as compared to right (47%) [Figure 6].

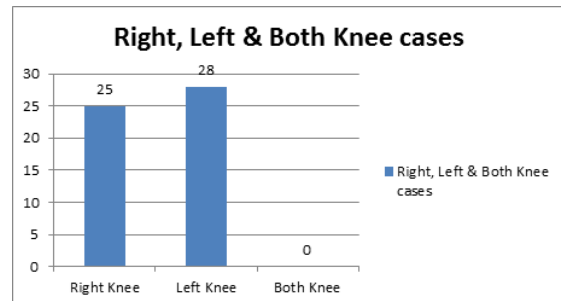


Figure 6: Bar chart showing the distribution of the patients as per the side.

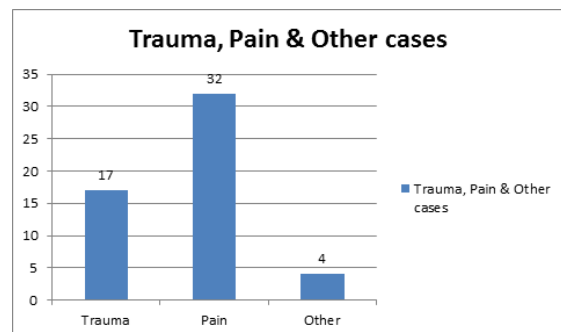
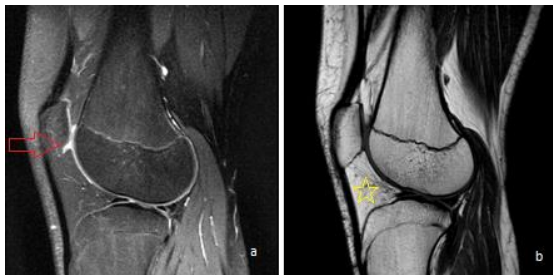


Figure 7: Bar chart showing the distribution of the patients as per the presenting symptoms.

The majority of the patients (60.37%) were of non specific pain as compared to the traumatic aetiology (32.07%).The remaining patients were of the miscellaneous group (7.5%) which constituted infective and related pathologies (Figure 7).Following observations related to HFP were noticed in the series:

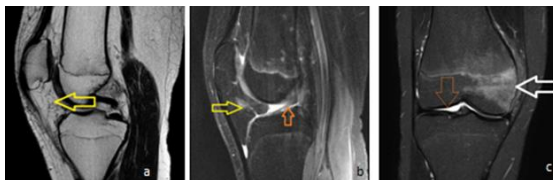- a) Normal configuration in 10 cases (18.86%)
- b) Plica hypertrophy 21 case (39.62%)
- c) Edema of HFP 20 cases (56.60%)
- d) Fragmentation of HFP in 36 cases (67.92%)
- e) Marrow edema of adjoining bones 40 cases (75.47%)
- f) Other associated findings in 4 cases (7.47%)

The younger age group mainly reported with mild trauma and had shown preserved delineation of Hoffa's fat pad except there were prominent superior and inferior recesses [Figure 8].



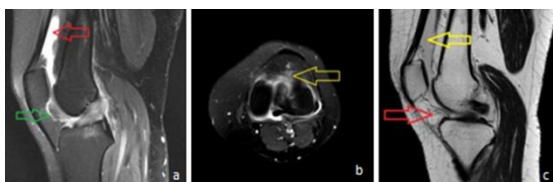
**Figure 8:** MRI left knee of 15-years old male with history of trauma.(a)sagittal section proton density with fat saturation shows superior recess of Hoffa's pad (red arrow) .(b) T1W sagittal section shows well delineated hyperintense Hoffa's fat pad (yellow star).

One of the patient 16-years old boy with history of trauma was having thickened plica and this was associated with the other post traumatic relevant findings [Figure 9].



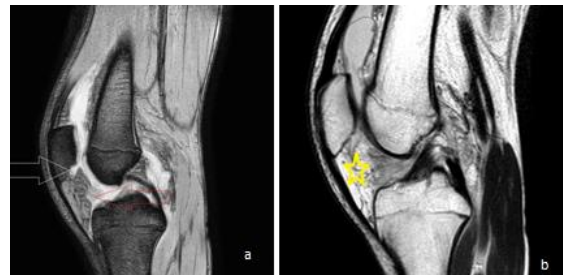
**Figure 9:** MRI right knee of 16-years old boy with trauma.(a) T1W thin sagittal sections show thickened infrapatellar plica (yellow horizontal arrow).(b) Proton density STIR sagittal section shows edema and fragmentation of fat pad (yellow arrow) with increased signal intensity in anterior cruciate ligament(saffron arrow).(c) Short tau inversion recovery (STIR) coronal section shows increase signal intensity on the medial femoral condyle suggestive of post traumatic marrow edema (white horizontal arrow).

Another 25-years old female was having history of pain in the left knee for the over four months without any relief. MRI evaluation had shown the fragmented HFP and with suprapatellar synovial fluid collection [Figure 10].

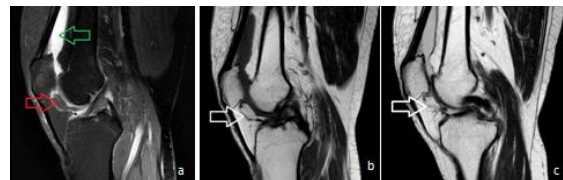

**Figure 10:** 25-years female with history of pain in left knee of four months duration.(a)Proton density SPIR sagittal section image shows fragmented HFP (green arrow) and fluid in suprapatellar fossa (red arrow).(b) axial section of the same shows fragmented of HFP (yellow arrow).(c) T2WI sagittal section shows thickened plica (red arrow) and suprapatellar fluid collection (yellow arrow).

There was evidence of fluid collection in both the recesses of HFP in a mild trauma case of a 14 years old boy. This had shown the edematous HFP [Figure 11].



**Figure 11:** Post traumatic MRI of 14 –years old boy (a) PDW images with suprahoffotic (white arrow) and infrahoffotic (red arrow) recesses.(b) T2WI shows enlarged edematous HFP(yellow star) and suprapatellar fluid collection.



**Figure 12:** MRI of 50 years old female with left knee pain.(a) sagittal section of proton density image with fat saturation shows partial hypertrophied plica of HFP (red arrow) with fluid in suprapatellar fossa (green arrow).(b)

All the patients were treated as per the underlying pathology. The majority of the non-traumatic cases were treated conservatively with the regular follow up. The cases having intracapsular fractures , additional ligament and meniscal injuries were treated surgically.

## RESULTS & DISCUSSION

Hoffa's fat pad is important structure between the synovium and capsule. This acts as cushion for various impact forces. Plica Ligamentum mucosum connects it to the intercondylar notch superiorly.<sup>[4]</sup> The transverse geniculate ligament traverses on the posterior aspect. This is attached to the inferior aspect of the anterior horns of the menisci and the tibial periosteum. This is supplied by superior and inferior geniculate arteries which are having an in between anastomosis.<sup>[5]</sup> This region is rich in innervations and responsible for the cause of anterior knee pain. It is because of this HFP that friction is avoided between the patella, patellar tendon and deep skeletal structures. HFP anatomical disturbance and pain is the result of multiple impingement, inflammation, surgical interventions and local micro traumas. This leads to many arthrofibrotic lesions which can easily be evaluated by MRI of the affected knee.<sup>[6,7]</sup> Post surgical edema of this fat pad can leads to

Cyclops lesions. The trauma can be direct or indirect. Infrapatellar plica syndrome or impingement can be the result of acute or repetitive microtraumas. These factors lead to local bleeding and inflammation which is the cause of anterior knee pain.<sup>[8]</sup> This further leads to arthrofibrotic lesions depicting chronicity. There are various factors which are responsible for the underlying etiologies have been described in the following chart [Figure 13]

Intrinsic Factors	Extrinsic Factors	Extra capsular disorders
Hoffa disease Intracapsular chondroma Localized nodular synovitis Post surgical or arthroscopic fibrosis Shear Injury	Internal derangement and articular disorders (Joint effusion and intra articular bodies, meniscal cyst, ganglion cysts, Cyclops lesion)  Synovial disorders (synovial proliferation with hemosidrine deposition, synovial proliferation with intra articular bodies, synovial and fatty proliferation, on specific proliferation)	Fractures, Patella sleeve fracture, Patellar tendon rupture, Sinding-Larsen-Johansson disease, Deep Infrapatellar bursitis and Osgood Schlatter disease

**Figure 13: Chart shows the multiplicity of factors responsible for Hoffa's fat pad disturbances and pathologies.**

The management of the cases depend upon the associated or primary injury. Otherwise simple impingement require only conservative treatment in the form of physical therapy, local corticosteroid injections, taping and to avoid the movements and sports responsible of the pain. The excision of HFP is reserved for the patients having chronic pain not being relieved from the conservative treatment.<sup>[9-11]</sup>

### CONCLUSION

HFP evaluation has a great significance in MR evaluation of knee trauma and other pathologies. This highlights the direct or indirect evidence of the derangement of HFP. The most common findings seen in our study were of marrow oedema, fragmentation and oedema of HFP and plica hypertrophy as per descending order.

#### Acknowledgement

We are thankful to Mr Rohit Sangwan MRI technician and Ms Jaya Jain data entry operator for conducting the study and compiling the data respectively.

### REFERENCES

- Saddik D, McNally EG, Richardson M, MRI of Hoffa's fat pad. *Skeletal Radiol.* 2004;33(8):433-444.
- Fenn S, Datir A, Saifuddin A. Synovial recesses of the knee: MR imaging review of anatomical features. *Skeletal Radiol.* 2009 Apr;38(4):317-28.
- Gracia-Valtulle R, Abascal F, Cereza L, et al. Anatomy and MR imaging appearance of synovial plicae of the knee. *Radiographics.* 2002;22(4):775-784.
- Jacobson JA, Lenchik L, Ruhoy MK, Schweitzer ME, Resnick D. MR imaging of the Infrapatellar fat pad of Hoffa. *Radiographics.* 1997 May-Jun;17(3):675-91.
- McCarthy CL, McNally EG. The MRI appearance of cystic lesions around the knee. *Skeletal Radiol.* 2004 Apr; 33(4):187-209.
- Vassiou K, Viychou M, Zibis A, Nikolopoulou A, Fezoulidis I, Arvanitis D. Synovial plicae of the knee joint: the role of advanced MRI. *Postgrad Med J.* 2015 Jan;91(1071):35-40.
- De Smet AA, Davis KW, Dahab KS, Blankenbaker DG, del Rio AM, Bernhardt DT. Is there an association between superolateral Hoffa fat pad oedema on MRI and clinical evidence of fat pad impingement? *AJR Am J Roentgenol.* 2012;199(5):1099-1104.
- LLopis E, Padr' on M. Anterior knee pain. *Eur J Radiol.* 2007;62:27-43.
- Schindler OS. 'The Sneaky Plica' revisited: morphology, Pathophysiology and treatment of synovial plicae of the knee. *Knee Surg Sports Traumatol Arthrosc.* 2014;22(2):247-262.
- Abreu MR, Chung CB, Trudell D, Resnick D, Hoffa's fat pad injuries and their relationship with anterior cruciate ligament tears: new observation based on MR imaging in patients and MR imaging and anatomic correlation in cadavers. *Skeletal Radiol.* 2008;37(4):301-306.
- Campagna R, Pessis E, Biau DJ, et al. Is superolateral Hoffa fat pad oedema a consequence of impingement between lateral femoral condyle and patellar ligament? *Radiology.* 2012;263(2):468-474.

**How to cite this article:** Govila VK, Kapur N, Aziz MR, Sethi M, Virmani N, Sharma BB. Importance of Hoffa's Pad Sign in MRI evaluation of various knee pathologies: a study conducted at SGT Hospital of SGT University of Gurugram Haryana. *Ann. Int. Med. Den. Res.* 2019; 5(3):OR01-OR04.

**Source of Support:** Nil, **Conflict of Interest:** None declared