

Surgical Management of Giant Skull Osteomas in Western U.P. Region.

Sanjay Sharma¹, Namita Sharma²

¹Consultant Neurosurgeon, CNS Hospital, Centre for Neurosciences, Meerut.

²CEO, CNS Hospital, Meerut.

Received: December 2018

Accepted: January 2019

Copyright: © the author(s), publisher. It is an open-access article distributed under the terms of the Creative Commons Attribution Non-Commercial License, which permits unrestricted non-commercial use, distribution, and reproduction in any medium, provided the original work is properly cited.

ABSTRACT

Background: Benign osteoblastic anomalies are uncommon bone tumors and commonly divided into osteoid osteomas and benign osteoblastomas according to their biological behaviour. Among these primary benign bone tumor osteomas are the most commonly found at the site of skull and face. Osteomas are usually asymptomatic as they increase in size slowly. Therefore, present study was designed to evaluate the clinical, radiological, and surgical aspects of osteomas in patients with giant skull lesions. **Methods:** This study was conducted in CNS Hospital, Centre for Neurosciences and Narayan Superspeciality hospital, Meerut and SVBP Hospital associated with LLRM Medical College, Meerut between the period of 2015 and 2018. The 12 successive patients with giant osteomas were treated surgically in the hospital. The patient population consisted of adult female patient ranging from 12 to 70 years with median age of 40 years and having giant cranial osteomas involving the cranial vault and some with extension into the paranasal sinuses or orbital wall. **Results:** Most common site of lesions was frontal portion of skull. Further, most common complaint of the patients was headache (50%). Further, slowly growing mass (44.4%) was the second most common complaint followed by proptosis in one patient. The mean diameter was 5.75 cm with range of 3 to 10 cm in all patients. The mean time duration of the patients of the onset of the tumor was 3 years with range from 6 months to 5 years. Histopathology picture of the patients revealed that tumors were composed of osteoid lamina. Further, different quantity of osteoid with major cement lines were found in trabeculae of laminae. **Conclusion:** Osteomas are normally benign tumors without any symptoms; However, surgical removal could be required for the cosmetic reasons. On the other hand, for the osteomas with different symptoms surgical treatment is the only choice of treatment. A considerable precaution and care of blood supply and surrounding brain tissue should be taken during radical extraction of the giant tumors.

Keywords: Osteomas, Location, Surgery, Reoccurrence.

INTRODUCTION

Benign osteoblastic anomalies are uncommon bone tumors and commonly divided into osteoid osteomas and benign osteoblastomas according to their biological behaviour. Among these primary benign bone tumors osteomas are the most commonly found at the site of skull and face.

Approximately 0.5% of tumors are osteomas among all types of tumors. Most of the osteomas are painless; whereas, incidental finding of 3% and 1% in CT scan and X ray respectively has been recorded.^[1] Tenderness in the vicinity of the osteomas is among the most common physical findings. Osteoblastomas has been found associated with neurological disorders frequently. Bone scan is the most effective diagnostic tool for assessing the prognosis osteoblastomas after surgery.

Osteomas are broadly divided into two types of

tumors. Exostoses or bone surface tumors originate from surface of bones and extend to the cranial vault, mandible, and external auditory canal whereas; paranasal sinus tumors or sino-orbital osteomas originated from paranasal sinus extend to nasal cavity and orbits.^[1,2]

Osteomas are usually asymptomatic as they increase in size slowly. Clinical symptoms of the osteomas are usually determined by the location, size and extension of tumors. Most of the osteomas are less than 10 mm in size; while, tumors more than 30mm diameter are known as giant tumors.^[3,4] Therefore, present study was designed to evaluate the clinical, radiological, and surgical aspects of osteomas in patients with giant skull lesions.

MATERIALS AND METHODS

This study was conducted in CNS Hospital, Centre for Neurosciences and Narayan Superspeciality hospital, Meerut and SVBP Hospital associated with LLRM Medical College, Meerut between the period of 2015 and 2018. The 12 successive patients with

Name & Address of Corresponding Author

Dr. Sanjay Sharma
Consultant Neurosurgeon,
CNS Hospital,
Centre for Neurosciences, Meerut.

giant osteomas were treated surgically in the hospital. The patient population consisted of adult female patient ranging from 12 to 70 years with median age of 40 years and having giant cranial osteomas involving the cranial vault and some with extension into the paranasal sinuses or orbital wall. In the preoperative period all the patients undergone neurological and radiological evaluation which includes plain radiographs [Figure 1 a], CT scans of head and three dimensional cranial CT [Figure 1b]. The origin and extension of each osteoma along with its dimensions and thickness was measured.

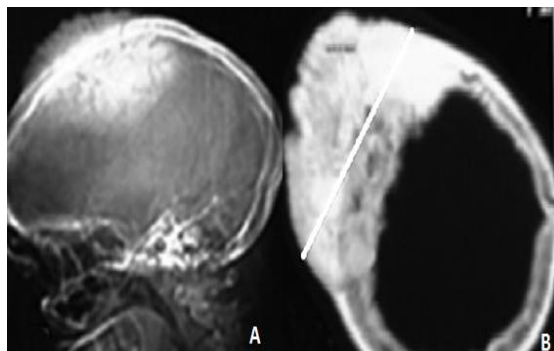


Figure 1 a: X ray lateral plan. Figure 1 b: CT scan head. (Showing right parietal hyperdense area)

RESULTS

Results of the current study showed the all the patients of giant osteomas belong to 12 to 70 years age group with median age 40 years. [Table 1] shows that most common site of lesions was frontal portion of skull. Further, most common complaint of the patients was headache (50%). Further, slowly growing mass (44.4%) was the second most common complaint followed by proptosis in one patient. The mean diameter was 5.75 cm with range of 3 to 10 cm in all patients. The mean time duration

of the patients of the onset of the tumor was 3 years with range from 6 months to 5 years.

General anesthesia was used for each and every patient before performing the surgery. The type of surgery was selected on the basis of size, location and extension of the tumors and their relation with various underlying structure of the skull. Craniectomy was the surgical technique used for the frontal bone surgery. Orbital reconstruction was done for temporal and frontotemporal tumors. Titanium mesh was used for cranioplasty after the surgical procedure.

Pathological findings

[Figure 2] shows the histopathology picture of the patients which revealed that tumors were composed of osteoid lamina. Further, different quantity of osteoid with major cement lines were found in trabeculae of laminae. There was no bone marrow component in the lesion. Surrounding tissue and bone were normal and no nuclear atypia was recorded in the histological picture of the patients.

Postoperative follow-up

Post operative care included evaluation of different hemodynamic parameters to ensure there is no secondary cerebrospinal fluid leaks due to dural tear. Antibiotics were used for all the patients after surgery at least for 3 days to avoid any infection. No complications were recorded in the present study except parietal haematoma in one patient. However, it was resolved completely. All the patients were physically and mentally normal during the time of follow up. No mortality was recorded in the present study during the time period of follow up. None of the patients reported reoccurrence of the osteomas. CT scan and plain x ray were done of all the patients after the surgery and follow up periods to assess if there is any complication of reoccurrence of the tumor at the site of the surgery.

Table 1: Characteristic and features of the tumors.

Origin	Time duration (Yrs)	Thickness (Cm)	Diameter (Cm)	Surgical Technique used	Complications
Frontal	3	4	8	Craniectomy + cranioplasty	None
Occipital	3.5	6	5	Craniectomy + cranioplasty	None
Temporal	2	2.9	3	Orbital reconstruction	None
Frontal	2.5	3.8	4	Craniectomy + cranioplasty	None
Frontal	4	7	8	Craniectomy + cranioplasty	None
Frontal	2	3	5	Craniectomy + cranioplasty	Parietal haematomas
Frontotemporal	2	3.9	6	Orbital reconstruction	None
Frontoparietal	4	2.8	4	Craniectomy + cranioplasty	None
Frontal	3	4.8	7	Craniectomy + cranioplasty	None
Temporoparietal	2	2.4	3	Grinding with high speed drill	None
Frontal	5	4.2	10	Craniectomy + cranioplasty	None
Frontal	2	3.5	6	Craniectomy + cranioplasty	None

DISCUSSION

Osteomas have a preference for the head and neck sites which incorporates the facial bones, skull, and mandible and is the most widely recognized variety of tumor of the sinonasal tract.^[5] Osteomas are

moderate developing tumors comprising altogether of very much separated bone. They are subdivided in ivory and develop types relying upon the extents of thick and cancellous bone. Ivory osteomas are made out of thick, develop, lamellar bone with minimal sinewy stroma. Develop osteomas are made out of

substantial trabeculae of develop, lamellar bone with increasingly inexhaustible stringy stroma and might possibly have osteoblastic rimming. Tumors with both ivory and develop highlights are portrayed as blended sort.^[2]

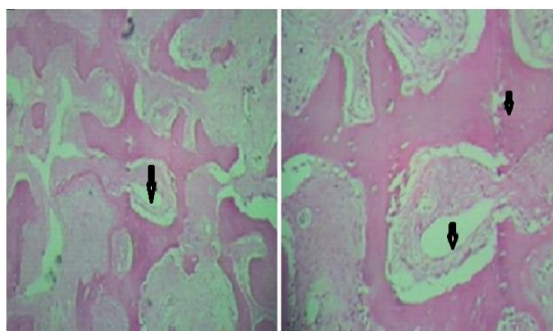


Figure 1: Histological picture of the tumor.
(= revealing dense lamellae along with organized haversian canals and intratrabecular stroma)

Present study included only female patients of osteomas with median age of 40 years. These findings are supported by earlier studies as female to male ratio was 2:1 whereas, the mean age of 39.8 years with age range of the patients was 16–64 years.^[6]

Findings of the present study revealed that all the osteomas were slowly growing and most of them were on the site of the frontal bone. All these osteomas are visible in plain radiograph as well as in CT scan. These findings are consistent with the findings of the earlier study of Haddad et al as they recorded frontal sinus was the most common site for the growth of osteomas followed by maxillary sinuses, the maxilla sinuses, temporal bone and ethmoid air cells. Moreover, they classified four types of osteomas (skull base, skull wall, dural and intraparenchymal). Skull base osteomas are most regular in the frontal sinus, however may likewise happen in the ethmoid air cells, maxillary and sphenoid sinuses, the maxilla and mandible and once in a while emerge in the transient bone. They are once in a while symptomatic however might be the reason for cerebral pains, orbital attack and deformation, pneumocephalus, rhinorrhea, meningitis and sore. Skull vault osteomas may emerge from the exostotic or enostotic and are typically asymptomatic.

There are various theories for the pathogenesis of osteomas including traumatic, infection and embryologic theories. Studies reported that more than 30% of osteomas had traumatic etiology with history of head injury. This injury of head causes inflammatory response which in turn induce the metaplastic process of bone tissue. Infectious etiology involve different types of infections like syphilis, tuberculosis etc which may cause growth of osteomas. It has been reported that osteoma originated from embryologic cartilage cells supports the embryologic theory.^[7,8] However, we have not

observed any history of infection or trauma in any patients of present study.

Radiography is traditionally used for the imaging of osteomas; nevertheless, CT scan has emerged as the technique of choice for the imaging of osteomas in the recent decades as it provides gross information about the thickness and location of the osteomas. Further, with the use of 3D technique along CT scan produce more pronounced image of osteomas as it is able to provide more precise quality and exact location along with extensions of the osteomas.^[9]

Studies suggest that osteoma increase in size gradually and slowly. This slow growth of osteoma may extent up to 12 to 20 years to become a giant tumor. Moreover, reoccurrence of the osteoma has been recorded 1 to 7 years.^[1]

Further, present study recorded that mean duration of tumor growth was 3 years in our study ranging from 6 months to 5 years. These findings are consistent with the earlier studies of Mc Hugh JB et al,^[2] and Erten F et al,^[3] as they recorded slow growth of osteoma in their studies. Various studies suggest that giant stroma may require surgical treatment due to different causes including larger size, pain and complications. On the other hand, traditional management instead of surgery is applied for the small size osteoma. However, in case of neurological store, pain and extension to adjacent structure may needed surgical approach even in small size osteoma.^[2-5]

CONCLUSION

Osteomas are normally benign tumors without any symptoms; However, surgical removal could be required for the cosmetic reasons. On the other hand, for the osteomas with different symptoms surgical treatment is the only choice of treatment. A considerable precaution and care of blood supply and surrounding brain tissue should be taken during radical extraction of the giant tumors.

REFERENCES

1. Secer HI, Gonul E, Izci Y. Surgical management and outcome of large orbitocranial osteomas. *J Neurosurg.* 2008;109:472–7.
2. McHugh JB, Mukherji SK, Lucas DR. Sino-orbital osteoma: A clinicopathologic study of 45 surgically treated cases with emphasis on tumors with osteoblastoma-like features. *Arch Pathol Lab Med.* 2009;133:1587–93.
3. Erten F, Hasturk AE, Pak I, Sokmen O. Giant occipital osteoid osteoma mimicking calcified meningioma. *Neurosciences (Riyadh)* 2011;16:363–5.
4. Haddad FS, Haddad GF, Zaatari G. Cranial osteomas: Their classification and management. Report on a giant osteoma and review of the literature. *Surg Neurol.* 1997;48:143–7.
5. Liu SC, Su WF, Nieh S, Lin DS, Chu YH. Lingual osteoma. *J Med Sci.* 2010;30:97–9.
6. Akiyama M, Tanaka T, Hasegawa Y, Chiba S and Abe T: Multiple intracranial subarachnoid osteomas. *Acta Neurochir (Wien).* 147:1085–1089. 2005.
7. Shigehara H, Honda Y, Kishi K, Sugimoto T. Radiographic and morphologic studies of multiple miliary osteomas of

cadaver skin. Oral Surg Oral Med Oral Pathol Oral Radiol Endod. 1998;86:121–5.

8. Cece H, Yildiz S, Iynen I, Karakas O, Karakas E, Dogan F. A rare case of petrous apex osteoma. J Pak Med Assoc. 2012;62:608–9.
9. Castelino RL, Babu SG, Shetty SR, Rao KA. Multiple craniofacial osteomas: An isolated case. Arch Orofac Sci. 2011;6:32–6.

How to cite this article: Sharma S, Sharma N. Surgical Management of Giant Skull Osteomas in Western U.P. Region. Ann. Int. Med. Den. Res. 2019; 5(2):MC05-MC08.

Source of Support: Nil, **Conflict of Interest:** None declared