

Epidemiological Factors Assessment and Study on Neck Structures Injury in Hanging Deaths.

V. Raja Sekhar¹, G. Dinesh²

¹Associate professor, Department of Forensic Medicine, Kurnool Medical College, Kurnool, Andhra Pradesh.

²Post Graduate, Department of Forensic Medicine, Kurnool Medical College, Kurnool, Andhra Pradesh.

Received: May 2019

Accepted: May 2019

Copyright: © the author(s), publisher. It is an open-access article distributed under the terms of the Creative Commons Attribution Non-Commercial License, which permits unrestricted non-commercial use, distribution, and reproduction in any medium, provided the original work is properly cited.

ABSTRACT

Background: Most of the hanging cases are considered as suicidal until the homicidal and accidental are proved, because both homicidal and accidental hanging are rare. In these cases a careful forensic examination plays an important role to determine the ante mortem character of the lesion and to exclude causes of hanging other than suicidal hanging. Aim: This study we carried to know the internal and external examination findings among hanging cases. **Methods:** Hanging deaths with external neck injuries along with ligature mark were included in this study. In this study a total of 60 cases of deaths due to hanging, was subjected to medico legal autopsy. **Results:** Majority of the cases were observed in the age group of 21-40 years i.e., 41 (69.4%) out of 59 hanging deaths. Out of 59 deaths, 32 (54.2%) were females and 27 (45.7%) were males. Among neck structure injuries, majority of hanging cases had rupture / contusion of sternocleidomastoid and other strap muscles of neck, it was 57.6%. 33.8% cases had carotid intimal tear, 5% cases showed hyoid bone fracture and 3.3% thyroid cartilage. No fractures noted in Cricoid cartilage and cervical vertebra. **Conclusion:** Social awareness, problem solving and family support of most common age group is extremely necessary.

Keywords: Hanging, Neck Structures.

INTRODUCTION

Most of the hanging cases are considered as suicidal until the homicidal and accidental are proved, because both homicidal and accidental hanging are rare. In these cases a careful forensic examination plays an important role to determine the ante mortem character of the lesion and to exclude causes of hanging other than suicidal hanging. Synonym of hanging is self-suspension.^[1]

Neck has many important structures which are crowded together in the neck such as muscles, glands, trachea, oesophagus, larynx, vessels, nerves, vertebrae etc.^[2]

Typical hanging is described when the point of suspension is over the centre of the occiput; the vessels of neck become occluded to the maximum. If the point of suspension is anywhere else, then it is called as atypical hanging.

Worldwide, in the past 45 years suicide rate have increased 60% and the suicide rate is 16 per 1,00,000 population. Approximately for every 40 seconds, one person dies by suicide globally. 1.8% of worldwide deaths are suicides.^[3]

Common reasons for hanging are loss of property, financial losses, poverty, and disgust with life, love failure, passion, physical and mental sufferings, failures in many aspects, marital problems, and religious mania. These Hanging causes vary from country to country.^[4]

This study we carried to know the internal and external examination findings among hanging cases.

MATERIALS AND METHODS

A Prospective study was conducted on cases suggestive of ante mortem hanging, in which the history and scene of crime examination report given by police and relatives of the deceased. This study conducted in 2018 (one year study) at Department of Forensic Medicine, Government Medical College, Kurnool.

Cases with external neck injuries along with ligature mark were included in this study. In this study a total of 60 cases of deaths due to hanging, was subjected to medico legal autopsy.

Details related to deceased persons including age, sex, place of hanging, reason for committing suicide, material used, type of knot, position of the knot, whether it was a complete or partial hanging, any blood stains or disturbance etc., at the scene of crime, presence of suicidal note and other relevant

Name & Address of Corresponding Author

Dr. G. Dinesh,
Post Graduate,
Department of Forensic Medicine,
Kurnool Medical College,
Kurnool, Andhra Pradesh.

Sekhar & Dinesh; Neck Structures Injury in Hanging Deaths

information were enquired from the police and relatives of the deceased.

After identification of the body, both external and internal findings were observed during post mortem examination. External findings such as injuries, saliva dribbling, signs of asphyxia, signs of sphincter relaxation, Le facie sympathetic, hypostasis pattern, rigor mortis, and ligature mark study etc. After removing thoracic organs and brain, dissection of neck was done.

During dissection of neck, skin, subcutaneous tissue, anterior cervical strap muscles were examined for contusion or injury. Carotid artery and internal jugular vein were examined for tears, extravasation of blood or ruptures. The hyoid bone, thyroid cartilage and cricoid cartilage were examined for areas of blood extravasation and fracture.

Blood samples and viscera were collected for systemic toxicological analysis according to regular procedures. All samples were sent to the Regional Forensic laboratory, Kurnool.

Data Obtained was entered into spread excel sheet and analysed.

RESULTS

A total of 59 cases of deaths observed due to hanging. Majority of the cases were observed in the age group of 21-40 years i.e., 41 (69.4%) out of 59 hanging deaths. Deaths due to hanging were not observed below the age group of 17 years. Among elders, one case of death observed in 71 years of age. Out of 59 deaths, 32 (54.2%) were females and 27 (45.7%) were males. Males and females were almost equally distributed in all the age groups [Table 1].

Table 1: Distribution of hanging deaths in different and age groups in relation to sex.

| Age in years | Male | % | Female | % | Total | % |
|--------------|------|------|--------|------|-------|-------|
| 1-10 | 0 | 0 | 0 | 0 | 0 | 0 |
| 11-20 | 4 | 6.7 | 9 | 15.2 | 13 | 22.03 |
| 21-40 | 20 | 33.8 | 21 | 35.5 | 41 | 69.4 |
| 41-60 | 3 | 5.08 | 1 | 1.6 | 4 | 6.7 |
| >60 | 0 | 0 | 1 | 1.6 | 1 | 1.6 |
| Total | 27 | 45.7 | 32 | 54.2 | 59 | 100 |

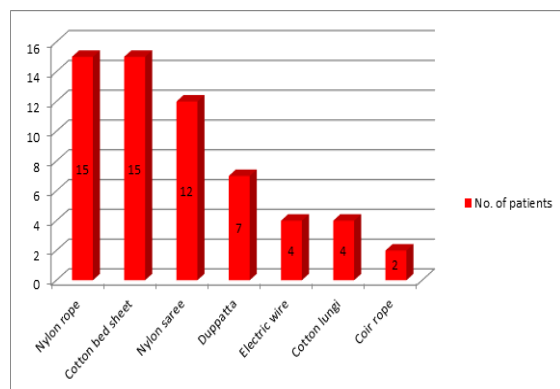


Chart 1: Number of various ligatures used for hanging

Nylon rope and cotton bed sheet were most commonly used ligature material followed by saree among hanging deaths. Nylon rope used in 15 (25.4%) cases, cotton bed sheet used in 15 (25.4%) cases, nylon saree used in 12 (20.3%) cases, duppatta used in 7 (11.8%) cases, electric wire used in 4 (6.7%) cases, cotton lungi used in 4 (6.7%) cases and coir rope used in 2 (3.3%) cases [Chart 1 & Figure 1].



Figure 1: Showing nylon rope used for hanging

Out of 59 Hanging cases, 24 (40.6%) were complete hanging and remaining 35 (59.3%) were partial hanging. On assessment of ligature mark position over the neck, 50 (84.7%) cases were seen above the thyroid cartilage and in only 9 (15.2%) cases it was seen over and above thyroid cartilage.

Incidence of position of knot was assessed. 36 (61%) cases, knot was on left side of neck, 17 (28.8%) cases knot was on back of neck, 4 (6.7%) cases, and knot was on right side of neck and 2 (3.3%) cases knot located below the chin [Chart 2 & Figure 2].

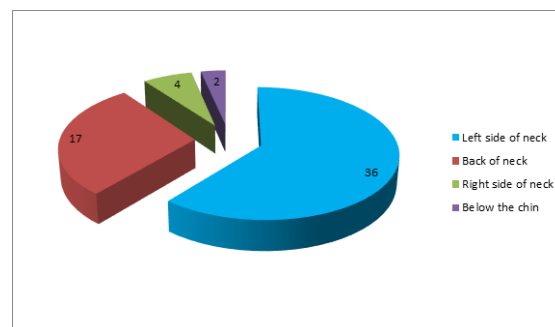


Chart 2: Various Positions of knot in Hanging deaths

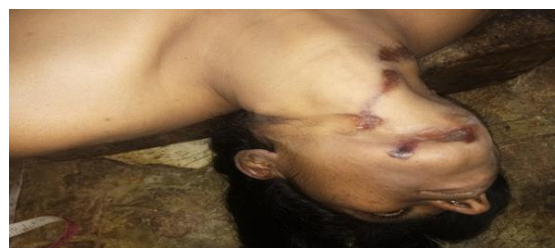

Figure 2: Showing Atypical hanging with knot position over the chin

Sekhar & Dinesh; Neck Structures Injury in Hanging Deaths

Among neck structure injuries, majority of hanging cases had rupture / contusion of sternocleidomastoid and other strap muscles of neck, it was 57.6%. 33.8% cases had carotid intimal tear, 5% cases showed hyoid bone fracture and 3.3% thyroid cartilage. No fractures noted in Cricoid cartilage and cervical vertebra [Chart 3, Figure 3 & Figure 4].

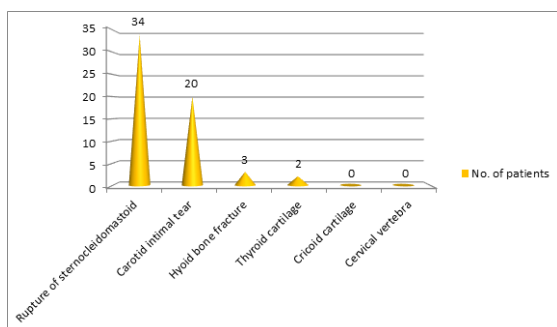


Chart 3: Neck structure injuries in deaths due to hanging

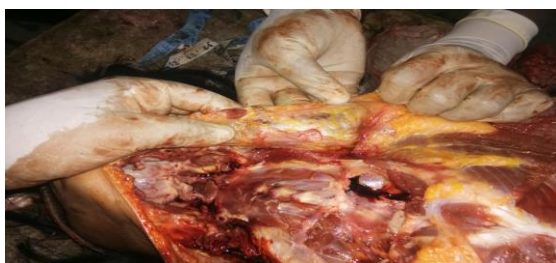

Figure 3: Showing Dissection of neck with soft tissue injuries

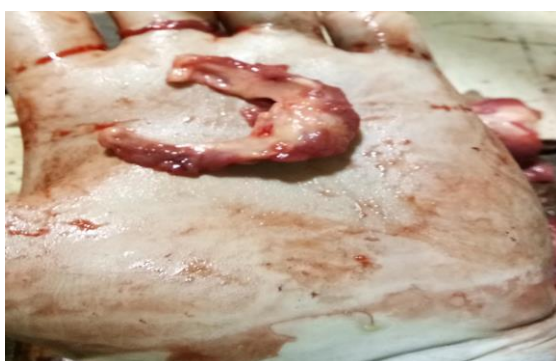

Figure 4: Showing inward fracture of hyoid bone

DISCUSSION

Hanging is a form of violent asphyxia death produced by suspending the body with a ligature around the neck, the constricting force being the weight of the body or a part of body weight.^[5] Asphyxia is defined as “the physiologic and chemical state in a living organism in which acute lack of oxygen available for the cell metabolism is associated with inability to eliminate excess of carbon dioxide”.^[6] Asphyxia or anoxia can occur due to interference with respiration by any mechanical obstruction in the air passages by constriction of air passages.^[7]

General external appearances can found among hanging deaths are pale face, dilated pupils, cyanosis, eyes may be closed or partially open, protruded tongue, dribbling of saliva, penis may be engorged, post mortem staining will be well marked.^[8]

In the present study, majority of the cases were observed in the age group of 21-40 years i.e., 41 (69.4%) out of 59 hanging deaths. Out of 59 deaths, 32 (54.2%) were females and 27 (45.7%) were males. Dr.Sharma BR et al did a retrospective study in 2005; documented male to female ratio of hanging cases was 2:1.^[9] They have also noticed 46% of hanging cases were observed in the age group of 21-30 years.

Nylon rope used in 15 (25.4%) cases, cotton bed sheet used in 15 (25.4%) cases, nylon saree used in 12 (20.3%) cases, duppatta used in 7 (11.8%) cases, electric wire used in 4 (6.7%) cases, cotton lungi used in 4 (6.7%) cases and coir rope used in 2 (3.3%) cases as per this study. Dr.Sharma BR et al documented, 54.7% of hanging cases used soft material as a ligature and remaining 28.6% of hanging cases used hard material.^[9]

Out of 59 hanging cases, 24 (40.6%) were complete hanging and remaining 35 (59.3%) were partial hanging. On assessment of ligature mark position over the neck, 50 (84.7%) cases were seen above the thyroid cartilage and in only 9 (15.2%) cases it was seen over and above thyroid cartilage.

Reddy KSN et al,^[1] observed that ligature mark is situated above the level of thyroid cartilage, between larynx and chin in 80% of hanging cases, at the level of thyroid cartilage in about 15% cases and below the level of thyroid cartilage in about 5% cases. Naik SK et al found the ligature mark below the level of laryngeal prominence in 4.76% hanging cases and discontinuity of ligature mark was not noticed in 11.11% cases of suicidal hanging and 33.33% cases of homicidal hanging.^[10]

As per this study out of 59 hanging deaths, 36 (61%) cases, knot was on left side of neck, 17 (28.8%) cases knot was on back of neck, 4 (6.7%) cases, and knot was on right side of neck and 2 (3.3%) cases knot located below the chin. Polson CJ et al stated as suspension by a knot below the chin is rare.^[11] Dr. Madan Mohan noted that in 46% of hanging cases, the knot is on the side and in 4% cases on the back.^[12]

Among neck structure injuries, majority of hanging cases had rupture / contusion of sternocleidomastoid and other strap muscles of neck, it was 57.6%. 33.8% cases had carotid intimal tear, 5% cases showed hyoid bone fracture and 3.3% thyroid cartilage. No fractures noted in Cricoid cartilage and cervical vertebra in this study.

In complete hanging cases especially, contusion and rupture of platysma and sternocleidomastoid muscles can be noticed.^[6,13] Sivasuthan S et al noted 62% of cases with rupture of lower attachment of sternocleidomastoid muscle.^[14] Bhattacharji PK et al

did a retrospective study on 175 cases of suicidal hanging, documented sternocleidomastoid muscle is the one most frequently gets injured.^[15]

Tear of intima of carotid arteries is seen in 5-10% hanging cases,^[11,1] usually hyoid bone is intact in 80% of cases of hanging.^[16] Renjith et al reported out of 21 cases of hanging, 28.5% of hyoid bone fractures, all of them were males.^[17] In suicidal hanging cases, upper cervical vertebrae fracture occurs when the deceased jumps from a height and its fall is arrested by sudden jerk of a ligature.^[8] DiMaio et al did a study on 83 hanging cases, noted 10 cases (12%) had fractures, of which 9 were thyroid cartilage fracture, especially superior horns, one was cervical spine fracture and none were hyoid bone fracture.^[18]

CONCLUSION

Most of the hanging cases noted in younger age group, this may impose a socioeconomic burden on society. Social awareness, problem solving and family support of most common age group is extremely necessary. Better way of preventing hanging cases is by creating social awareness for their problems, employment facilities for youth, psychiatric counselling.

REFERENCES

- Reddy KSN. Mechanical asphyxia. The essentials of Forensic Medicine and Toxicology, 27th ed., Medical book company, Hyderabad. 2008, pp. 299-318.
- Richard S Snell. Clinical Anatomy by Regions- 8th ed., Wolters Kluwer (India), Pvt Ltd, New Delhi, 1993.
- Ajdaic Gross V, Weiss MG, Ring M, Hepp V, Bopp M, Gutzwiller F et al. Methods of suicide: International suicide patterns derived from the WHO mortality database. Bull World Health Organ. 2008;86:726-32.
- Ali E, Maksud M, Zubyra SJ, Hossain S Md, Debnath PR, Alam A, Chakrabarty PK. Suicide by hanging : study of 334 cases. Bangladesh Med J. 2014 May; 43 (2): 90-93.
- Glaister J, Rentoul E. Asphyxia, Medical Jurisprudence and Toxicology, 12th ed., E& S Livingstone, London. 1966, pp.166-187.
- Krishan Vij. Asphyxial deaths. Textbook of Forensic Medicine and Toxicology- Principles and practice, 3rd ed., Elsevier, 2008, pp. 179-202.
- Mukherjee JB. Violent Asphyxial Deaths. Forensic Medicine and Toxicology, Vol I Academic Publishers Calcutta, 1982, pp. 453-491.
- Modi JP. Deaths from asphyxia. Modi's Medical Jurisprudence and Toxicology, 23rd ed., edited by Dr. K. Mathiwaran, Prof Dr. Amrith Patnaik, Lexis Nexis Butterworths, 2006, pp. 565 – 590.
- Sharma BR, Harish D, Virendar Pal Singh, Preminderjeet Singh. Ligature mark on neck; How informative, a retrospective study of 95 deaths due to constriction of neck. JIAFM. 2005;27(1):10-15.
- Naik SK. Obliquity Vs. Discontinuity of ligature mark in diagnosis of hanging – a comparative study, Anil Agarwal's internet. Journal of Forensic Medicine and Toxicology. 2006 Jan-Jun;7(1).
- Polson CJ, Gee DJ, Knight B. Mechanical Asphyxia, The Essentials of Forensic Medicine, 4th ed., Pergamon Press, Oxford, 1985, pp. 351- 420.
- Madan Mohan A. A Study of death due to hanging (An analysis of fifty cases of hanging), Thesis submitted to University of Calicut, 1982.
- Parik CK. Violent Asphyxial Deaths. Parikh's Text book of Medical Jurisprudence Forensic Medicine and Toxicology – for classrooms and court rooms-, 6th ed., CBS publishers & distributors, New Delhi, 2007, pp. 3.40 – 3.56.
- Sivasuthan S. Sternomastoid Rupture an index of antemortem hanging- an autopsy study of 100 cases. Indian Internet J of Forensic Med. & Toxicol. 2005;3(4).
- Bhattacharji PK. Violent Asphyxia, Medicolegal Companion, 2nd ed., Aruna Publications, Lucknow. 1968, pp. 167-180.
- NageshKumar Rao. Asphyxial deaths. Textbook of Forensic Medicine and Toxicology, 1st ed., Jaypee brothers, New Delhi, 2000, pp.157-166.
- Renjith C. A PostMortem Study of one hundred Hyoid bones, Thesis submitted to university of Calicut, 1984.
- DiMaio VJ, DiMaio D. Asphyxia, Forensic Pathology, 2nd ed., CRC Press, London, 2001, pp 230-275.

How to cite this article: Sekhar VR, Dinesh G. Epidemiological Factors Assessment and Study on Neck Structures Injury in Hanging Deaths. Ann. Int. Med. Den. Res. 2019; 5(4):FM01-FM04.

Source of Support: Nil, **Conflict of Interest:** None declared