

Evaluation of Causes of Failures in Endodontic Treatment: A Clinical Study.

Niketa Gupta¹, Anshul Gupta²

¹Junior Resident, Department of Dentistry, S.P. Medical College, Bikaner, Rajasthan, India.

²Consultant Dental Surgeon, Bikaner, Rajasthan, India.

Received: March 2019

Accepted: March 2019

Copyright: © the author(s), publisher. It is an open-access article distributed under the terms of the Creative Commons Attribution Non-Commercial License, which permits unrestricted non-commercial use, distribution, and reproduction in any medium, provided the original work is properly cited.

ABSTRACT

Background: Endodontic treatment or root canal treatment is a treatment sequence for the infected pulp of a tooth which results in the elimination of infection and the protection of the decontaminated tooth from future microbial invasion. The present study was conducted to assess the causes of endodontic failures. **Methods:** The present study was conducted on 100 patients of both genders. A total 220 endodontic treated teeth were evaluated. Intraoral periapical (IOPA) radiograph was used for assessment of presence or absence of periapical radiolucency, quality of obturation, missed canal, dislodged/fractured restorations, iatrogenic problems: perforation, file separation, ledges etc. **Results:** Out of 100 patients, males were 40 and females were 60. The difference was non-significant (P<0.5). Common cause of failure was missed canal (maxilla- 40%, mandible- 45%), inadequate obturation (maxilla- 45%, mandible- 50%) and fractured coronal obturation (maxilla- 15%, mandible- 5%). The difference was significant (P<0.05). **Conclusion:** Endodontic failure is not uncommon phenomenon. Common causes are missed canal, inadequate obturation and fractured coronal obturation. Periodic evaluations of cases are required to prevent developing complications.

Keywords: Dislodged, Endodontic, Obturation.

INTRODUCTION

Endodontic treatment or root canal treatment is a treatment sequence for the infected pulp of a tooth which results in the elimination of infection and the protection of the decontaminated tooth from future microbial invasion. It is widely used phenomenon in cases of apical periodontitis, periapical abscess, granuloma and cysts. The effectiveness of the treatment depends upon the careful following of all steps such as access opening, biomechanical preparation, obturation and restoration.^[1]

Increased dental patient education and awareness in conjunction with technological advancements have helped to promote the view that dentition should remain throughout people's lives. As a result, the need for performing conventional non surgical root canal treatment also has increased dramatically. Endodontic treatment has failure rates also.^[2]

Endodontic treatment has failed if, after a sufficiently long period for healing, there is a residual, persistent, or progressive radiological translucency in periapical tissue. Furthermore, any

kind of clinical complaint is to be considered an appropriate criterion for unsuccessful root canal treatment. Endodontic failure still occurs for a variety of reasons, and presence of clinical signs and symptoms along with radiographic evidence of periapical bone destruction indicates the need for reintervention. The first and most important step is to determine the cause of endodontic failure. Normally, the etiologic factors of endodontic failure can be placed into four groups: (1) persistent or reintroduced intraradicular microorganism, (2) extraradicular infection, (3) foreign body reaction, and (4) true cysts.³ The present study was conducted to assess the causes of endodontic failures.

MATERIALS AND METHODS

The present study was conducted in the department of Dentistry. It included 100 patients of both genders. All were informed regarding the study and written consent was obtained. A total 220 endodontic treated teeth were evaluated. General information such as name, age, gender etc was noted. Intraoral periapical (IOPA) radiograph was used for assessment of presence or absence of periapical radiolucency, quality of obturation, missed canal, dislodged/fractured restorations, iatrogenic problems: perforation, file separation, ledges etc. Results thus obtained were subjected to

Name & Address of Corresponding Author

Dr. Anshul Gupta,
BDS, MDS,
Consultant Dental Surgeon,
Bikaner, Rajasthan, India.

statistical analysis using chi-square test. P value less than 0.05 was considered significant.

RESULTS

[Table 1] shows that out of 100 patients, males were 40 and females were 60. The difference was nonsignificant (P=0.5).

[Figure 1] shows that common cause of failure was missed canal (maxilla- 40%, mandible- 45%), inadequate obturation (maxilla- 45%, mandible- 50%) and fractured coronal obturation (maxilla- 15%, mandible- 5%). The difference was significant (P<0.05).

Table 1: Distribution of patients.

Total 100	
Male	Female
40	60

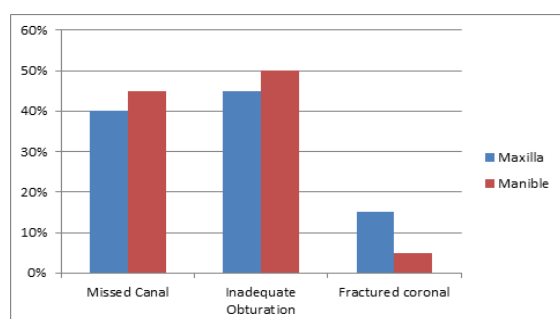


Figure 1: Causes of endodontic failures.

DISCUSSION

Endodontic failure related to microorganisms can be caused by anatomical difficulties such as apical ramification, isthmuses, and other morphologic irregularities as well as procedural errors such as missed canals, root perforation, ledge formation, and separated instruments. The quality of coronal restoration on favorable outcome of non surgical root canal treatment has been studied upon and has been established. According to the literature, failure to place an adequate coronal restoration results in a lower success rate. Based on the causes of failure decision is made by the clinician among nonsurgical endodontic re treatment, surgical treatment or extraction.^[4] The most frequent causes of endodontic treatment failure include insufficient apical obturation, insufficient coronal obturation, insufficient disinfection of the root canal, specific microbial infection, protracted course of treatment, excessive use of instruments/excessive filling/false route. In present study, out of 100 patients, males were 40 and females were 60. This is in agreement with Vertussi et al.^[5] We found that common cause of failure was missed canal, inadequate obturation and fractured coronal obturation. This is similar to Wolkot et al.^[6] Instruments may break during root canal treatment. The file segment may be left behind if an acceptable level of cleaning and

shaping has already been completed and attempting to remove the segment would risk damage to the tooth. While potentially disconcerting to the patient, having metal inside of a tooth is relatively common, such as with metal posts, amalgam fillings, gold crowns, and porcelain fused to metal crowns. The occurrence of file separation is proportional to the narrowness, curvature, length, calcification and number of roots on the tooth being treated. Complications resulting from incompletely cleaned canals, due to blockage from the separated file, can be addressed with surgical root canal treatment.^[7] Another common complication of root canal treatment is when the entire length of the root canal is not completely cleaned out and obturated with root canal filling material (usually gutta percha). The X-ray in the right margin shows two adjacent teeth that had received bad root canal treatment. The root canal filling material does not extend to the end of the tooth roots. The dark circles at the bottom of the tooth roots indicated infection in the surrounding bone.^[8] Commonly found inadequacy was under obturation most frequently in curved canal cases. This may be due inadequate attention to preoperative radiograph and also less attention given to negotiate the curved canal. Due to inability to develop apical stop over obturation and over extension was found. Correct determination of working length and maintaining the length throughout the procedures cannot be less emphasized. Single cone 2% gutta percha was found to be used for obturation led to failure due to inadequate sealing of the root canal. This emphasizes the need of adequate shaping and cleaning while maintaining the proper working length followed by adequate obturation for proper sealing of the apex which leads to successful healing.^[9]

CONCLUSION

Endodontic failure is not uncommon phenomenon. Common causes are missed canal, inadequate obturation and fractured coronal obturation. Periodic evaluations of cases are required to prevent developing complications.

REFERENCES

1. Nair R. Pathology of apical periodontitis. In: Orstavik D, Pitt Ford TR, eds. Essential Endodontology: Prevention and Treatment of Apical Periodontitis, 2nd ed. Boston, MA: Blackwell Science 2008: 68-88.
2. Lin LM, Skrinber JE, Gaengler P. Factors associated with endodontic treatment failures. J Endo 1992; 18: 625-7.
3. Lazarski MP, Walker WA 3rd, Flores CM, Schindler WG, Hargreaves KM. Epidemiological evaluation of the outcomes of nonsurgical root canal treatment in a large cohort of insured dental patient. J Endod 2001; 27: 791-6.
4. Friedman S, Abitbol S, Lawrence HP. Treatment outcome in endodontics: The Toronto Study. Phase 1: Initial treatment. J Endod 2003; 29: 787-93.

5. Vertucci FJ. Root canal anatomy of the human permanent teeth. *Oral Surg Oral Med Oral Pathol Oral Radiol Endod* 1984;58: 589-99.
6. Wolcott J, Ishley D, Kennedy W, Johnson S, Minnich S. Clinical investigation of second mesiobuccal canals in endodontically treated and retreated maxillary molars. *J Endod* 2002; 28: 477- 9.
7. Lynch CD, Burke FM, Ni Riordain R, Hannigan A. The influence of coronal restoration type on survival of endodontically treated teeth. *Eur J Prosthodont Restor Dent* 2004; 12: 171-6.
8. Mindola MJ, Mickel AK, Sami C, Jones JJ, Lalumandier JA, Nelson SS. Endodontic treatment in an American Indian population: A 10-year retrospective study. *J Endod* 2006; 32: 828-32.
9. Abbott PV. Recognition and prevention of failures in clinical dentistry, endodontics. *Ann R Australas Coll Dent Surg* 1991; 11: 150-66.

How to cite this article: Gupta N, Gupta A. Evaluation of Causes of Failures in Endodontic Treatment: A Clinical Study. *Ann. Int. Med. Den. Res.* 2019; 5(3):DE71-DE73.

Source of Support: Nil, **Conflict of Interest:** None declared