

# Determination of Thickness of Palatal Masticatory Mucosa Using Cone Beam Computerized Tomography and Direct Bone Sounding: A Clinico-Radiographic Study.

Rashidat Ul Khairat<sup>1\*</sup>, Suhail Majid Jan<sup>2</sup>, Roobal Behal<sup>3</sup>, Beanish Bashir<sup>1</sup>

<sup>1</sup>MDS, Department of Periodontics, GDC, Srinagar.

<sup>2</sup>Professor and HOD, Department of Periodontics, GDC, Srinagar.

<sup>3</sup>Assistant Professor, Department of Periodontics, GDC, Srinagar.

Received: May 2019

Accepted: June 2019

**Copyright:** © the author(s), publisher. It is an open-access article distributed under the terms of the Creative Commons Attribution Non-Commercial License, which permits unrestricted non-commercial use, distribution, and reproduction in any medium, provided the original work is properly cited.

## ABSTRACT

**Background:** Palatal masticatory mucosa is the main donor site for soft tissue grafts, thus determination of its thickness is of paramount importance as it affects the surgical outcome. Thus in this study we tried to evaluate and compare the mean thickness of palatal masticatory mucosa with the help of direct bone sounding using a periodontal probe and cone beam computerized tomography (CBCT) at different regions. **Methods:** 30 subjects in the age group of 20-50years were included in this study and had to undergo bone sounding with periodontal probe and subsequently cone beam computerized tomography in relation to canine, 1st premolar, 2nd premolar, 1st molar and 2nd molar at four different points, i.e., 2, 5, 8 and 12 mm from the gingival margin. **Results:** On comparison between the two techniques non-significant difference was found with slightly higher values obtained by CBCT. The tissue at the premolars was thicker than that measured at the molars. There was also increase in tissue thickness as the distance from gingival margin was increased except for canine at the depth of 12mm. **Conclusion:** It was concluded that CBCT can be used as non-invasive and accurate method to determine the soft tissue thickness of the palatal masticatory mucosa than clinical measurements made via bone-sounding.

**Keywords:** Bone sounding, Cone-beam computerized tomography, Different depths, Gingival margin, Palatal masticatory mucosa.

## INTRODUCTION

Periodontal plastic surgery, a term originally proposed by Miller,<sup>[1]</sup> fulfils the esthetic and functional demands of patients. The autogenous soft tissue donor sites used in periodontal plastic surgery include palatal masticatory mucosa or maxillary tuberosity area. Palatal masticatory mucosa, the main donor area for soft tissue grafts is applied for increasing the dimensions of keratinized mucosa around teeth and implants, covering exposed roots, and increasing localized alveolar ridge thickness.<sup>[2]</sup> Proper thickness of graft material is important for survival to permit nutrient supply from the recipient site. The graft obtained if too thin can shrink and undergo necrosis,<sup>[3,4]</sup> and if it is too thick, its peripheral layer is jeopardized due to excessive tissue separating it from new circulation and nutrients. Hence the thickness of the graft tissue

obtained is an important factor for the success of these techniques.

A critical aspect in the treatment planning of these situations is the determination of the thickness of the graft donor tissue, as the thickness of tissue grafted from the palate to the recipient site directly affects the surgical outcome.<sup>[5,6]</sup> Pre-surgical assessment of the thickness of the donor area is greatly overlooked due to a lack of reliable methods for this purpose. There are various invasive and non-invasive methods of mucosal thickness evaluation. The various invasive methods include direct bone sounding using a periodontal probe,<sup>[7,8]</sup> an endodontic reamer, or an injection needle after local anesthesia,<sup>[9]</sup> histologic measurements of the tissue obtained<sup>[10]</sup> and measurements from cadavers.<sup>[11]</sup> Assessment of thickness of palatal mucosa by periodontal probe, is commonly performed immediately prior to surgery as the patient has to be anaesthetized and may hinder appropriate treatment planning of the procedure as the clinician may find that there is not sufficient tissue thickness in the pre-anaesthetized area thus not allowing a precise pre-surgical planning of the procedure.<sup>[12]</sup>

### Name & Address of Corresponding Author

Dr Rashidat-ul-Khairat  
Post Graduate Scholar,  
Department of Periodontics,  
Govt. Dental College,  
Astan Pora, Rawalpura,  
Srinagar, J & K, India.

Indirect measurement methods, such as ultrasonography,<sup>[13]</sup> computed tomography (CT),<sup>[14]</sup> and recently cone-beam computed tomography (CBCT),<sup>[12]</sup> have also been used for assessment of palatal mucosa thickness. Cone-beam computed tomography (CBCT) is a new diagnostic tool that has revolutionized diagnosis and treatment planning in the dental field.<sup>[15]</sup>

In addition to accurately reproducing linear dental measurements,<sup>[16]</sup> data obtained from CBCT scans may indeed be more accurate than that obtained from bone - sounding, as pressure from a periodontal probe or needle may cause tissue distortion during bone - sounding.<sup>[14]</sup>

Thus in this study we tried to evaluate the thickness of palatal masticatory mucosa at various sites by the help of direct bone sounding using a periodontal probe and cone beam computerized tomography for precise treatment planning.

## MATERIALS AND METHODS

30 subjects comprising of both the sexes, visiting outpatient Department of Periodontology, Govt. Dental College and Hospital Srinagar, were considered for the present clinical study after meeting inclusion and exclusion criteria. The criteria for inclusion in the study were systemically healthy subjects with age ranging between 20 - 50 years and having all maxillary teeth, except the third molars. Subjects having undergone surgery in the area to be analysed, history or presence of pathology in the palatal region, teeth with severe morphological alterations, tooth mal-alignment, bone or gingival loss, pregnant women or lactating mothers and smokers were excluded.

After fulfillment of inclusion criteria for the study, informed consents were obtained from all the patients. A maxillary impression was made with alginate impression material and poured in a dental stone. Acrylic measurement guides were then fabricated on the cast model and trimmed appropriately to include all teeth present in the arch. Each stent was completely tooth-borne to prevent movement during measurements. Using a standardized UNC probe, measurements were made at distances of 2 mm, 5 mm, 8 mm and 12 mm from the gingival margin for canine, first and second premolar, first molar and second molar on the right and left side of the palatal mucosa. A hole was punctured through the acrylic stent at each measurement point. The greater palatine and incisive nerves were blocked with 2% lidocaine, 1:100,000 epinephrine injection. The measurement points were marked with a hematoxylin pencil on the palate, through the holes made in the acrylic stent. Measurements were performed 20 minutes after the injection by bone sounding with William's periodontal probe. The values were rounded up to the nearest 0.5mm. After bone sounding, gutta-

percha was used to fill each measurement site as a radio-opaque marker on the CBCT scan.

Next day, CBCT scans were performed with the NewTom GAINO unit (QR Srl Verona, Italy) and the images were acquired by means of the NewTom software and processed by a computer. At the time of the CBCT scans, the patient's head and chin was stabilized. The acrylic stent with gutta-percha was placed in patient's mouth and asked to bite a wooden spatula placed across the mouth at the level of the maxillary and mandibular molars (first and second molars) to separate them and to prevent the tongue from touching the soft and hard palates during image acquisition. Acquisition was performed in the maxilla for 30 seconds with NewTom tomography acquisition protocol: voxel size: 75µm; Grey scale:16 bits; focal spot:1 mm; image detector: amorphous silicon flat panel; image acquisition: single 360 ° rotation.

## Statistical Analysis

Statistical Software SPSS (Version 20.0) and Graphpad Prim (version 5.00) were used to carry out the statistical analysis of data. Data was expressed as Mean  $\pm$  SD and presented by Bar diagrams. Student's independent t-test was used to compare clinical measurements with radiographic measurements of palatal mucosa thickness. Analysis of Variance (ANOVA) test was employed to compare average thickness of palatal mucosa at various depths using either clinical or radiographic technique.

## RESULTS

[Table 1 & Figure 1] shows the comparison between the thickness measurements of palatal mucosa obtained by bone sounding via periodontal probe (clinical technique) and cone beam computerized tomography (radiographic technique) in relation to canine, first premolar, second premolar, first molar and second molar at various depths of 2 mm, 5 mm, 8 mm, and 12 mm from gingival margin. Statistical analysis of the data obtained by the two techniques did not reveal any statistically significant difference (p- value >0.05).

[Table 2 & Figure 2] shows the comparison between the mean thickness measurements obtained by bone sounding via periodontal probe (clinical technique) and cone beam computerized tomography (radiographic technique) in relation to canine, first premolar, second premolar, first molar and second molar. Statistical analysis of the data obtained by the two techniques did not reveal any statistically significant difference (p- value >0.05).

[Table 3 & Figure 3] shows the thickness measurements of palatal mucosa obtained by bone sounding via periodontal probe (clinical technique) in relation to canine, first premolar, second premolar, first molar and second molar at various depths of 2

mm, 5 mm, 8 mm and 12 mm from gingival margin. Statistically significant difference was seen in relation to various depths from gingival margin for each tooth. The p-value of 0.005 in relation to canine and p-value of 0.001 in relation to premolars and molars was seen.

[Table 4 & Figure 4] shows the thickness measurements of palatal mucosa obtained by cone beam computerized tomography (radiographic

technique) in relation to canine, first premolar, second premolar, first molar and second molar at various depths of 2 mm, 5 mm, 8 mm and 12 mm from gingival margin. Statistically significant difference was seen in relation to various depths from gingival margin for each tooth. The p-value of 0.003 in relation to canine and p-value of 0.001 in relation to premolars and molars was seen.

**Table 1: Comparison of thickness measurements of palatal mucosa at various depths obtained by Clinical and Radiographic techniques.**

Mean Distance From Gingival Margin (mm)	Clinical		Radiographic		P-value@	Significance	
	Mean	SD	Mean	SD			
Canine	2	1.98	0.404	2.01	0.296	0.772	NS
	5	2.97	0.434	3.11	0.363	0.171	NS
	8	3.45	0.514	3.64	0.428	0.119	NS
	12	3.18	0.609	3.29	0.481	0.469	NS
1st Pre-molar	2	2.05	0.379	2.19	0.363	0.149	NS
	5	3.15	0.375	3.32	0.330	0.062	NS
	8	3.82	0.382	3.94	0.367	0.208	NS
	12	4.22	0.449	4.34	0.366	0.248	NS
2nd Pre-molar	2	2.12	0.429	2.20	0.265	0.389	NS
	5	3.13	0.490	3.27	0.288	0.193	NS
	8	3.98	0.425	4.14	0.276	0.103	NS
	12	4.45	0.480	4.58	0.332	0.227	NS
1st Molar	2	1.98	0.359	2.05	0.237	0.399	NS
	5	2.12	0.364	2.21	0.290	0.276	NS
	8	2.87	0.454	2.97	0.329	0.317	NS
	12	4.37	0.472	4.54	0.309	0.098	NS
2nd Molar	2	2.15	0.438	2.12	0.416	0.787	NS
	5	2.42	0.417	2.44	0.436	0.857	NS
	8	3.32	0.404	3.39	0.462	0.496	NS
	12	5.62	0.364	5.75	0.422	0.184	NS

NS: Not Significant, @P-value by Student's Independent t-test

**Table 2: Comparison of mean thickness measurements of palatal mucosa obtained by Clinical and Radiographic techniques**

Variable	Clinical		Radiographic		P-value@	Significance
	Mean	SD	Mean	SD		
Canine	2.90	0.402	3.01	0.341	0.229	NS
1st Premolar	3.31	0.314	3.45	0.298	0.079	NS
2nd Premolar	3.42	0.388	3.55	0.214	0.126	NS
1st Molar	2.83	0.351	2.94	0.241	0.161	NS
2nd Molar	3.38	0.265	3.47	0.382	0.558	NS

NS: Not Significant, @P-value by Student's Independent t-test

**Table 3: Showing thickness of palatal mucosa at various depths using clinical technique**

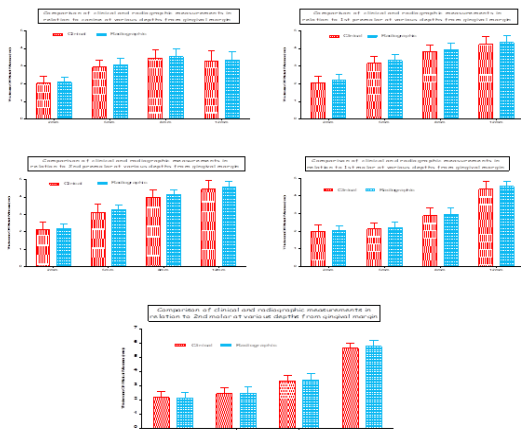
Mean Distance From Gingival Margin (mm)	Mean	SD	P-value@
Canine	2	1.98	0.005*
	5	2.97	
	8	3.45	
	12	3.18	
1st Pre-molar	2	2.05	<0.001*
	5	3.15	
	8	3.82	
	12	4.22	
2nd Pre-molar	2	2.12	<0.001*
	5	3.13	
	8	3.98	
	12	4.45	
1st Molar	2	1.98	<0.001*
	5	2.12	
	8	2.87	
	12	4.37	
2nd Molar	2	2.15	<0.001*
	5	2.42	
	8	3.32	
	12	5.62	

\*Statistically significant difference (P-value<0.05);@P-value by ANOVA

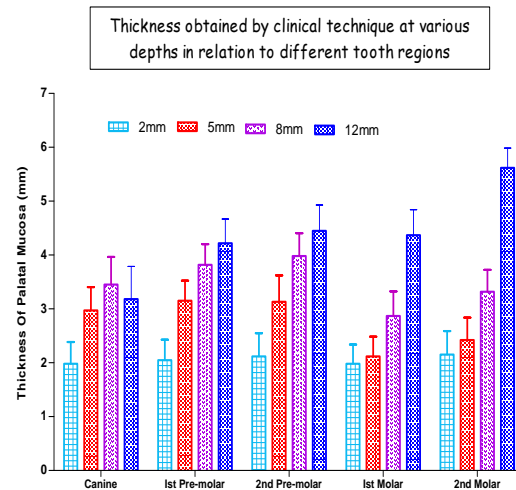
**Table 4: Showing thickness of palatal mucosa at various depths using radiographic technique**

Mean Distance From Gingival Margin (mm)	Mean	SD	P-value@
Canine	2	2.01	0.003*
	5	3.11	
	8	3.64	
	12	3.29	
1st Pre-molar	2	2.19	<0.001*
	5	3.32	
	8	3.94	
	12	4.34	
2nd Pre-molar	2	2.20	<0.001*
	5	3.27	
	8	4.14	
	12	4.58	
1st Molar	2	2.05	<0.001*
	5	2.21	
	8	2.97	
	12	4.54	
2nd Molar	2	2.12	<0.001*
	5	2.44	
	8	3.39	
	12	5.75	

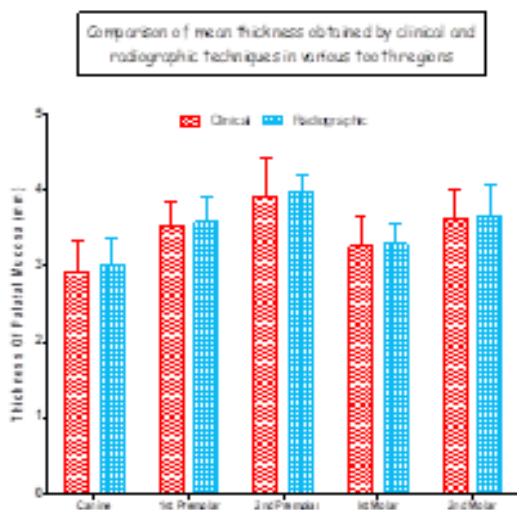
\*Statistically significant difference (P-value<0.05); @P-value by ANOVA



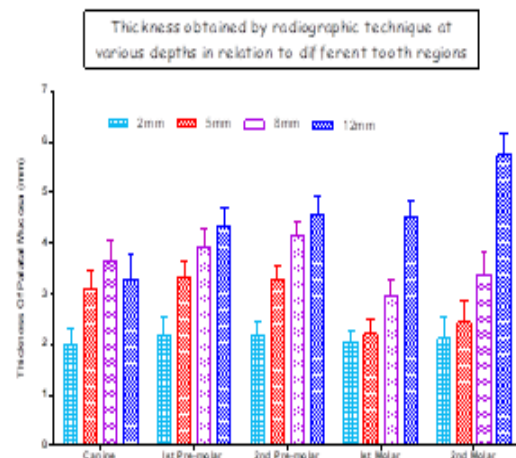
**Figure 1: Comparison of thickness obtained by clinical and radiographic methods in relation to different tooth regions**



**Figure 3: Palatal thickness obtained by clinical method in relation to different tooth regions at various depths.**



**Figure 2: Comparison of mean thickness by clinical and radiographic methods in relation to different tooth regions**



**Figure 4: Palatal thickness obtained by radiographic method in relation to different tooth regions at various depths.**

## DISCUSSION

Assessment of the thickness of palatal masticatory mucosa aids in a better pre-operative diagnosis and treatment planning. Taking into account the usefulness of the palatal mucosa in periodontal plastic procedures and implant therapy, it is quite evident that this tissue holds a prominent position in the current era of soft tissue aesthetics in dentistry.<sup>[17]</sup> As palatal masticatory mucosa is the main donor site of connective tissue in periodontal plastic surgery during soft tissue grafting,<sup>[18]</sup> it sometimes fails to provide adequate donor tissue, either as a result of palatal anatomic form or insufficient thickness of the soft tissue leading to alteration in surgical approach. Since its dimensions play an important role in the clinical outcomes of periodontal plastic surgical procedures, it is important to determine the available dimensions of the palatal donor tissues, prior to attempting surgical harvesting.<sup>[19]</sup>

The thickness of the palatal masticatory mucosa has been evaluated in different studies. Palatal mucosal thickness has been measured using direct and indirect methods.<sup>[13,20-22]</sup> The direct method including transgingival sounding is cost effective and easy to perform.<sup>[23]</sup> However, it may be uncomfortable for the patient because it has to be performed under local anesthesia.<sup>[5,20]</sup> The measurements are rounded off to the nearest millimeter, affected by volume of local anesthetic and inflammation.<sup>[14,20]</sup> In addition, these procedures are performed immediately before graft harvesting, and as a result, pre-surgical planning cannot be done.<sup>[12]</sup> There occurs tissue displacement during probing and probing against the palate could influence the measurement.<sup>[14]</sup>

A non-invasive method that applies an ultrasonic device has also been described that is more comfortable for patients,<sup>[13,21,22]</sup> non-invasive and easily applicable, but is technique sensitive, has low reproducibility, and has limitations in sites with a palatal vault depth >6 mm. Therefore affected by the anatomic form of the palate repeated measurements are needed to resolve these problems.<sup>[21,24]</sup>

None of the techniques reported so far produce an image of the hard and soft tissues including the palatal mucosa. As an alternative to existing methods, the tooth, gingiva, and other periodontal tissues may be imaged by CT and CBCT.<sup>[12,14,25]</sup>

CBCT is a simple technique that has several applications in dentistry. It is a quantitative method, because the differences between the epithelial, fat and connective tissues cannot be seen on the images. Furthermore, an inflamed gingiva would have a similar appearance as a healthy gingiva on the images acquired by CBCT.<sup>[12]</sup>

CBCT presents advantages such as more focused beam, better image quality, greater comfort for the patient and lower cost. CBCT scans have been

shown to accurately reproduce linear dental measurements.<sup>[26]</sup>

Barriviera, et al.<sup>[12]</sup> has described a technique using CBCT that accurately visualized the dimensions of the palatal masticatory mucosa, thus enabling the clinician to make linear measurements of the soft tissue covering the palate. The images obtained reveals a high-quality image of hard (teeth and bone) and soft (facial and palatal gingiva) tissues and allows measurements of the dimensions and relationships of these structures. The clinical significance of this finding was that CBCT scans may be useful in the treatment planning of cases where the thickness of the palatal tissue is paramount.

CBCT scans used in this study provides the possibility of evaluating both sides of the maxilla in the same image, thus allowing the dentist with options to choose the side he/she thinks is the best donor area.

In the present study we tried to evaluate the mean thickness of palatal masticatory mucosa with the help of bone sounding by periodontal probe and cone beam computerized tomography. The mean thickness determined by bone sounding and cone beam computerized tomography in relation to canine was 2.90 mm and 3.01mm, 1st premolar was 3.31 mm and 3.45 mm, 2nd premolar was 3.42 mm and 3.55 mm, 1st molar was 2.83 mm and 2.94mm and 2nd molar was 3.38 mm and 3.47mm respectively. These results are in agreement with the results of previous studies of Studer et al 1997,<sup>[20]</sup> Muller et al 1999,<sup>[21]</sup> 2000,<sup>[22]</sup> Wara-aswapati et al. 200,<sup>[5]</sup> and Barriviera et al. 2009.<sup>[12]</sup>

The reason for the variation in thickness may be due to that the larger parts of the mucosa of the hard palate contain a submucosa. Whereas near the palatal raphe mediana and within the gingival portions the firm lamina propria passes directly into the periosteum of the bony palatal roof, on both sides of the raphe, the lamina propria is thin and continues into a submucosa containing various amounts of adipose tissue and small mucous glands.<sup>[27]</sup>

In this study we tried to determine the actual thickness of the soft tissue in different palatal locations of 2 mm, 5 mm, 8 mm and 12 mm from gingival margin using clinical and radiographic method in relation to canine, 1st premolar, 2nd premolar, 1st molar and 2nd molar. The results of this study showed that the tissue became thicker as the distance from the tooth increased except for the canine in relation to the distance at 12 mm in both radiographic and clinical technique. This was in agreement to the results with the studies of Barriviera et al. 2009,<sup>[12]</sup> and Song et al 2008.<sup>[14]</sup>

These variations may be due to the fact that the palatal mucosa is composed of keratinized stratified squamous epithelium, the lamina propria (dense connective tissue); and the submucosa layer (composed of glandular and adipose tissues).<sup>[28]</sup> In



the anterior region the hard palate constitutes of the mucoperiosteum. Near the palatal raphe mediana and the gingival parts of the palatal mucosa, the firm lamina propria extends directly into the periosteum of the palatal roof.<sup>[29]</sup>

In this study the tissue measured at the premolars was thicker than that measured at the molars. This was in agreement with Studer, et al.1997,<sup>[20]</sup> Muller, et al.2000.<sup>[22]</sup>

This may be due to the protuberance of the palatal root of maxillary 1st molar<sup>[23]</sup> thus acting as an anatomic barrier<sup>[20]</sup> and in the premolar region the connective tissue mainly contains adipose tissue, ie, pars corporis adiposa of the hard palate, extending to the plane of the premolars.<sup>[29]</sup>

In this study we compared the thickness of the palatal masticatory mucosa as determined from a CBCT scan to that by bone sounding technique via periodontal probe. In the present study, non-significant difference was found between measurements determined by the two techniques . These results are in agreement to the results of Gupta P, et al 2015.<sup>[30]</sup> The results obtained by CBCT have slightly higher value than that obtained by bone sounding though non - significant. The results obtained by CBCT are more precise and there may be inter-examination variation in relation to bone sounding by periodontal probe.

## CONCLUSION

Thus it can be concluded that CBCT can be used as reliable, simple, non-invasive, alternative and accurate reproducible method to determine the soft tissue thickness of the palatal masticatory mucosa than bone-sounding that could help in planning dental treatment procedures especially in Periodontics, Implant dentistry and Oral surgery. The tissue measured at the premolars was thicker than that measured at the molars.

## REFERENCES

1. Miller PD Jr. Regenerative and reconstructive periodontal plastic surgery. *Dent Clin North Am* 1988; 32:287-306.
2. Wennstrom JL & Pini Prato GP. (2003) Mucogingival therapy – periodontal plastic surgery. In: Lindhe, J, Karring, T & Lang, NP (eds). *Clinical Periodontology and Implant Dentistry*, 4th edition, pp. 576–631. Oxford,UK: Blackwell Munksgard
3. Mormann W, Schaer F, Firestone AG. The relationship between success of free gingival grafts and transplant thickness. *J Periodontol* 1981;52:74.
4. Pennel BM, Tabor JC , King KO, et al : Free masticatory mucosa graft. *J Periodontol* 1969;40:162.
5. Wara-aswapati N,Pitiphat W, Chandrapho N, Rattanayatikul C, Karimbux N. Thickness of palatal masticatory mucosa associated with age. *J Periodontol*. 2001 Oct 1;72(10):1407-12.
6. Ueno D, Sato J, Igarashi C, Ikeda S, Morita M, Shimoda S, et al. Accuracy of oral mucosal thickness measurements using spiral computed tomography. *J Periodontol*. 2011 Jun; 82 (6) : 829-36.

7. Greenberg J, Laster L, Listgarten MA. Transgingival probing as a potential estimator of alveolar bone level. *J Periodontol* 1976;47, 514–7.
8. Wolf HF, Rateitschak EM, Rateitschak KH, Hassell TM. (2004) *Color Atlas of Dental Medicine-Periodontology*, 3rd edition. Stuttgart, Germany: Thieme
9. Hamdan Alghamdi, Nadir Babay, Anil Sukumaran. Surgical management of gingival recession: A clinical update. *The Saudi Dental Journal* (2009) 21, 83-94
10. Ostlund SG. The effect of complete dentures on the gum tissue: A histological and histopathological investigation. *Acta Odontol Scand* 1958;16:1-40.
11. Kim HJ, Yun HS, Park HD, Kim DH, Park YC. Soft-tissue and cortical-bone thickness at orthodontic implant sites. *American journal of orthodontics and dentofacial orthopedics*. 2006 Aug 31;130(2):177-82.
12. Barriviera M, Duarte WR, Januario AL, Faber J, Bezerra AC. A new method to assess and measure palatal masticatory mucosa by cone- beam computerized tomography. *J Clin Periodontol*. 2009 Jul 1;36(7):564-8.
13. Eger T, Muller HP, Heinecke A. Ultrasonic determination of gingival thickness. *J Clin Periodontol*. 1996 Sep 1;23(9): 839-45.
14. Song JE, Um YJ, Kim CS, Choi SH, Cho KS, Kim CK, et al. Thickness of posterior palatal masticatory mucosa: the use of computerized tomography. *J Periodontol*. 2008 Mar;79(3):406-12.
15. Jaju PP, Jaju SP. Clinical utility of dental cone-beam computed tomography: current perspectives. *Clinical, Cosmetic and Investigational Dentistry* 2014, 6:29-43
16. Kobayashi K, Shimoda S, Nakagawa Y, Yamamoto A. Accuracy in measurement of distance using limited cone-beam computerized tomography. *Int J Oral Maxillofac Implants* 2004; 19: 228-31.
17. Rajpoot N, Nayak A, Bankur PK. Evaluation of variation in the palatal gingival biotypes using an ultrasound device. *J Clin Diagn Res*. 2015 Mar 1;9.
18. Zuhr O, Baumer D, Hurzeler M. The addition of soft tissue replacement grafts in plastic periodontal and implant surgery: critical elements in design and execution. *J Clinical Periodontol*. 2014;41 (Suppl 15): S123-42.
19. Ramesh KS, Swetha P, Krishnan V, Mythili R, Rama Krishna Alla MD. Assessment of Thickness of Palatal Masticatory Mucosa and Maximum Graft Dimensions at Palatal Vault Associated with Age and Gender—A Clinical Study. *Journal of clinical and diagnostic research: JCDR*. 2014 May;8(5):ZC09
20. Studer SP, Allen EP, Rees TC, Kouba A. The thickness of masticatory mucosa in the human hard palate and tuberosity as potential donor sites for ridge augmentation procedures. *J Periodontol*. 1997 Feb ; 68(2) : 145-51.
21. Muller HP, Schaller N, Eger T. Ultrasonic determination of thickness of masticatory mucosa: a methodologic study. *Oral Surgery, Oral Medicine, Oral Pathology, and Endodontology*. 1999 Aug 31;88(2):248-53.
22. Muller HP, Schaller N, Eger T, Heinecke A. Thickness of masticatory mucosa. *J Clin Periodontol*. 2000 Jun 1;27(6): 431-6.
23. Stipetic J, Hrala Z, Celebic A. Thickness of masticatory mucosa in the human hard palate and tuberosity dependent on gender and body mass index. *Collegium antropologicum*. 2005 Jun 15;29(1):243-7.
24. Lawson RB, Jones ML. An evaluation of a noninvasive method of assessing alveolar bone levels in an experimental model of cleft lip and palate. *Cleft Palate Craniofac J* 1998; 35:1-8.
25. Ueno D, Sekiguchi R, Morita M, Jayawardena A, Shinpo S, Sato J, et al. Palatal mucosal measurements in a Japanese population using cone-beam computed tomography. *Journal of Esthetic and Restorative Dentistry*. 2014 Jan 1;26(1):48-58.
26. Baumgaertel S, Palomo JM, Palomo L, Hans MG. Reliability and accuracy of cone-beam computed tomography dental

- measurements. Am J Orthod Dentofacial Orthop 2009;136:19-25.
27. Schroeder HE. (1991) Oral structural biology, pp. 350–370. New York: Georg ThiemeVerlag.
  28. Nanci A. Ten cate's oral histology: development, structure, and function. 6th ed. Seoul: Daehan Publishing Co.; 2005. p.333-76.
  29. Muller HP, Eger T. Masticatory mucosa and periodontal phenotype: a review. Int J Periodont Restor Dent. 2002 Apr 1;22(2).
  30. Gupta P, Jan SM, Behal R, Mir RA, Shafi M. Accuracy of cone-beam computerized tomography in determining the thickness of palatal masticatory mucosa. Journal of Indian Society of Periodontology. 2015 Jul;19(4):396.

**How to cite this article:** Khairat RU, Jan SM, Behal R, Bashir B. Determination of Thickness of Palatal Masticatory Mucosa Using Cone Beam Computerized Tomography and Direct Bone Sounding: A Clinico-Radiographic Study. Ann. Int. Med. Den. Res. 2019; 5(4):DE49-DE55.

**Source of Support:** Nil, **Conflict of Interest:** None declared