

Ruptured Scrotum and Gangrenous Testis in a Newborn Ending up in Orchidectomy after Vaginal Breech Delivery: A Case Report

Rohit Thakur¹, Arvind Bhatia², Saloni Sood³, Rajesh Chaudhary⁴, Ragini Bhatia⁵, Gaurav R Kumar⁶

¹MS, General Surgeon, Department Of Surgery, Pandit Jawahar Lal Nehru Government Medical College, Chamba, HP, India.

² MS, General Surgeon, Department Of Surgery, Pandit Jawahar Lal Nehru Government Medical College, Chamba, HP, India.

³Assistant Professor, Department Of Anaesthesia, Pandit Jawahar Lal Nehru Government Medical College, Chamba, HP, India

⁴General Surgeon, Department Of Surgery, Civil Hospital Nagrota Bagwan, HP, India.

⁵BDS, MPH, Indian Institute of Public Health, Gandhinagar, Gujarat, India.

⁶Junior Resident, Department Of Surgery, Dr. RP Govt. Medical College Kangra at Tanda HP, India.

Received: June 2020

Accepted: June 2020

ABSTRACT

Testicular injuries are the rarest form of birth injuries suffered during the vaginal breech deliveries. Presenting breech pressing against the dilating cervix can lead to edema of the scrotum and buttocks, thus making the breech extraction difficult and prone to injuries. We report here the case of a newborn male borne after prolonged labor through the vaginal breech delivery. The scrotum was ruptured, and the left testicle was gangrenous, showing no blood flow on USG Doppler of the scrotum; hence orchidectomy was done. Very few case reports of testicular loss at birth are there in literature. Elective cesarean section can surely prevent this complication.

Keywords: Birth injuries, Castration. Testicular injuries, Vaginal breech birth.

INTRODUCTION

Birth trauma is the mechanical injury suffered by a fetus during the whole process of delivery. The incidence of birth trauma has decreased significantly over the last 50 years, but it is still a cause of concern and litigation these days. The prevalence of birth trauma from India is reported to be 3.2/ 1000 live births, while from the USA it's been reported as 0.2-37/1000 live births.[1] The significant birth trauma causing the neonatal death or leaving permanent damage to the neonate is very less. Less than 2% of neonatal deaths are accounted for birth trauma these days.[2]. About 3-4% of all the deliveries are breech deliveries.[3] Vaginal Breech Birth (VBB) is a cause of significant birth trauma. Although birth injuries can occur with spontaneous, full-term vaginal deliveries, they are two times more common during the VBB.[4] Common birth injuries are:

Fractures: clavicle, long bones, and skull, cephalohematoma.

Neurological injuries: an injury to the brachial plexus, facial nerve, phrenic nerve, and spinal cord.

Intracranial trauma: subdural hemorrhage, subarachnoid hemorrhage, and intracranial

hemorrhage.

Solid abdominal organ injuries: can occur to liver, spleen, adrenals, and kidneys.

Genitourinary injuries: injuries to the scrotum, penis, and testes are seen in males while labial hematomas, necrosis, and perineal tears are seen in females.

Testicular injuries are extremely low down in the birth injuries. There are very few case reports of neonates born with ruptured scrotum, and testicular gangrene, leading to testicular loss.

CASE REPORT

We present the case of a 21-year-old primigravida. She was being brought to the Pandit Jawahar Lal Nehru Government Medical College Chamba, by the ambulance from about 100 Km away. It was about a 3 hours drive through the hilly roads. She delivered a baby boy through vaginal breech delivery in the ambulance while on her way to the hospital. When she reached the hospital, the baby was 2700 grams, otherwise healthy except, bruised, edematous & ruptured scrotum with edematous penis, exposed bilateral testes, and gangrenous left testicle [Figure 1]. Ultrasonogram (USG) doppler study of the scrotum revealed a healthy right testicle but no blood flow to the left testicle. So the baby was taken up for emergency surgery where left orchidectomy, and repair of the ruptured hemi-scrotum was performed. Mother and baby made an excellent recovery and were discharged on day four of admission. After one month, the scrotal wound has healed well [Figure 2].

Name & Address of Corresponding Author

Dr. Rajesh Chaudhary,
MS, Senior Resident,
Department Of Surgery,
Dr. RP Govt. Medical College Kangra at Tanda
HP, India.

The USG scrotum was repeated and showed normal-sized right testes with normal blood flow on Doppler study. [Figure 3]

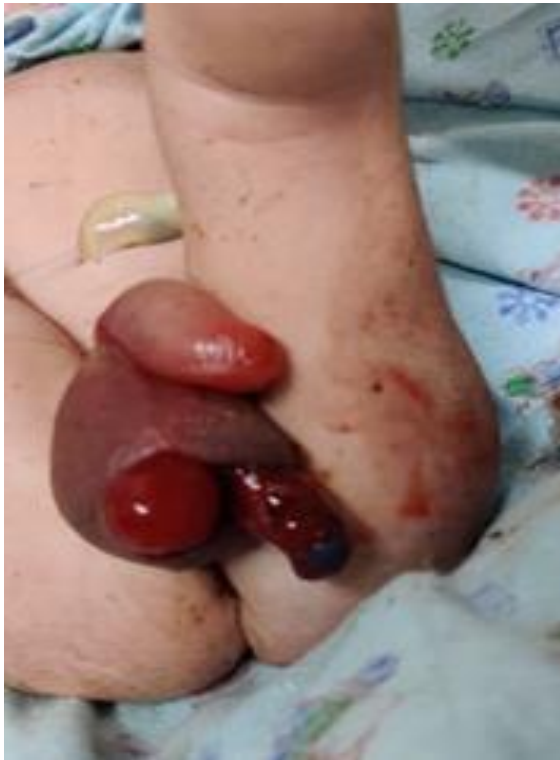

Figure 1: Showing the edematous penis, ruptured scrotum, and exposed bilateral testes with the gangrenous left testicle.

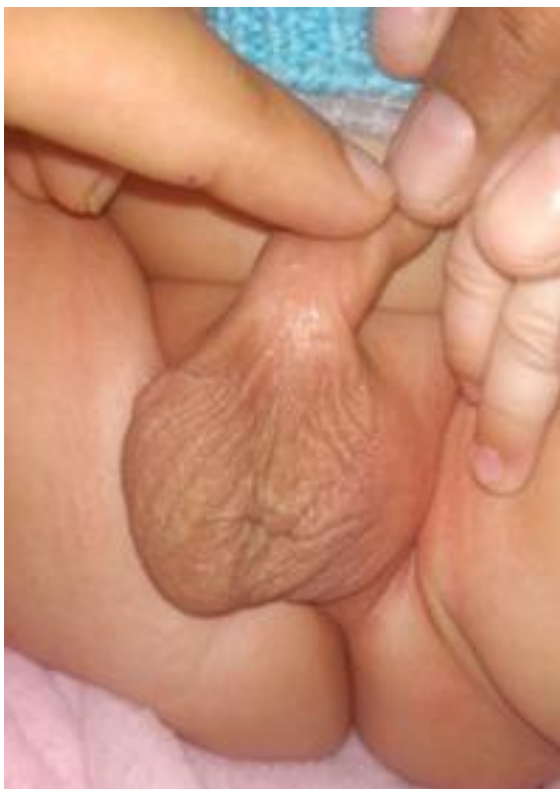

Figure 2: Showing the healed scrotal wound

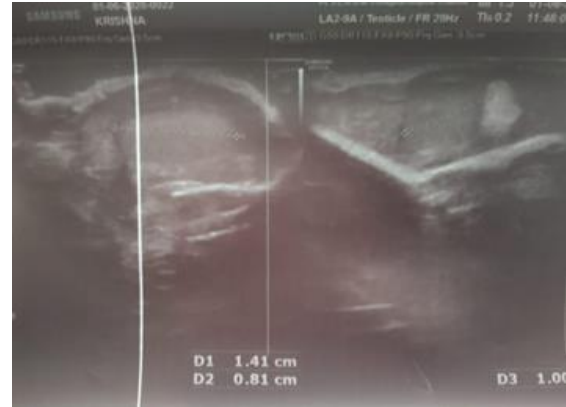


Figure 3: USG Doppler Showing the normal right testes and normal vascular flow on Doppler.

DISCUSSION

Genital injuries are more common in vaginal breech deliveries. Testicular injuries in the singleton vaginal breech deliveries occur in about 10 % of the babies.^[5] Genital injuries may range from injuries to the scrotum, penis, testicular hematomas, labial hematomas, and necrosis seen in female neonates.^[6] These injuries were not considered significant until 1975, when Peter M Dunn presented the findings of his survey conducted at Birmingham Maternity Hospital, in front of the Pediatric Research Society.^[5] The testicular birth injuries are more commonly seen in the first-born singleton vaginal breech deliveries. Not much consideration is given to this condition in the pediatric or urology textbooks either. This condition is commonly seen in the singleton infants born after 40 weeks and birth weights of more than 2.5 kilograms (KG). Repeated compressions of the presenting part i.e., perineum, against the dilating cervix, may lead to edema of the scrotum and the buttocks. Repeated per vaginal examination or forceful extraction of the breech may cause injury to the edematous scrotum and testicles.^[7] Bruising of the scrotum can be seen sometimes in bleeding disorders or rarely in congenital testicular torsion, in which case it is usually unilateral and associated with minimal pain. Long term follow-up and, consequences of testicular birth injuries are not known. Probably it may render the male sterile and, in order to prevent that, the bruised scrotum needs to be explored and, any hematoma of testes needs to be drained to avoid future necrosis of the testicles.^[5] USG of the scrotum is a good alternative if conservative management is planned. Only one case report similar to our case is reported by Matthews et al. in 1999, in which the neonate born out of VBB had extensive perineal edema and trauma along with gangrenous right testicle, which was removed.^[8] In another report, the baby got castrated at birth unknowingly, when the surgeon was performing a right mediolateral episiotomy for VBB.^[9] In a study by Tiwari CM, among 166 male breech babies, 13 babies born by

cesarean section did not show any injury to the genital area. Nineteen babies having VBB showed injury to buttocks, scrotum, or testes.^[10] Nowadays breech presentation is an indication for a Cesarean Section. Definitely, it can prevent most of the birth injuries. Karning RK et al. concluded that vaginal delivery is not completely a safe option but can be considered as safe route for breech babies as long as the selection criteria is fulfilled and delivery is conducted by a skilled obstetrician with intrapartum fetal monitoring.^[11]

CONCLUSION

Testicular birth injuries are severe but rare complications of vaginal breech delivery. They could be a source of litigation, so proper planning and documentation of the method of delivery by an expert is required. Cesarean section is an effective and safe method of preventing such injuries in a breech presentation during childbirth.

Consent

Written informed consent has been obtained from the patient. A copy of the written permission is available for review by the Editor-in-Chief of the journal.

Author's Contributions

Rohit Thakur: Contributed substantially to the Conception, design, Acquisition of data, Analysis and interpretation of data, drafting the article, Critical revision of the material, and final approval of the version published.

Rajesh Chaudhary: Contributed substantially to the Conception and design, Critical revision of the material, and final approval of the version published.

Arvind Bhatia: Contributed substantially to the Conception and design, Acquisition of data, Critical revision of the material, and final approval of the version published.

Saloni Sood: Contributed substantially to the Conception and design, Acquisition of data, Critical revision of the material, and final approval of the version published.

Ragini Bhatia: Contributed substantially to the Conception and design, Acquisition of data, Critical revision of the material, and final approval of the version published.

Gaurav R Kumar: Contributed substantially to the Conception and design, Acquisition of data, Critical revision of the material, and final approval of the version published.

REFERENCES

1. Ray S, Mondal R, Samanta M, Hazra A, Sabui TK, Debnath A, et al. Prospective study of neonatal birth trauma: An Indian perspective. *J Clin Neonatol.* 2016;5:91-5.

2. Levine MG, Holroyde J, Woods JR Jr, et al. Birth trauma: incidence and predisposing factors. *Obstet Gynecol.* 1984; 63(6):792-5.
3. Jadoon S, Jadoon SMK, Shah R. Maternal and neonatal complications in term breech delivered vaginally. *J Coll Physicians Surg Pak.* 2008;18(9):555-558.
4. Vane DW. Child abuse and birth injuries. In Grosfeld JJ, O'Neill JA Jr, Coran AG, Fonkalsrud EW, Caldamone AA, eds. *Pediatric Surgery*, 6th ed. Mosby Elsevier, 2006, Pp 400–407.
5. Dunn PM. Testicular birth injuries. *WEMJ Volume 114 No.3 Article 6 September 2015*
6. Spitz L, Steiner GM, Zachary RB. *Color atlas of pediatric surgical diagnosis.* Chicago: Year Book Medical Publishers; 1981.
7. Finan BF, Redman JF. Neonatal genital trauma. *Urology* 1985; 25:532–3
8. Mathews R, Sheridan E, Patil U Neonatal testicular loss secondary to perinatal trauma in breech presentation. *BJU International.* 1999;83:1069–1070.
9. Samuel G. Castration at birth. *Br Med J.* 1988;297:1313–1314.
10. Tiwary CM. Testicular injury in breech delivery: possible implications. *Urology* 1989; 34: 210–2
11. Karning RK, Bhanu BT, Sarojini. Mode of delivery and outcome of breech presentation: a prospective observational study in a tertiary centre. *Int J Reprod Contracept Obstet Gynecol* 2017;6:3409-13.

Copyright: © Annals of International Medical and Dental Research. It is an open-access article distributed under the terms of the Creative Commons Attribution Non-Commercial License, which permits unrestricted non-commercial use, distribution, and reproduction in any medium, provided the original work is properly cited.

How to cite this article: Thakur R, Bhatia A, Sood S, Chaudhary R, Bhatia R, Kumar GR. Ruptured Scrotum and Gangrenous Testis in a Newborn Ending up in Orchidectomy after Vaginal Breech Delivery: A Case Report. *Ann. Int. Med. Den. Res.* 2020; 6(4):SG22-SG24.

Source of Support: Nil, **Conflict of Interest:** None declared