

Role of EsophagoGastroDuodenoscopy for Detection of Upper GI Malignancy – Our Experience.

Chawngthu Vanlalhlua¹, Rachel Lalramlawmi²

¹Associate Professor, Department of Surgery, Zoram Medical College, Mizoram.

²Endoscopist, State Referral Hospital, Falkawn, Zoram Medical College, Mizoram.

Received: January 2020

Accepted: January 2020

Copyright: © the author(s), publisher. It is an open-access article distributed under the terms of the Creative Commons Attribution Non-Commercial License, which permits unrestricted non-commercial use, distribution, and reproduction in any medium, provided the original work is properly cited.

ABSTRACT

Background: Abdominal discomfort and dyspepsia is one of the most common symptoms in patients referred for EsophagoGastroDuodenoscopy (EGD) in our centre. With the invention of fiberoptic flexible endoscopy, upper GI endoscopy has become easily available, safe and reliable procedure. With further advancements in narrow band imaging and chromoendoscopy, precision of biopsy techniques and diagnosis has been significantly increased. The aim of this study was to find out the role of endoscopy to detect upper gastrointestinal malignancy. **Methods:** This study comprised of 5910 patients referred from various departments to our Endoscopy centre, who had undergone UGI Endoscopy during the period of 2 years at Zoram Medical College starting from November 2017 to October 2019. All patients referred for Endoscopy were included. Age ranges from 8 years to 92 years old. EsophagoGastroDuodenoscopy was performed by Endoscopist/Surgeons in all subjects as a primary diagnostic investigation and interpretation of the findings as observed by a single observer was noted. Endoscopic biopsy was taken from any suspicious lesions. **Results:** Out of total 5910 endoscopy cases, biopsy was taken from 402 patients and out of which, 81 patients were found to be malignant case. Out of 81 malignant cases, 40 cases were esophagus and 41 (33+8) were stomach. It was found more in Male than Female (57:24). The majority of malignant cases were seen in older age group above 50yrs of age. **Conclusion:** We concluded that EsophagoGastroDuodenoscopy plays an important role for detection of carcinoma in upper gastrointestinal organs in patients with dyspepsia and abdominal pain.

Keywords: EsophagoGastroDuodenoscopy, Malignancy, Ulcers, Growths.

INTRODUCTION

Patients with pain upper abdomen constitute majority of patients referred for UGI Endoscopy. Although a detailed history and physical examination may help to arrive at diagnosis, most of the times it is difficult to do so considering the complexity of the abdominal anatomy. Routine investigations only have a subordinate role and results of Ultrasonography are limited by intestinal gas.^[1] Within the invention of fiberoptic glasses flexible endoscopy, upper GI endoscopy has become a safe, reliable and office procedure. With further advancements in narrow band imaging and chromoendoscopy, precision of biopsy techniques and diagnosis has been significantly increased.^[2] Discovery of role of *Helicobacter pylori* in the pathogenesis of gastric and duodenal ulcers was a breakthrough in the treatment of these lesions. Since then a variety of invasive and non-invasive tests are available to diagnose *H.pylori* infection.^[3]

Endoscopy is a sensitive diagnostic test for peptic ulcers. Endoscopy was more sensitive (92% vs 54%) and more specific (100 vs 91%) than radiographic examination.^[4] The main role of Endoscopy in patients with uncomplicated peptic ulcer diseases is to confirm the diagnosis, identify lesions too small to be detected by radiographic examination and to rule out malignancy by performing endoscopic biopsy.^[5] *Helicobacter pylori* bacteria is a fastidious and microaerophilic gram-negative bacteria that colonizes human gastric mucosa.^[6] Barry Marshall and Robin Warren established its role in peptic ulcer disease; it affects 50% of the world population.^[7] It colonizes the gastric mucosa during childhood and usually remains asymptomatic. It causes peptic ulcer disease and gastric malignancy in 10-15% of infected patients. Close person to person contact is the mode of transmission and it is transmitted by feco-oral and oro-oral routes.^[8]

Carcinoma stomach is the second most common cancer mortality worldwide accounting for almost 10% of all new cancer deaths, the overall 5yr survival rate in these patients is less than 25% which reflects the late stage at which so many patients present.^[9] Symptoms of gastric cancer in the early stage are covert and do not differ from those found in dyspepsia.^[10] Early detection and treatment will improve favourable outcome, the role of lifestyle

Name & Address of Corresponding Author

Dr. Chawngthu Vanlalhlua,
Associate Professor,
Department of General Surgery,
Zoram Medical College,
Falkawn, Mizoram, N.E.India.

and dietary factors are being investigated and proved to be pivotal in causing gastric cancer.^[11] The aim of this study was to find out the role of endoscopy to detect upper gastrointestinal malignancy.

MATERIALS AND METHODS

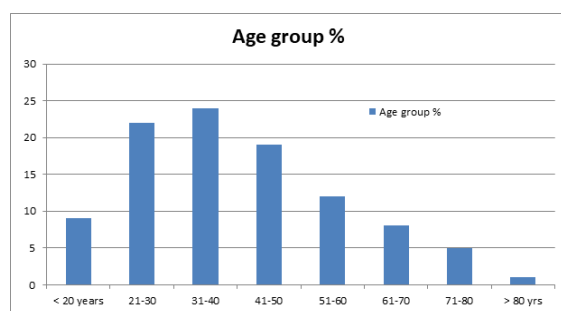
This prospective observational study was conducted in the department of Surgery Endoscopy centre, State Referral Hospital of Zoram Medical College, Falkawn, and LRM Hospital, Aizawl, Mizoram during the periods of two years starting from November 2017 to October 2019. All patients referred for UGI Endoscopy totaling 5910 consecutive cases were included; their age ranges from 8years to 92 years old. Before taking up the study, approval for carrying out the research work was obtained from the Hospital Ethical Committee. Informed Consent was taken for each case.

After explaining the procedure, patient was premedicated by spraying oropharynx (10% Lignocaine) with or without sedation by Inj. Midazolam 2mg i.v just before the procedure. Upper GI Endoscopy (EsophagoGastroDuodenoscopy) was performed by Endoscopist/Surgeons in all subjects as a primary diagnostic investigation and interpretation of the findings as observed by a single observer was noted, recorded and reported. Four to six pieces of tissues was taken for biopsy using biopsy forcep from ulcers/growth/polyps or any suspicious abnormal findings of any sites, kept in formalin vial and sent for histopathological examination to Pathology department, reports were collected and recorded.

RESULTS

Table 1: Age group distribution of all cases.

Age group	No. patients	Percentage
< 20 yrs	532	9 %
21-30	1300	22 %
31 -40	1418	24%
41 -50	1123	19%
51 -60	709	12%
61 -70	473	8%
71 -80	296	5%
>80 yrs	59	1%
Total	5910	100%



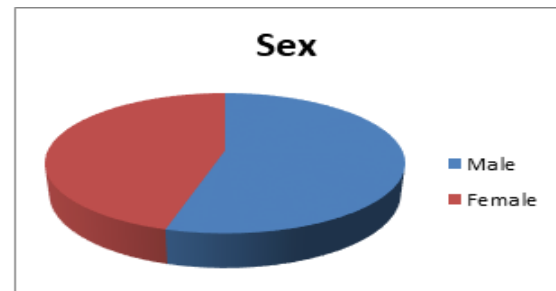
Bar Chart 1: showing age distribution of all cases.

This study includes all patients referred to our Endoscopy centre of varying ages ranging from 8yrs

to 92yrs of age with the maximum number in the age groups of 31-40 yrs of as shown in the table. We had 3 cases of below 11 years old– 8yrs, 9yrs, and 10 yrs each. And two 2 cases of more than 90yrs old – 91yrs and 92 years.

Table 2: Sex distribution of all cases. This study comprises of 54.48% male and 45.52% females.

Sex Distribution	No. of Patients	Percentage
Male	3220	54.48%
Female	2690	45.52%
Total	5910	100%



Pie chart 1: showing sex distribution of all cases.

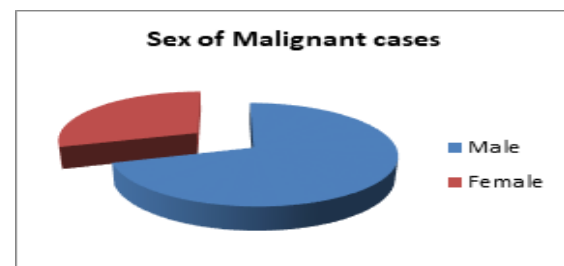
Table 3: Biopsy and Malignancy

Biopsy and Sites of Malignancy	No. of patients	Percentage of total 5910 cases	
Ulcers/Growths (Esophagus/Stomach/Duodenum) From where Biopsy taken	402 (out of 5910).	6.80%	
Malignancy confirm from Biopsy (HPE)	81	1.37%	
Malignant Ulcer/growth in esophagus	40	0.67%	
Malignant Ulcer/growth in Stomach	Proximal Gastric	8	0.18%
	Distal Gastric	33	0.55%


Out of total 5910 endoscopy cases, biopsy was taken from 402 patients and out of which, 81 patients were found to be malignant case. Out of 81 malignant cases, 40 cases were esophagus and 41 (33+8) were stomach. It was found more in Male than Female (57:24). The majority of malignant cases were seen in older age group above 50yrs of age.

Table 4: Sites and Sex: Malignancy cases (81 out of 4910 = 1.37%).

Sites	Male	Female	Total
Esophagus	31	9	40
Proximal Stomach	5	3	8
Distal stomach	21	12	33
Total	57	24	81



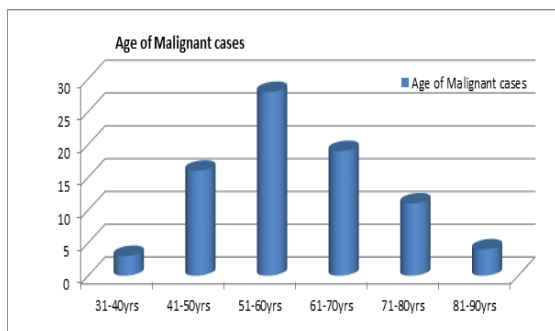
Pie chart 2: Sex of malignant cases



Pie chart 3: Sites of Malignancy

Table 5: Age distribution of malignancy

Age gr	Male	female	Total
31-40	2	1	3
41-50	12	4	16
51-60	18	10	28
61-70	13	6	19
71-80	9	2	11
81-90	3	1	4
Total	57	24	81



Bar chart 2: Age group

Out of 81 malignant cases, 40 cases were in esophagus and 41 (33+8) were in stomach. It was found more in Male than Female (57:24). The majority of cases were seen in older age group above 50yrs of age.

DISCUSSION

This present study showed that majority of patients referred for Endoscopy in our center were aged between 31 and 50 years and males are found to be more than females. These findings may be attributable to increased work place stress, untimely food intake habits and consumption of spicy food, alcohol intake and smoking. This has a significant impact on their work in terms of absence from work and decrease in income.

In our series, the total incidence of carcinoma of esophagus and stomach was 1.37% (81) from all the cases with the peak incidence in 6th decade which is in concordance with Chenkual S et al study.^[12]

Out of total 5910 endoscopy cases, biopsy was taken from 402 patients and out of which, 81 patients were found to have cancer positive. Out of 81 cancer cases, 40 cases were esophagus and 41 (33+8) were stomach. It was found more in Male than Female (57:24). The majority of cases were seen in older age group above 50yrs of age.

Upper GI Endoscopy is cost effective in long term management of chronic upper abdominal pain.^[13] It is considered as gold standard for diagnosing gastric and duodenal ulcers.^[14,15] It is also safe and useful in paediatric and adolescent patients.^[16,17]

CONCLUSION

We concluded that EsophagoGastroDuodenoscopy (EGD) plays an important role in patients with upper abdominal discomfort. Because of its precision and relatively safe technique, UGI Endoscopy may be considered in all patients with complaints of persistent pain in upper abdomen. Subjecting patients early to endoscopy helps to detect the malignancy in early stage and has a significant positive impact on their treatment. It not only helps in diagnosing the pathology but also provides an opportunity to do therapeutic interventions and helps to delineate the extent of pathology.

REFERENCES

1. Kasznia BJ and Karnati G: Imaging of the upper gastrointestinal tract; endoscopy or radiology? Br. J. Hosp. Med. (Lond). 2011; 72(3): M39-M43.
2. Alina B, Cristian B and Silvia D: Narrow band imaging with magnifying endoscopy for the evaluation of gastrointestinal lesion, World Gastrintest Endosc. 2015, Feb. 16; 7(2): 100-120.
3. O'Connor H: The role of Helicobacter pylori in peptic ulcer disease. Scand J Gastroenterol Suppl, 1994; 2011-15.
4. Jia-Qing H, Subbaramiah S and Richard HH: Role of Helicobacter pylori infection and non-steroidal anti-inflammatory drugs in peptic-ulcer disease; a meta-analysis. Lancet, 2002; 359: 14-22.
5. Richard GL III, Nicholas J and Talley J: Prevalence and clinical spectrum of Gastro esophageal Reflux; a population based study on Olmsted County, Minnesota, Gastroenterology, 1997; 112: 1448-56.
6. Esebei LH and Zugari RM: Epidemiology of Helicobacter pylori infection. Helicobacter, 2014; 14: 1-5.
7. Goh KL, Chan WK, Shiota S and Yamaoka Y: Epidemiology of Helicobacter pylori infection and public health implication: Helicobacter, 2011; 16 (1): 1-9.
8. Diaconu S, Predescu A, Moldoveanu A, Pop CS and Fierbinteanu-Braticevici C: Helicobacter pylori infection: Old and New. J. Med. Life, 2017; 10:112-117.
9. Crew K, Neugut A: Epidemiology of gastric cancer. World Journal of Gastroenterology, 2006; 3(12):354-62.
10. Tan Y and Fielding J: Early diagnosis of early gastric cancer. European Journal of Gastroenterology & Hepatology, 2006; 18(8): 821-9.
11. Nagini S: Carcinoma of the stomach: A review of epidemiology, pathogenesis, molecular genetics and chemoprevention. World Journal of Gastroenterology. 201; 4(7): 156-8.
12. Chenkual S, Ralte Z, Reddy VG. Study of postoperative outcome following Billroth-2 reconstruction after subtotal

- gastrectomy for carcinoma of stomach. *Int J Surg Med*. 2019; 5(4): 202-206.
13. Working party of the clinical services committee of the British Society of Gastroenterology: provision of gastrointestinal endoscopy and related services for a district general. *Gut*. 1991; 32: 95-101.
 14. Eisen GM, Dominitz JA, Faigel DO, Goldstein JA, Kalloo AN, Petersen BT, Raddawi HM, Ryan ME, Vargo JJ, Young HS, Fanelli RD, Hyman NH and Wheeler HJ: American Society for Gastrointestinal Endoscopy. The role of endoscopy in dyspepsia. *Gastrointest Endosc*. 2001; 54(6): 815-7.
 15. Ukarpol N, Lertprasertsuk N and Wongsawasdi L: Recurrent abdominal pain: the utility of upper GI Endoscopy and histopathology. *Singapore Med Journal*, 2004; 45(3): 121-4.
 16. Kumar M: Endoscopic, Histologic and Microbiologic evaluation of upper abdominal pain with special reference to *Helicobacter pylori* infection. *Ind. Pediatr*. 1996; 33(11): 905-9.
 17. Tom Richard Okello: Upper gastrointestinal endoscopic findings in adolescents at Lacor hospital, Uganda, *Afr Health Sci*. 2006; 6(1): 39-42.

How to cite this article: Vanlalhlua C, Lalramlawmi R. Role of EsophagoGastroDuodenoscopy for Detection of Upper GI Malignancy – Our Experience. *Ann. Int. Med. Den. Res*. 2020; 6(2):SG05-SG08.

Source of Support: Nil, **Conflict of Interest:** None declared