

MR Mammography and Sono-mammography in Characterization of Breast Lesions in a Tertiary Care Centre of Eastern India

Sohini Sengupta¹, Chhabi², Samir Rana³, Archana Singh¹

¹Associate Professor, Department of Radiodiagnosis, IPGME&R and SSKM Hospital, Kolkata, India.

²Consultant Radiologist India.

³Assistant Professor, Department of Radiodiagnosis, IPGME&R and SSKM Hospital, Kolkata, India.

Received: January 2021

Accepted: February 2021

ABSTRACT

Background: Breast cancer is the most common cancer in women worldwide. Breast cancer among Indian woman is the second most common cancer after cervix. Early detection and characterization of breast masses is important for early management and reduction of mortality and morbidity. Objective: The main objective of the study was to characterize the breast masses using high resolution ultrasonography and Magnetic Resonance Imaging and then compare the obtained results with histopathological results. **Methods:** A prospective observational study was performed between January 2016 to June 2017. The study was conducted with a total sample size of 54 breast lesions which were evaluated by Ultrasonography and MR mammography (BI-RADS 3/ 4/5). The results of both ultrasonography and MRI were compared with the histopathological results which was taken as gold standard. **Results:** Sensitivity, Specificity of different radiological modalities were analysed using standard statistical methods using SPSS software and p value < 0.05 was considered statistically significant. Sensitivity (97.1%) and negative predictive value (94.2%) of MRI was more than that of HRUSG (86.7% & 75% respectively) in detection of breast carcinomas. Specificity (80%) and positive predictive value (89.2%) of MRI was more than that of HRUSG (75% & 85.3% respectively) in detection of breast carcinomas. **Conclusions:** USG is widely available and cost effective tool used as first line of investigation. Overall accuracy in detections of breast carcinoma by MRI (90.7%) is more than that of HRUSG (81.5%). MRI is especially useful in detection of DCIS as well as assessment of extent of disease especially chest wall involvement.

Keywords: MR Mammography, Breast lesions, Sono-mammography, BI-RADS.

1

INTRODUCTION

Breast cancer is one of the commonest causes of death in middle-aged women all over the world. Breast cancer among Indian woman is the second most common cancer after cervix. The burden of breast cancer is increasing both in developed and developing countries. Although breast cancer can be detected at earlier stages, cases are mostly diagnosed in later stages due the lack of awareness. X-ray mammogram had been the modality of screening and diagnosis for breast cancer. It is the tool for initial detection with particular strength is the ability to detect subtle microcalcification. But it has its own disadvantages as there is problem of radiation which is not good for women of young age due to presence of dense breast tissue etc. Recently ultrasound and MRI breast have received boost as new methods for breast cancer diagnosis. Ultrasound has basic role in separation of cystic to solid masses and has an advantage of being real time and any intervention becomes easy under its guidance. MRI has shown greater sensitivity in

detection, diagnosis and staging and in identifying occult breast carcinoma in contra-lateral breast. Setback of ultrasound is that it is user dependent and not good for post-menopausal involuted breasts. MRI has low specificity and increases the follow up burden. Histopathological study is the gold standard for definite diagnosis of breast cancer.

Aims & Objectives:

1. To evaluate the breast masses using Ultrasound and MRI.
2. To compare the results obtained through the above modalities with histopathological studies.

MATERIALS & METHODS

This is a prospective observational study conducted in the Department of Radiodiagnosis in collaboration with the Department of General Surgery and Department of Pathology of IPGME&R and SSKM Hospital, Kolkata from January 2016 to June 2017. The study was approved by the "Institutional Ethical Committee. A total 54 cases were studied between January 2016 to June 2017.

Inclusion criteria:

1. Patients demonstrating symptoms and signs of suspicious masses, skin thickening, deformity of nipple and areola complex, discharge, nipple eczema

Name & Address of Corresponding Author

Dr Archana Singh,
Associate Professor,
Department of Radiodiagnosis,
IPGME&R and SSKM Hospital,
Kolkata, India.
Email-asinghrd@gmail.com

and suspicious axillary lymphadenopathy [without a known primary focus].

2. Patients showing above mentioned irrespective of age.

Exclusion criteria:

1. Patients undergone cochlear or any form of metallic implants, has pacemaker, aneurysm clips.
2. Patients who are claustrophobic.
3. Patients has already received neo adjuvant chemotherapy.
4. Patients who have under gone incisional or excisional biopsies of suspicious breast lesion.
5. Male breast cases.
6. Patients with history of allergy to contrast material.
7. Patients who have not given consent for this study.

Parameters studied:

The breast mass is studied in both ultrasound and MRI for its morphological feature and dynamic contrast and BIRADS Score was allotted for both USG and MRI.

The provisional diagnosis made is compared with its histopathological findings.

Study tools:

- 3.0 Tesla (superconducting) MRI machine, WIPRO-GE Signa HDxt.
- High quality dedicated 16 channel surface coil for breast.
- Philips HD7 ultrasound with linear transducer (7.5-12 MHz)
- Informed consent

MRI acquisition and Post processing

Bilateral breast MRI was performed using 3.0T MR (Signa HDx 3.0T, GE Medical Systems) with a dedicated 16-channel bilateral breast coil with patient in the prone position. Bilateral breast MRI was done using the following protocol – an axial T2 sequence (TR/TE 3300/85; slice thickness 4 mm without any interslice gap; field of view (FOV) 32 × 32; matrix size 288 × 256); an axial STIR sequence (TR/TE 3125/68; inversion time 175 ms; slice thickness 4 mm without any interslice gap; FOV 32 × 32; matrix size 288 × 192); echo planar imaging (EPI)-based DWI sequence in axial planes at b values of 0 and 800 s/mm² (TR/TE 5825/minimum; slice thickness 3 mm; interslice gap 0; FOV 32 × 32 and matrix size 96 × 140; bandwidth 125 kHz; number of excitation 16; acquisition time 4–5 min depending on number of slices); an axial VIBRANT multiphase three-dimensional (3D) T1-weighted dynamic gradient-echo sequence obtained after 10 ml intravenous bolus injection of gadolinium DTPA at a rate of 2.5 ml/s followed by a 20-ml saline flush by a power injector (flip angle 12°; slice thickness 2 mm with no interslice gap; FOV 36 × 36; matrix 320 × 320). Dynamic study comprised one pre contrast and 7 post contrast series, each phase lasting 1 min 21 s. Automated subtracted images were obtained for each

of the seven phases. Kinetic curve assessment of the fastest enhancing component of the lesion or the most suspicious curve pattern in the lesion was assessed with the available software (Functool) in GE Workstation.

Ultrasound Technique:

Breast US should be performed with broadband linear electronically focused high frequency transducers. The center frequency should be 10Mhz, with frequency ranging as high as 17Mhz in the near field and as low as 5Mhz deeper in the image field, thus enabling greater penetration of the posterior breast tissue and pectoralis muscle. The patient is examined in the supine oblique position. The side being examined is raised and the arm is placed above the head to ensure that the breast is evenly distributed over the chest wall. If the US being done as target examination, proper area to scan must be determined from the mammogram or clinical examination. The direction of scanning is in the transverse and longitudinal directions. Scanning in the radial (parallel to the ducts) and anti-radial (perpendicular to ducts) planes is of value in demonstrating ductal abnormalities. If lesion is identified, its presence is confirmed with 90° rotation of the transducer. The specific location, including laterality and the distance from the nipple, should accurately annotated on the images and documented in the reports. It is often helpful to place the transducer slightly off center to the nipple and then use angulation to image the retroareolar tissues. Use of Doppler ultrasound of breast lesions have produced mixed results. Because Doppler technique relies on increased vascularity which can be seen in benign and malignant patients, significant overlap of positive findings is not unexpected. Penetrating vessels are more lightly to be present in malignant tumors.^[1]

Reference standard

All lesions with a MR BI-RADS category 3, 4, or 5 were compared with surgically excised specimen or with 14-gauge core needle biopsy under ultrasound guidance. Histopathological diagnosis was taken as the gold standard.

Statistical Analysis

For statistical analysis data were entered into a Microsoft excel spreadsheet and then analysed by SPSS 10.0.1 and Graph Pad Prism version 5. Data have been summarized as mean and standard deviation for numerical variables and count & percentages for categorical variables. The median and the interquartile range have been stated for numerical variables that are not normally distributed. Student's independent sample's t-test was applied to compare normally distributed numerical variables between groups. Unpaired proportions were compared by Chi-square test or Fischer's exact test, as appropriate.

Once a t value is determined, a p-value can be found using a table of values from Student's t-distribution. If

the calculated p-value is value is below the threshold chosen for statistical significance (usually the 0.10, the 0.05, or 0.01 level), then the null hypothesis is rejected in favour of the alternative hypothesis.

p<0.05 was considered statistically significant.

Interpretation of the various diagnostic procedures was compared with the histological examination with regard to sensitivity, specificity, accuracy, positive and negative predictive value. Criteria for positive test for malignancy includes BIRAD≥4 and negative test for malignancy includes BIRAD≤3.

Sensitivity = True Positive / (True Positive + False Negative)

Specificity= True Negative / (True Negative + False Positive)

Positive predictive value = True Positive / (True Positive + False Positive)

Negative predictive value= True Negative / (True Negative + False Negative)

% False Positive = False Positive / (True positive + False positive) %False Negative = False Negative / (True negative + False negative)

Accuracy = (True Positive + True Negative) / (True Positive + True Negative + False Positive + False Negative)

A result was classified as false negative when a diagnostic method classified a histologically confirmed cancer as benign. A result was classified as false-positive when a diagnostic method classified a histologically confirmed benign lesion as cancer .We compared the performance of all diagnostic methods individually and in combination, using the results from all patients.

RESULTS & DISCUSSION

Mammography and ultrasound are the first line imaging investigations in women with breast symptoms. MRI is established as an adjunctive diagnostic tool because of its high sensitivity for invasive breast cancer. Percutaneous image-guided biopsy is used for the histopathological assessment of breast lesion. The combination of imaging, clinical examination and needle biopsy- known as “triple assessment”- is the expected standard for the diagnosis of breast diseases.

In our study we found that breast cancers mostly present in the 51-60 years age group (50%) and mean age of occurrence is 56 years. As per Park`s textbook the mean age of occurrence of breast cancer in female is 42 years in India whereas 53 years in western countries. We found that overall breast cancers are more prevalent in the post-menopausal age group (82.4%).

In our study positive family history are shown to be associated with 11.8% of breast cancers. Most common histological type among breast carcinomas is IDC (76.5% +8.8% =85.3%).Majority of the cases are presented in later stages, mostly due to lack of awareness.

Table 1: Association between MRI Kinetic curve (types) and HPE Types

MRI Kinetic curve (type)	HPE Type		
	Benign	Malignant	Total
I	11	0	11
Row %	100.0	0.0	100.0
Col %	100.0	0.0	20.4
II	9	13	22
Row %	40.9	59.1	100.0
Col %	45.0	38.2	40.7
III	0	21	21
Row %	0.0	100.0	100.0
Col %	0.0	61.8	38.9
Total	20	34	54
Row %	37.1	62.9	100.0
Col %	100.0	100.0	100.0

p<0.001

Table 2: Association between HRUSG MORPHOLOGY (BIRADS) in malignant patients

HRUSG Morphology	Truth (HPE Results)		
	Positive (Malignant)	Negative (Benign)	Total
Positive (BIRAD ≥4)	29.0	5.0	34.0
Row %	85.3	14.7	100.0
Col %	85.3	25.0	62.9
Negative (BIRAD ≤3)	5.0	15.0	20.0
Row %	25.0	75.0	100.0
Col %	14.7	75.0	37.1
Total	34.0	20.0	54.0
Row %	62.9	37.1	100.0
Col %	100.0	100.0	100.0

p<0.001

Sensitivity : 85.2%

Specificity : 75%

Positive Predictive Value : 85.3%

Negative Predictive Value: 75%

Accuracy : 81.5

Table 3: Association between MRI morphology (BIRADS) in malignant patients

MRI MORPH	Truth (HPE Results)		
	Positive (Malignant)	Negative (Benign)	Total
Positive (BIRAD ≥4)	33	4	37
Row %	89.2	10.8	100.0
Col %	97.1	20	68.5
Negative (BIRAD ≤3)	1	16	17
Row %	5.9	94.1	100.0
Col %	2.9	80	31.5
Total	34	20	54
Row %	62.7	37.1	100.0
Col %	100.0	100.0	100.0

p<0.001

Sensitivity : 97.1%

Specificity : 80%

Positive Predictive Val : 89.2%

Negative Predictive Value: 94.1%

Accuracy : 90.7

In MRI study we found that BI-RAD 3 cases are all benign (83.3%), in BI-RAD 4 category malignancy noted in 80% cases and in BI-RAD 5 category 92.9% cases are malignant. As per ACR likelihood of malignancy of BI-RAD 3, 4, & 5 are respectively ≤2%, >2 -<95% and ≥ 95%.Inour study, we found the following relationship between the type of kinetic

curve and malignancy: type I- 0%, type II- 59.1% and type III-100% malignant. Laura Libermann et al said visually assessed kinetic patterns were not significant predictors of carcinoma, but washout was present in 70% of infiltrating carcinomas versus 9% of DCIS lesions ($p < 0.01$).^[3]

Table 4: Comparison of Validity of Different Modalities in Breast Carcinoma

	MRI (%)	HRUSG (%)
SENSITIVITY	97.1	85.2
SPECIFICITY	80	75
PPV	89.2	85.3
NPV	94.2	75
%FP	20	25
%FN	2.9	14.7
ACCURACY	90.7	81.5

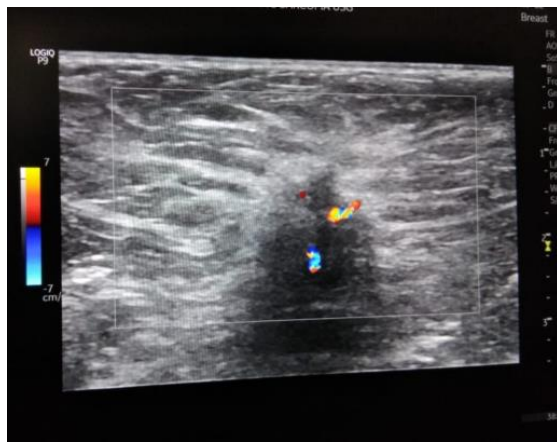

Figure 1: USG image of left breast in a 62 year old female showing hypoechoic, taller than wide mass with spiculated margin and central vascularity

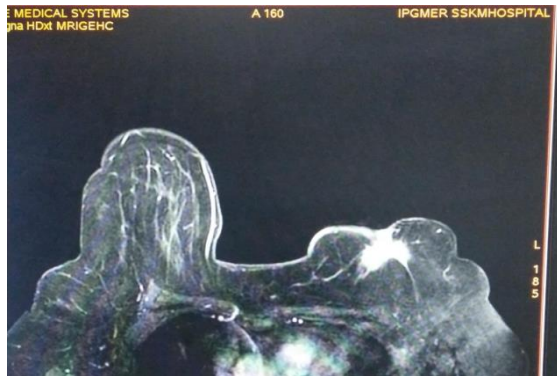


Figure 2: MR Mammography (post contrast axial Vibrant sequence) of same patient showing heterogeneously enhancing mass with spiculated margin and nipple retraction in the left breast

Liuquan Cheng et al described that generally, a persistent curve is suggestive of benign changes; washout, malignancy; and plateau, either benign change or malignancy. In the current study DCIS detection rate by MRI (75%) is definitely more than that of HRUSG (50%).

Arjan P Schouten van der Velden et al. observed that detection rate of DCIS on MRI ranges from 38% to 100%.^[5]

Katarzyna J. Macura et al. found sensitivity of MR imaging for detection of DCIS lies in between 40% and 100%.^[6]

Christiane Kuhl et al. observed that about 10% of DCIS cases diagnosed with the aid of mammography will not be diagnosed with MR owing to absence of enhancement. And up to 40% DCIS cases are diagnosed only with breast MR imaging.^[7]

Sabine Malur et al. found carcinoma in situ was diagnosed by mammography in 78.9% and by MR mammography in 68.4% of patients.^[8]

Combination of all three diagnostic methods lead to the best results for detection of invasive cancer and multifocal disease. However, sensitivity of mammography and sonography combined was identical to that of MR mammography (i.e. 94.6%).

In our study we found that:

- Sensitivity (97.1%) and negative predictive value (94.2%) of MRI appears definitely more than that of HRUSG (85.3% & 75% respectively) in detection of breast carcinomas.
- Specificity (80%) and positive predictive value (89.2%) of MRI appears definitely more than that of HRUSG (75% & 85.3% respectively) in detection of breast carcinomas.
- False positive cases by MRI (2.9%) is less than that of HRUSG (14.7%). Whereas false negative cases are least with MRI (20%) in comparison with HRUSG (25%)
- Overall accuracy in detections of breast carcinoma by MRI (90.7%) is more than that of HRUSG (81.4%).

CONCLUSION

- USG breast is a widely available and cost effective tool for first line investigation of breast masses
- Compared with HRUSG, MR mammography has higher sensitivity, Positive Predictive Value, specificity and Negative Predictive Value.
- Hence MR mammography is an effective diagnostic adjunct for breast masses.
- MRI is superior modality for DCIS

REFERENCES

1. Smriti Hari, Sanjay Thulkar, Arun Kr. Gupta et al. A Systematic Approach to Imaging of Breast Lesions. Normal mammographic anatomy, Diagnostic Radiology Musculoskeletal and Breast Imaging, 3rd Edition, Jaypee. P454.
2. Christiane Kuhl et al. The Current Status of Breast MR Imaging, Part I. Choice of Technique, Image Interpretation, Diagnostic Accuracy and Transfer to Clinical Practice: the university of Bonn breast MR imaging protocol: Aug 2007, Vol 244 (2), 362.
3. Laura Liberman et al Breast lesions detected on MR Imaging: Features and positive predictive value AJR 2002; 179:171-178
4. Liuquan Cheng and Xiru Li. Gland Surgery: Breast Magnetic Resonance Imaging: Kinetic Curve Assessment: Gland Surg. 2013 Feb; 2(1): 50-53

5. Arjan P. Schouten van der velden et al. Magnetic resonance imaging of ductal carcinoma in-situ: what is its clinical application? A review. The American Journal of Surgery REVIEW Volume 198, issue 2, p 262-269, August 01, 2009
6. Macura, K.J. et al: "Patterns of Enhancement of Breast MR Images: Interpretation and Imaging Pitfalls." Radiographics 2006 Nov-Dec; 26(6): 1719-1734
7. Christiane K Kuhl et al. MRI for diagnosis of pure ductal carcinoma in situ : a prospective observational study Lancet.2007 Aug 11;370 (9586): 485-92
8. Sabine Malur, Susanne Wurdinger, Andreas Moritz, Wolfgang, Michels and Achim Schneider et al: Comparison of written reportS of mammography, sonography and magnetic resonance mammography for preoperative evaluation of breast lesions, with special emphasis on magnetic resonance mammography: Breast Cancer Res2001, 3:5560 doi:10.1186/bcr27.

Copyright: © the author(s), 2020. It is an open-access article distributed under the terms of the Creative Commons Attribution License (CC BY 4.0), which permits authors to retain ownership of the copyright for their content, and allow anyone to download, reuse, reprint, modify, distribute and/or copy the content as long as the original authors and source are cited.

How to cite this article: Sengupta S, Chhabi, Rana S, Singh A. MR Mammography and Sono-mammography in Characterization of Breast Lesions in a Tertiary Care Centre of Eastern India. Ann. Int. Med. Den. Res. 2021; 7(2):RD22-RD26.

Source of Support: Nil, **Conflict of Interest:** None declared