

# Evaluation of Risk Factors in Congenital Patello-Femoral Instability by Magnetic Resonance Imaging

Samir Rana<sup>1</sup>, Indrani Basak<sup>2</sup>, Avik Sarkar<sup>3</sup>, Madan Karmakar<sup>4</sup>

<sup>1</sup>Assistant Professor, Department of Radiology, I.P.G.M.E&R, Kolkata, India.

<sup>2</sup>Junior Resident, Department Of Radiology, I.P.G.M.E&R, Kolkata, India.

<sup>3</sup>Assistant Professor, Department Of Gastro-Radiology, I.P.G.M.E&R, Kolkata, India.

<sup>4</sup>Professor, Department Of Radiology, I.P.G.M.E&R, Kolkata, India.

Received: January 2021

Accepted: February 2021

## ABSTRACT

**Background:** Patello-femoral instability is a clinical syndrome where the patella is prone to recurrent lateral dislocation. Patellar articular surface is relatively smaller than the trochlear articular surface. Joint geometry plays an important role for stabilization during movements. Aim of our study was to evaluate various acquired and congenital morphologic alterations of the patello-femoral joint (PFJ) by magnetic resonance imaging (MRI), which are responsible for patella-femoral instability. **Methods:** It was a cross sectional study and was carried out for a period of one and half year. MRI of the affected knee joint was done in a 3T MRI system in 30 patients with clinical diagnosis of patella-femoral instability. We assessed trochlear dysplasia (Dejour's classification of morphological types of trochlear dysplasia, lateral trochlear inclination angle, trochlear facet asymmetry ratio and trochlear depth), patella alta by Insall-Salvati Index and distance between tibial tuberosity and trochlear groove (TTTG distance) in all the patients. **Results:** Most of the patients were in 10-20 years group with female predominance. Trochlear dysplasia and patella alta are the two most common risk factors in our study and were present in 60% and 66.7% population respectively. However, only half of the patients had increased TTTG distance in our study. **Conclusions:** MRI of knee joint is very helpful in assessment of risk factors for patello-femoral instability. Standard MRI protocol and careful measurement of various parameters help in accurate detection of trochlear dysplasia, patella alta and increased TTTG distance and helps in further management of the patients.

**Keywords:** MRI, Patella alta, Patello-femoral instability, trochlear dysplasia, TTTG distance.

1

## INTRODUCTION

The PFJ is a complex joint with high biomechanical and functional requirements for the various movements.<sup>[1]</sup> Extensor muscles are the active stabilizers and the bones and ligaments are the passive stabilizers of this joint. Joint geometry plays a vital role for stabilization during movements. Patellar pathologies are a common cause of anterior knee pain in adolescent and young adults.<sup>[2]</sup> Various developmental and acquired alterations of this joint result in various patellar pathologies.<sup>[3]</sup> Patello-femoral instability is defined as an abnormal lateral translation of patella during flexion of the knee with or without patellar dislocation.<sup>[3]</sup> Recurrent patellar dislocation of patella may subsequently result in chondromalacia patella, arthritis and degenerative changes if left untreated.<sup>[3]</sup> The three important risk factors for patella-femoral instability are, patella alta (high riding patella), trochlear dysplasia and lateralization of tibial tuberosity.<sup>[4]</sup> Trochlear dysplasia is flattening of the trochlear articular surface that causes lateral patellar displacement

during knee joint flexion.<sup>[5]</sup> For many decades, conventional radiography & computed tomography (CT) were the imaging investigations to assess the joint instability. In recent years, however, MRI has emerged as an alternative effective method for investigation. It has advantages in terms of detecting osteochondral lesions and soft tissue injuries including medial patella-femoral ligament (MPFL) in addition to identifying predisposing morphologic abnormalities without exposing the patient to ionizing radiation.<sup>[6-8]</sup> It provides accurate and reproducible measurements for assessment of trochlear dysplasia.<sup>[3]</sup> MRI also helps in quantification and characterization of these anatomic risk factors and helps in deciding the orthopaedic management.<sup>[9]</sup>

## MATERIALS & METHODS

A cross-sectional study was conducted for a period of one and half year in the Department of Radiodiagnosis in a tertiary care hospital of eastern India. Total 30 patients, who attended out-patient department of orthopedics with subsequent clinical diagnosis of congenital patello-femoral instability were included in our study. All patients with traumatic patellar dislocation, history of previous knee surgery, contraindications to use of MRI and not providing informed written consent, were excluded from this study. Ethical Committee

### Name & Address of Corresponding Author

Dr. Samir Rana  
Assistant Professor,  
Department of Radiology,  
I.P.G.M.E&R,  
Kolkata, India.  
dr.samirrana@gmail.com

Clearance was obtained. MRI of knee joint was performed using 3.0Tesla MRI Machine (GE Healthcare), Signa 3T HDxt with Extremity Knee coil (16 channel). Images were viewed on a dedicated MRI Console (HP, Z800 Workstation). Sagittal T1, T2, PD (FS) cube, GRE (Gradient-Recalled-Echo), Coronal PDFS, Axial T2 & T2FS sequences were obtained in all patients.

Simple statistical analysis and percentage calculations were done to detect the incidence of various risk factors present in congenital patella-femoral instability in a study population of 30.

#### Trochlear dysplasia was evaluated as below;

1. Dejour's Classification: For classifying morphology of trochlear dysplasia we used this one.<sup>[4,10]</sup>

**Type A**-Normal trochlear shape preserved but appears shallow.

**Type B**- Markedly flattened or convex surface of trochlear.

**Type C**-Asymmetric trochlear facets, with the lateral facet being too high and medial facet being hypoplastic, resulting in the flattened joint surface.

**Type D**- Cases with type C morphology with ventral prominence in supra trochlear region.<sup>[10]</sup>

2. Lateral Trochlear Inclination: The superior most section from axial images showing trochlear cartilage was selected. Inclination Angle was measured between a line through the lateral trochlear facet along the sub chondral bone and a tangential line through the posterior surfaces of medial and lateral femoral condyles. Inclination angle of  $\leq 11$  degrees was taken as cut off for trochlear dysplasia.<sup>[11]</sup>
3. Trochlear Facet Asymmetry Ratio: Ratio of medial trochlear facet length to lateral trochlear facet length was calculated 3cm above the tibio femoral cleft on an axial MRI image. A trochlear facet ratio of less than 40% (0.4) is defined as indicator of dysplasia.<sup>[12]</sup>
4. Trochlear depth: This measures the inset depth of the trochlear groove (sulcus) relative to the average of the maximum anteroposterior distance of the medial and lateral femoral condyles (it is determined on axial images at the same level as trochlear facet asymmetry). Trochlear dysplasia is assumed if trochlear depth is 3mm or less.<sup>[12]</sup>

#### Patella alta:

The ratio of patellar tendon length (measured from apex of patella on sagittal image to its attachment to tibial tuberosity below) to the maximum supero-inferior patellar distance. Patellar height ratio of more than 1.3 (which is the normal plus 2 standard deviations) was taken as patella alta.<sup>[9,10]</sup>

#### TTTG distance:

TTTG distance was measured on axial MRI images. The distance between the middle of tibial tuberosity to the deepest point of trochlear groove was taken. Distance of  $< 13$  mm was considered normal, and

13mm or more as predisposing factor for patellar instability.<sup>[15]</sup>

Injury of the MPFL and the medial patellar retinaculum is diagnosed on MR images in 70-100% patients examined after lateral patellar dislocation. In 1/4th of cases, the MPFL is ruptured at the femoral attachment, which can also occur in the form of an avulsion tear of epicondyle.<sup>[16]</sup>

## RESULTS

Out of 30 patients, 20 were female (66.7%) patients and 10 male (33.3%) patients. Mean age of the patients was  $17.00 \pm 6.2367$  and majority of patients were in 10-20 years age group (18 out of 30 cases i.e. 60%).

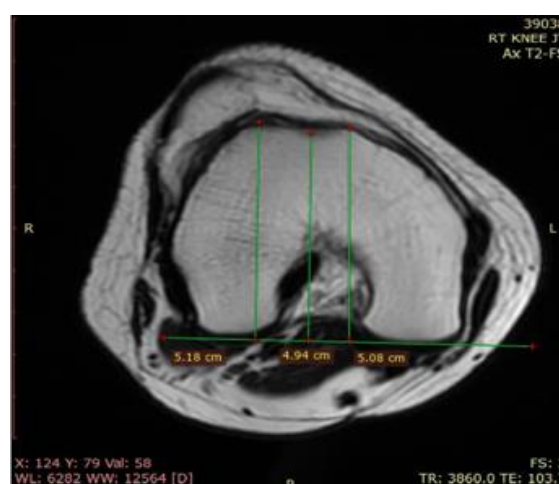


Figure 1: Trochlear depth  $< 3$ mm (axial T2W image)

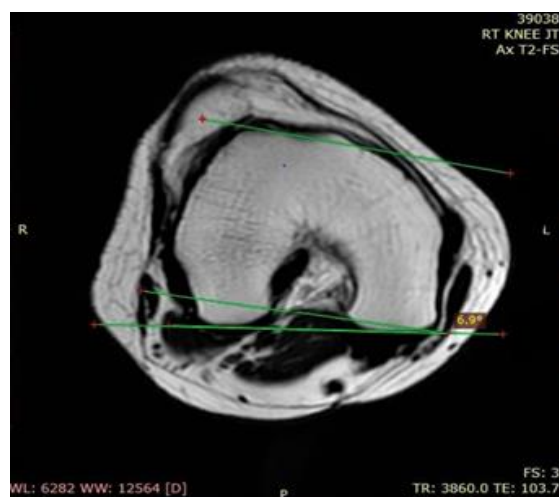


Figure 2: Lateral trochlear inclination angle  $< 11^\circ$

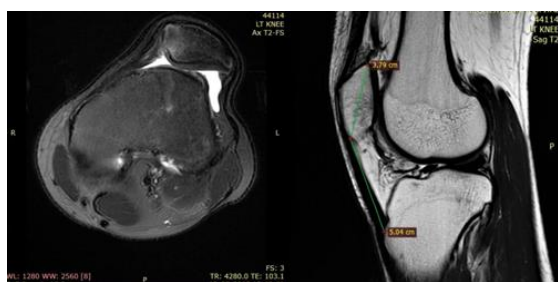Morphology of trochlear facet in our study was as follows: Dejour's type A in 13 patients, type B in 7 patients, type C in 2 patients and type D in no patients. Hence there was 73.3% morphological abnormality of trochlear facet in our study. Shallow trochlear depth ( $< 3$ mm) was present in 17 out of 30 patients i.e. 56.7% [Figure 1]. In our study  $< 11^\circ$  lateral trochlear inclination angle was present in 16 patients (53.3%) [Figure 2]. Abnormal trochlear

facet asymmetry ratio i.e. <40% was present in 10 out of 30 cases.

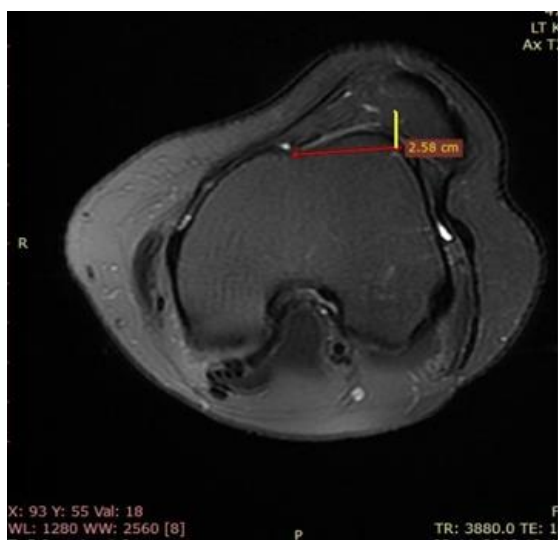Majority of our patients had patella alta [Figure 3]. 20 out of 30 patients (66.7%) in our study had increased patellar height ratio of >1.3 (Insall Salvati ratio).

TTTG distance was  $\geq 13$  mm (Figure 4) in 19 patients (63.3%) and <13mm in 11 patients.

We also studied MPFL status in our patients with congenital patellar instability. 7 (23.3%) patients had partial tear at patellar insertion and 14 (46.7%) patients had thinning at entire length. It was also noted that, patients having more number of previous episodes of patellar dislocations, had more MPFL abnormalities (16 patients with  $\geq 4$  episodes of dislocations and 5 patients with <4 episodes of dislocations had MPFL abnormalities).



**Figure 3: Patella alta with lateral patellar dislocation (Insall Salvati ratio 1.33)**



**Figure 4: Increased TTTG distance of 25.8mm (axial T2FS image)**

## DISCUSSION

There are multiple predisposing factors responsible for congenital patellar instability and resulting into recurrent patellar dislocations. Recurrent patellar dislocation results in soft tissue (particularly MPFL) and articular cartilage injury, one of the causes of anterior knee pain. MRI is very useful in assessing these risk factors as well as the resultant injuries.<sup>[2]</sup> We used a 3 Tesla MRI machine in clinically

diagnosed cases of congenital patellar instability and found 1 or more risk factors in all the patients.

Steensen et al. reported trochlear dysplasia in 69% patients with recurrent instability compared to 6% in controls, which supports our study.<sup>[17]</sup> In our study trochlear dysplasia was present in 22 patients out of 30 patients (73.3%). Burmann et al., and LaPrade et al. reported the incidence of different morphological types of trochlear dysplasia.<sup>[4,7]</sup> In both the studies Type A was the commonest and type D was the least common morphological type seen. In our study also we found type A as the most common morphology. Pfirrmann et al. carried out similar study and showed shallow trochlear groove as an important risk factor.<sup>[18]</sup> In our study we found trochlear depth of <3mm in 17 patients (56.7%), correlating well with the above mentioned study. In 16 patients (53.3%), in the present study, the lateral trochlear inclination angle was <11°. Previous study by Escala et al. have pointed out lateral trochlear inclination angle of <11° as a very important risk factor for patella-femoral instability.<sup>[19]</sup>

Insall-Salvati index is a reliable and simple parameter to assess the patellar height ratio which is also an important risk factor for patello-femoral instability.<sup>[13,14]</sup> Patella alta was present in 20 out of 30 patients (66.7%) in our study (Insall Salvati ratio of >1.3).

Lateralization of tibial tuberosity was present in 19 patients (63.3%) in our study. Giampietro et al. have shown the 13mm cut off value for TTTG distance with good sensitivity and specificity in patients with patella femoral instability.<sup>[15]</sup>

CT Scan of knee joint was once imaging gold standard for measurement of TTTG distance, however recent studies have shown that MRI can be used as an accurate alternate investigation without ionizing radiation and added advantage of soft tissue and articular cartilage evaluation.<sup>[20]</sup> Early detection of such predisposing risk factors in these patients and surgical correction prevents soft tissue and cartilage injuries and thus chronic knee pain and disabilities.<sup>[10]</sup> Trochleoplasty and medialization of tibial tuberosity is performed for trochlear dysplasia and increased TTTG distance patients respectively.<sup>[3,10]</sup>

MRI has limitations of less availability, high cost and some technical and patient related contraindications. Also the planes and protocols are to be chosen correctly for accurate measurements. Various measurements as described above, are not routinely obtained in MRI examination of knee, unless there is clinical suspicion of recurrent patellar dislocation. Maintaining optimum knee joint angulation (i.e 5-10%) during the scan and inclusion of tibial tuberosity in the scan area are important prerequisite for successful completion of the study.<sup>[21]</sup> We had to recall 3 patients to include the tibial tuberosity in the scan.

## CONCLUSION

MRI is a very useful imaging modality for the evaluation of predisposing factors in clinically suspected patients of congenital patello femoral instability. It is also capable of detecting soft tissue and cartilage injuries in these patients of recurrent patellar dislocations. Carefully performed MRI and image interpretation with detailed measurements in these patients can detect trochlear dysplasia, patella alta and increased TTTG distance and helps in timely surgical interventions.

## REFERENCES

1. Ali SA, Helmer R, Terk MR. Analysis of the patellofemoral region on mri: association of abnormal trochlear morphology with severe cartilage defects. *AJR Am J Roentgenol.* 2010;194(3):721-27.
2. Fahmy HF, Khater NH, Nasef NM, Nasef NM. Role of MRI in assessment of patello-femoral derangement in patients with anterior knee pain. *The Egyptian Journal of Radiology and Nuclear Medicine.* 2016;47:1485-92.
3. Diederichs G, Issever AS, Scheffler S. MR imaging of patellar instability: injury patterns and assessment of risk factors. *Radiographics.* 2010;30(4):961-81.
4. Burmann RC, Locks R, Pozzi JFA, Konkewicz ER, de Souza MP. Avaliation of predisposing factors in patellofemoral instabilities. *ActaOrtopedicaBrasileira.* 2011;19(1):37-40.
5. Bolog NV, Andreisek G, Ulbrich EJ. MRI of the Knee- A Guide to Evaluation and Reporting. *Radiology.* 2016;279(2):366-67.
6. Kohlitz T, Scheffler S, Jung T, et al. Prevalence and patterns of anatomical risk factors in patients after patellar dislocation: a case control study using MRI. *EurRadiol.* 2013;23(4):1067-74.
7. Sillanpaa PJ, Maenpaa HM, Mattila VM, Visuri T, Pihlajamaki H: Arthroscopic surgery for primary traumatic patellar dislocation. *Am J of Sports Medicine* 2208, 36:2301-9.
8. Biedert RM, Bachmann M. Antero-posterior trochlear measurements of normal and dysplastic trochlea by axial magnetic resonance imaging. *Knee Surg Sports TraumatolArthrosc.* 2009;17(10):1225-30
9. E Souza PM, de Sa Gabetto MS, Serrao GM. Patellofemoral instability: evaluation by Magnetic Resonance Imaging. *RevistaBrasileira de Ortopedia.* 2013;48(2):159-64.
10. LaPrade RF, Cram TR, James EW, Rasmussen MT. Trochlear dysplasia and the role of trochleoplasty. *Clin Sports Med.* 2014; 33:531-45.
11. Carrillon Y, Abidi H, Dejour D, Fantino O, Moyon B, Tran-Minh VA. Patellar instability: assessment on MR images by measuring the lateral trochlear inclination-initial experience. *Radiology.* 2000;216(2):582-85.
12. Pfirrmann CW, Zanetti M, Romero J, Hodler J. Femoral trochlear dysplasia: MR findings. *Radiology* 2000;216:858-64.
13. Barnett A, Prentice M, Mandalia V, Wakeley C, Eldridge J. Patellar height measurement intochlear dysplasia. *Knee Surg Sports TraumatolArthrosc.* 2009;17:1412-15.
14. Shabshin N, Schweitzer ME, Morrison WB, Parker L. MRI criteria for patella alta and baja. *Skeletal Radiol.* 2004;33:445-50.
15. Giampietro L. , Joaquin MA, Michael A, Ashley HA, Paul SS. Tibial Tubercle-Trochlear Groove Distance Is a Reliable and Accurate Indicator of Patellofemoral Instability. *ClinOrthopRelat Res* (2019) 477:1450-1458.
16. Lance E, Deutsch AL, Mink JH. Prior lateral patellar dislocation: MR imaging findings. *Radiology* 1993;189(3):905-907
17. Steensen RN, Dopirak RM, McDonald WG (2004) The anatomy and isometry of the medial patellofemoral ligament: implications for reconstruction. *Am J Sports Med* 32(6):1509-1513.
18. Pfirrmann CW, Zanetti M, Romero J, Hodler J. Femoral trochlear dysplasia: MR findings. *Radiology.* 2000;216(3):858-64.
19. Escala JS, Mellado JM, Olona M, Giné J, Saurí A, Neyret P. Objective patellar instability: MR-based quantitative assessment of potentially associated anatomical features. *Knee Surg Sports TraumatolArthrosc.* 2006;14(3):264-72.
20. Schoettle PB, Zanetti M, Seifert B, Pfirrmann CW, Fucntese SF, Romero J. The tibial tuberosity-trochlear groove distance: a comparative study between CT and MRI scanning. *Knee.* 2006;13(1):26-31.
21. McNally EG, Ostlere SJ, Pal C, Phillips A, Reid H, Dodd C. Assessment of patellar maltracking using combined static and dynamic MRI. *EurRadiol.* 2000;10(7):1051-55.

**Copyright:** © the author(s), 2020. It is an open-access article distributed under the terms of the Creative Commons Attribution License (CC BY 4.0), which permits authors to retain ownership of the copyright for their content, and allow anyone to download, reuse, reprint, modify, distribute and/or copy the content as long as the original authors and source are cited.

**How to cite this article:** Rana S, Basak I, Sarkar A, Karmakar M. Evaluation of Risk Factors in Congenital Patello-Femoral Instability by Magnetic Resonance Imaging. *Ann. Int. Med. Den. Res.* 2021; 7(2):RD10-RD13.

**Source of Support:** Nil, **Conflict of Interest:** None declared