

# A Prospective Comparative Study of Conventional Radiographs with MRI in the Diagnosis of Hip Pathologies

Ramesh Chander<sup>1</sup>, Sandeep Sohi<sup>2</sup>, Poonam Ohri<sup>3</sup>, N S Neki<sup>4</sup>, Tushar Bhagat<sup>5</sup>

<sup>1</sup>Professor & Head, Department of Radiodiagnosis, Government Medical College Amritsar, India-143001.

<sup>2</sup>Junior Resident, Department of Radiodiagnosis, Government Medical College Amritsar, India-143001.

<sup>3</sup>Associate Professor, Department of Radiodiagnosis, Government Medical College Amritsar, India-143001.

<sup>4</sup>Professor, Department of Medicine, Government Medical College Amritsar, India-143001.

<sup>5</sup>Final Prof MBBS, Government Medical College Amritsar, India-143001.

Received: January 2020

Accepted: January 2020

**Copyright:** © the author(s), publisher. It is an open-access article distributed under the terms of the Creative Commons Attribution Non-Commercial License, which permits unrestricted non-commercial use, distribution, and reproduction in any medium, provided the original work is properly cited.

## ABSTRACT

**Background:** Hip joint pain is a common complaint in the present day practice and could be due to various reasons, as the investigations are invariably used to come to a diagnosis of the cause of pain. Plain radiographs are used as primary investigation followed by MRI which is a valuable tool in the evaluation of hip disorders, because it enables accurate assessment of articular cartilage, epiphyses, joint fluid, bone marrow and extra-articular soft tissues that can be affected by hip disease. MR imaging is the modality of choice when clinical examination is suspect for hip disease and plain radiographs are normal or equivocal. Early diagnosis and treatment is important in many of the disorders. **Aims and Objectives:** 1. To compare the role of X-Ray with MRI. 2. To assess the severity and extent of the underlying lesion in various conditions of painful hip joint. **Methods:** 50 patients presenting with a history of hip pain in the OPD as well as indoor and being referred for X-Rays or MRI examination were examined. **Results:** Of the 50 cases the males (76%) are commonly affected than females (24%). Majority of the patients fall under the age group of 31-45 years (34%). In our study we find the commonest pathology for the hip joint pain is AVN of femoral head 20 cases (40%), followed by joint effusion 2 cases (4%), Osteoarthritis 2 cases (4%), TB hip 6 cases (12%), Perthes 2 cases (4%), DDH 2 cases (4%) and metastatic disease 3 cases (6%). Out of 20 cases of AVN, only 7 (35%) cases are detected on plain radiograph whereas all the 20 cases (100%) are diagnosed on MRI. Similarly out of 2 cases diagnosed as joint effusion only 1 case (50%) is detected on plain radiograph, but both the cases (100%) are detected on MRI. Out of the 6 cases of TB of hip joint 4 cases are detected on X ray and all the 6 cases detected on MRI. Similarly out of 10 cases of osteomyelitis 3(30%) cases detected on Xray and all 10(100%) cases are detected on MRI. Rest of the pathologies are detected 100% both on X-ray and MRI however, MRI helps in better delineation of articular cartilage, epiphyses and extra articular soft tissue abnormalities. **Conclusions:** The hip is a stable, major weight-bearing joint with significant mobility. In adults, hip pain may be caused by intraarticular disorders such as avascular necrosis, arthritis, joint effusion, tuberculosis and metastatic disease. In children common pathologies include DDH, Perthes disease and infections like tuberculosis. Plain radiography is a widely established, economical investigation readily available in all kinds of health setups for imaging the hip joint. Plain film radiography is used in the initial evaluation of any cause of hip pain. Plain film may not detect early pathologies like AVN, also cannot accurately characterize the articular cartilage pathology and soft tissue involvement. MRI of the hips should be performed early in patients with persistent pain and negative radiography findings. MR imaging is a valuable tool in the evaluation of hip disorders because it enables assessment of articular cartilage, epiphyses, joint fluid, bone marrow and extra-articular soft tissues structures that can be affected by hip disease. MRI is an imaging technique that does not require exposure to radiation. MR imaging is the modality of choice when clinical examination is suspect for hip disease and plain radiographs are normal or equivocal. Early diagnosis and treatment is important in many of the disorders.

**Keywords:** Plain radiograph, MRI, Hip joint, Tuberculosis of hip, Bone marrow edema, Arthritis, Perthes disease, DDH, Avascular necrosis of hip.

1

## INTRODUCTION

X-Ray, a form of Electromagnetic radiation passes through hip to create a two-dimensional picture of the bones that form the hip joint and gives

information about the joint alignment, joint space, bone spurs and bony structures. It is the initial investigation done when a patient presents with the pain in hip joint.

One of the most revolutionary advances in the field of medicine that has essentially changed the face of diagnosis especially in the diagnosis of hip pathologies is Magnetic Resonance Imaging (MRI). MRI is a valuable tool in the evaluation of hip disorders because it enables assessment of articular structures, extra-articular soft tissues, and the osseous structures that can be affected by hip

### Name & Address of Corresponding Author

Dr. Sandeep Sohi,  
Junior Resident,  
Department of Radiodiagnosis,  
Government Medical College Amritsar  
India-143001

disease.<sup>[1]</sup> Trauma, infection, arthritis, avascular necrosis, tumor, and hip dysplasia can all manifest with extremely subtle radiographic abnormalities.

The principal benefit of the true coronal and axial planes is that they provide symmetric, bilateral images, which can be important in the diagnosis and can greatly minimise the time required to evaluate both hips simultaneously. Normal hip anatomy can be routinely demonstrated on coronal and axial MR images. The femoral head, neck and the intertrochanteric region are best appreciated on coronal MR images. Axial MR images provide good visualization of the articular space, hip musculature, and supporting ligaments.<sup>[1]</sup>

MRI detects AVN in its early stages, thus allowing early treatment and prevention of subsequent bone destruction. MRI has been shown to be the most sensitive modality for imaging AVN.

MRI is becoming increasingly useful in the diagnosis and management of pediatric hip disorders. MRI offers several advantages that are especially important in the pediatric population. As much of the pediatric hip is cartilaginous, it is often not optimally imaged with other modalities such as plain radiography, ultrasound (US) (after 6 months of age), and computed tomography (CT). MRI is unique in its ability to depict cartilage and is, therefore, especially efficacious in the evaluation of the pediatric hip.<sup>[1]</sup>

A major concern in the juvenile hip is normal development, which is dependent on proper seating of the femoral head in the acetabulum. The position and shape of the femoral head should be precisely assessed with multiplanar MRI. Also, changes in bone marrow can be directly visualized with MRI as it is not possible with CT or US.

MRI has played an increasingly important role in the evaluation of the arthritis. The most common form of arthritis in children is juvenile rheumatoid arthritis (JRA). MRI is uniquely capable of depicting the soft-tissue abnormalities that occur in JR including synovial inflammation, joint effusion and articular cartilage destruction.

In patients of sarcoidosis with musculoskeletal complaints, MRI reveals marrow and soft-tissue lesions that are occult or underestimated on radiographs.

Most disorders classified as dysplasia can be readily diagnosed with plain radiography. Thus MRI is rarely employed in the routine work-up of patients with bone dysplasias.

MRI can be useful in the evaluation of a variety of hip disorders. Selecting imaging protocol is essential for maximizing the diagnostic potential of MRI in the work-up of hip diseases. Specific protocols that incorporate surface coil imaging, oblique image acquisition, and alternative pulse sequences are the foundation for successful hip studies. The use of GRE sequences is essential in the

evaluation of cartilaginous disorders, particularly in pediatric hip disease.<sup>[1]</sup>

Currently, MRI of the hip provides the best means for evaluating intra-articular pathology. However, radiography remains important for the diagnosis of subtle bony irregularities associated with femoroacetabular impingement. Therefore, a comprehensive imaging strategy requires conventional radiographs and MRI to evaluate pain in hip joint.

Though there has been a decade of imaging the hip joint with MRI, its role as an important imaging modality for patients with hip pathologies continues to evolve. In the last few years, advantages such as reduced scan time and better image quality have significantly widened the scope of MRI. MRI is a highly specific and sensitive technique for detecting a number of abnormalities involving the hip and surrounding tissues and hence should be the preferred choice after radiographs.

MRI has proved efficient in evaluation of primary musculoskeletal tumors, trauma, arthropathies, marrow replacement processes and osteomyelitis. Its excellent ability to evaluate bone marrow, soft tissue and joints has made it extremely valuable for diagnosing musculoskeletal infections. Latest research suggests that MRI of joints using diluted gadopentetate dimeglumine injected directly into the joint can be very helpful for evaluating the acetabular labrum.

Varied operative approaches and treatment strategies for different hip pathologies makes accurate preoperative diagnosis imperative. The limitations of X-Ray and CT scan in narrowing down the differential diagnosis of hip pathologies makes MRI the investigation of choice in such patients.

#### **Aims and Objectives:**

1. To compare the role of X-Ray with MRI in patients presenting with hip pain.
2. To assess the severity and extent of the underlying lesion in various conditions of painful hip joint.

### **MATERIALS & METHODS**

The study was conducted after approval from institutional thesis and ethical committee.

The main source of data for the study is patients presenting with a history of hip pain in the OPD as well as indoor and being referred for X-Rays or MRI examination at Guru Nanak Dev Hospital, Amritsar. In all cases, Informed consent was taken after explaining about and before any procedure. This study was conducted in the Department of Radiodiagnosis and Imaging, Government Medical College and Guru Nanak Dev Hospital, Amritsar from August 2017 to November 2019. 50 cases were selected from randomly referred patients to X-Ray

and MRI centre of Guru Nanak Dev Hospital, Amritsar.

#### **Selection criteria:**

- Non-traumatic clinically suspected cases: patients with unilateral or bilateral groin, buttock, thigh or knee pain, deformity or limitation of range of movements at hip joint.
- Traumatic clinically suspected cases: dislocation of hip, fracture head/neck of femur or fracture of acetabulum.

#### **Technique:**

**X-Ray:** Imaging was done with samsung/ DXMR machine

**MRI:** Imaging was done with 1.5 Tesla Siemens Magnetom symphony machine with the help of dedicated body coil.

The tests will be performed using following parameters.

- FOV – 350 to 400 (in adult) and 180 to 200 (in paediatrics)
- Slice thickness – 4 mm
- Matrix size – 512 x 512

The following sequences were obtained: spin-echo T1 weighted (coronal/transverse), PD FAT SAT (coronal/transverse), T2 weighted (oblique sagittal/transverse), T2 FAT SAT and inversion recovery (coronal) sequences of both hips.

## RESULTS

**Table 1: Pathology**

Sl. No	Pathology	No. of Patients	Percentage
1	AVN	20	40%
2	TB Hip	6	12%
3	Osteomyelitis	10	20%
4	Joint Effusion	2	4%
5	SCFE	2	4%
6	Tumors/Metastasis	3	6%
7	DDH	2	4%
8	Perthes disease	2	4%
9	OA	2	4%
10	Osteoporosis	1	2%
	TOTAL	50	100%

The above table bar diagram depict that 20 (40%) out of the total 50 patients has AVN, 6 (12%) patients TB hip, 10 (20%) patients osteomyelitis, 2 (4%) patients joint effusion, 2 (4%) patients SCFE, 3 (6%) patients tumor/metastasis, 2 (4%) patients DDH, 2 (4%) perthes, 2 (4%) patients OA and 1 (2%) patients osteoporosis.

#### **Avascular Necrosis of Femoral Head:**

Out of 50 cases, 20 (40%) cases are diagnosed as AVN of femoral head. In 20 cases of AVN only 7(35%) cases are detected on X-Ray but, all 20 (100%) cases are detected on MRI. 13 (65%) cases which are normal {stage 1 & stage 2 of FICATS

CLASSIFICATION} on X-Ray proved to have AVN on MRI.

Out of 7(35%) cases which are detected both on X-Ray and MRI, 6 (30%) cases which are detected as stage 2 on X-Ray (FICATS) shows stage 3 or more on MRI (MITCHELL'S). 1 (5%) case which is detected as stage 3 on X-Ray (FICATS) shows stage 4 on MRI (MITCHELL'S).

**Table 2: AVN**

AVN	On X-ray	On MRI
Total	35%	100%

**Table 3: X-Ray Findings**

X-ray findings	Number of patients	Percentage % (n=7)
Osteoporosis	7	100%
Sclerosis	3	42.8%
Subchondral cysts	4	57.1%
Crescent sign/subchondral lucency	3	42.8%
Altered morphology	3	42.8%

**Table 4: MRI Findings**

MRI Findings	Number of patients	Percentage % (n=20)
Osteoporosis	17	85%
Double line sign	16	80%
Subchondral Cysts	15	75%
Femoral head altered contour	3	15%
Femoral head fragmentation with collapse	3	15%

#### **TB of HIP Joint:**

Out of 50 cases, 6 cases (12%) shows TB of hip joint.

Out of 6 Cases of TB of hip joint, 4(66.6%) cases detected on X-Ray, whereas 6 (100%) cases detected on MRI. Out of 4 cases detected on X-Ray, stage 2 (1case), stage 3 (2 cases), stage 4 (1 case). Out of 6 cases detected on MRI shows stage 1 (1 case), stage2 (1 case), stage 3(1 case), stage 4(2 cases) & stage 5 (1 case).

**Table 5: TB HIP joint**

TB HIP JOINT	ON X-RAY	ON MRI
Total 6	4 (66.6%)	6 (100%)

**Table 6: X-Ray Findings**

X-Ray findings	Number of patients	Percentage % (n=4)
Osteopenia	4	100%
Joint effusion	1	25%
Soft tissue swelling	2	50%
Joint erosions and reduction of joint space	4	100%
Subchondral cysts	2	50%
Joint destruction & bony ankylosis	2	50%

**Table 7: MRI Findings**

MRI Findings	Number of patients	Percentage% (n=6)
Synovial hyperintensity on T2W	3	50%
Joint effusion	6	100%
Bone marrow edema	6	100%
Subarticular cysts	3	50%
Joint space reduction	6	100%
Joint destruction & bony ankylosis	2	33.33%
Soft tissue hyperintensity on T2W	2	33.33%

**Perthe's Disease:**

Out of 50 cases, 2 (4%) cases show Perthe's disease. Both 2 cases are detected on X-ray (100%) and MRI (100%).

**Table 8: X-Ray Findings**

X-Ray findings	Number of patients	Patients% (n=2)
Small epiphyses	1	50%
Complete resorption of epiphyses	1	50%

**Table 9: MRI Findings**

MRI Findings	Number of	Percentage % (n=2)
Epiphyseal hyperintensity on T2W	1	50%
Bone marrow edema	2	100%

**Osteoid Osteoma**

Out of the 50 cases, 1 case (2%) shows Osteoid Osteoma. The case is detected both on X-Ray (100%) and MRI (100%).

**Table 10: X-Ray Findings- Osteoid Osteoma**

X-Ray findings	No. of Patients	Percentage%(n=1)
Perostial reaction with cortical thickening	1	100%
Nidus	1	100%

**Table 11: MRI Findings- Osteoid Osteoma**

MRI findings	No. of Patients	Percentage%(n=1)
Bone marrow edema	1	100%
Synovial enhancement	0	0%
Nidus	1	100%

**Osteomyelitis:**

Out of the 50 cases, 10 cases (20%) are diagnosed with Osteomyelitis.

Out of 10 Cases of Osteomyelitis, 3(30%) cases detected on X-Ray, whereas all the 10 (100%) cases detected on MRI.

**Table 12: X-Ray Findings- Osteomyelitis**

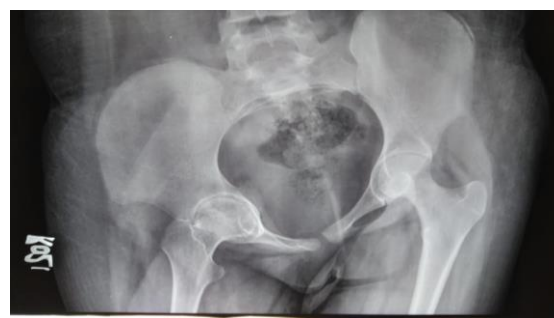X-Ray findings	No. of Patients	Percentage%(n=3)
Osteopenia	3	100%
Perostial reaction	0	0%
Focal bone lysis	2	66.67%
Peripheral sclerosis	3	100%
Sequestrum, Involucrum	0	0%
Joint destruction	1	33.3%

**Table 13: MRI Findings- Osteomyelitis**

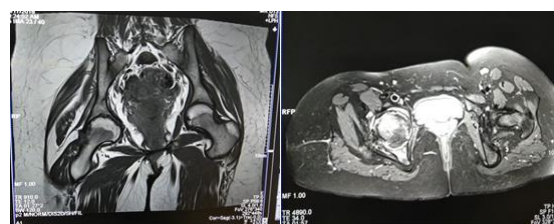MRI findings	No. of Patients	Percentage%(n=10)
Bone marrow edema	10	100%
Joint effusion	6	60%
Joint deformity	1	10%
Collections	4	40%

**Perthes Disease of Hip Joint**

A female patient aged 13 year complaining of right hip pain and a limp during walking.



**Figure 1: Plain X-Ray showing shortening of right limb (compare level of lesser trochanters) in keeping with a coxa magna deformity in this patient. Shows small epiphyseal size on right side with apparent increase in density of the epiphyses and blurring of physcal plate. Widening and flattening of femoral head and neck with thin sclerotic line running across femoral neck(Sagging Rope sign)**



**Figure 2: MRI Coronal image showing irregularity of the femoral head, asymmetrical femoral epiphysis and widening of joint space with the erosion of articular cartilage. Axial PDFS image showing hyperintensity in right femoral epiphysis suggestive of bone marrow edema**

Right Osteomyelitis and Left Psoas Abscess with Bilateral AVN

A 40 years old male patient complaining of bilateral hip pain, limping gait and history of fever.

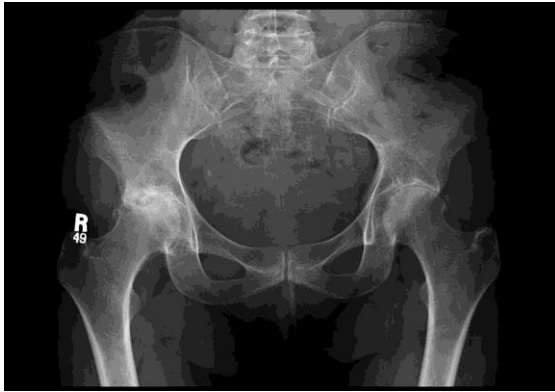

Figure 3: Plain X-ray shows joint space reduction in bilateral hip joint and sclerosis in bilateral femoral head with loss of normal contour of right femoral head

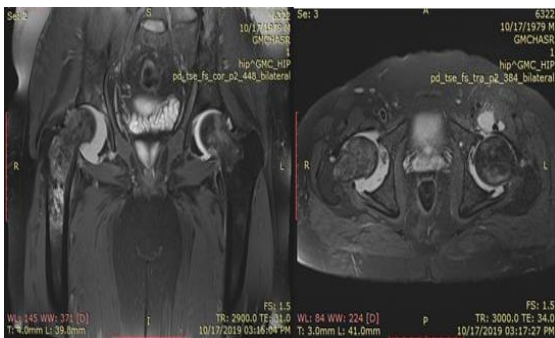


Figure 4: MRI coronal PDFS image shows subtle collapse and flattening of the right head along with subluxation leading to reduced joint space. Sclerosis and erosions seen in right femoral head. Mild joint effusion seen bilaterally, Altered signal intensity noted in right metadiaphyseal and upper shaft region of right femur. Articular cartilage erosion seen (R>L). Left femoral head shows double line sign suggestive of AVN. Collection noted in left psoas muscle.

**Bilateral AVN of Hip**

An 25 years old male patient complaining of chronic hip pain with limping gait.

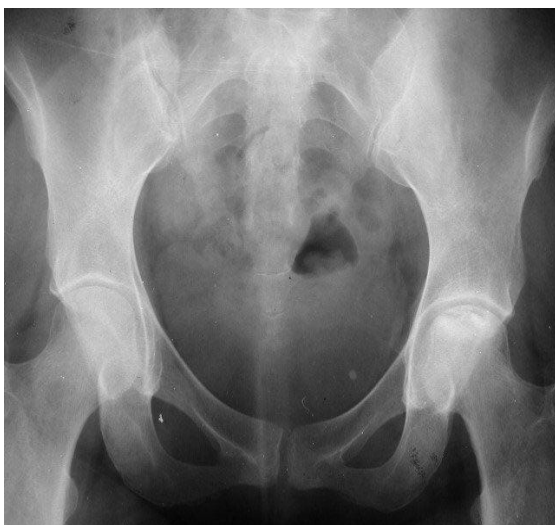

Figure 5: Plain X-Ray showing normal hip joints bilaterally with preserved joint space

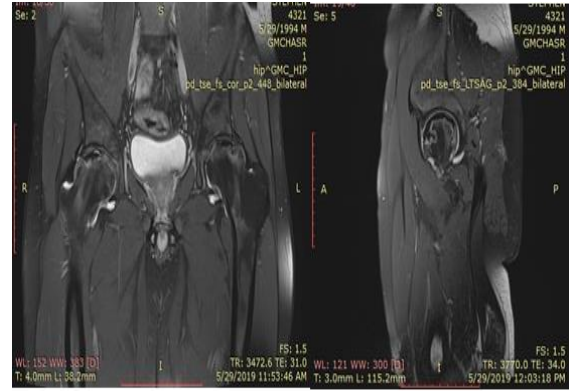


Figure 6: MRI CORONAL T2 FS image showing curvilinear hypointense outerline with hyperintense innerline representing double line sign, seen in bilateral hip joints. Mild bone marrow edema and joint effusion seen bilaterally. Sagittal image showing less than 30% involvement of femoral head. AVN stage 1 normal radiograph with abnormal MRI.

**Osteoid Osteoma of Left Hip Joint**

A 19 years old male patient complains of left hip pain worsening at night.

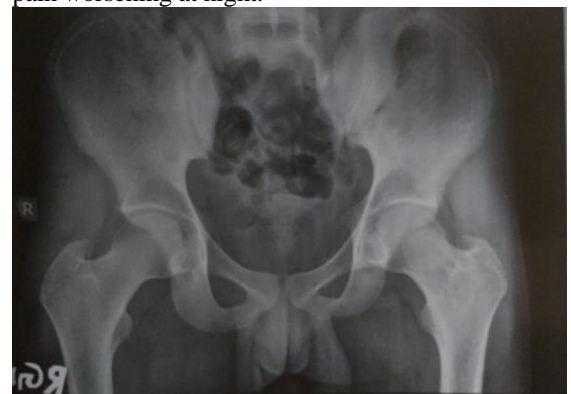

Figure 7: Plain X-ray shows well defined oval radiolucent nidus with cortical thickening in the intertrochanteric region of neck of left femur.

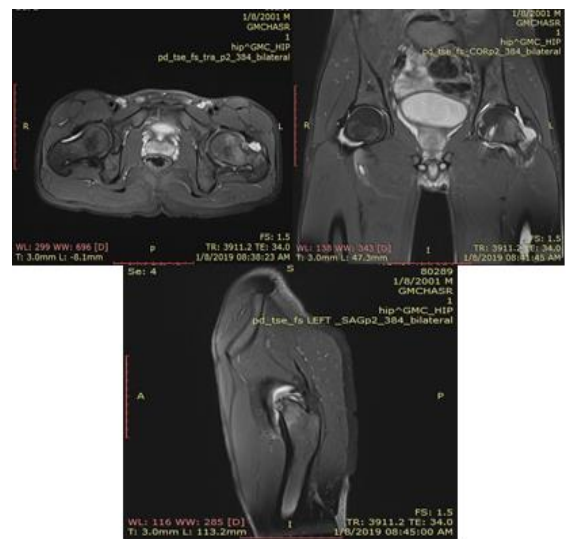

Figure 8: MRI axial, coronal sagittal PDFS image shows nidus in the left femoral neck with surrounding bone marrow edema and mild joint effusion.

## DISCUSSION

Plain radiography is a widely used, economical investigation readily available in all kinds of health setups for imaging the hip joint. Whereas MRI is an expensive, not readily available investigation at the level of primary health care centers.

However, MRI is the non-invasive gold investigation in early diagnosis, evaluate the extent of pathological involvement more accurately and narrow down the differential diagnosis.

Our study aims at the early detection of the disease before the appearance of signs on radiography or in patients having subtle findings on plain radiography by using MRI that helps the clinician to treat the patient at the early stages to prevent the further progression of disease.

It also aims at the accurate staging of the disease and assesses the extent of involvement of the pathology in cases which are already detected on X-Ray, using MRI to guide the clinician in appropriate treatment according to the stage of involvement of pathology.

Our discussion also proves MRI as gold standard in evaluation of soft tissue and articular cartilage which are having limitations for the detection of pathology on plain radiography.

### Avascular necrosis of femoral head:

In our study, AVN of femoral head is the commonest hip pathology.

In 20(40%, n=50) cases of AVN diagnosed on MRI only 7 (14%, n=50) cases are identified on plain radiography.

Out of 7(33.3%, n=20) cases diagnosed on plain X-Ray, 4 (20%, n=20) cases are showing subchondral cysts, osteoporosis suggestive of stage 1 AVN (FICATS staging). Other 3 (15%, n=20) cases are showing crescent sign, altered head morphology and osteoporosis suggestive of stage 2 AVN (FICATS staging).

Of 20 cases detected on MRI 17(85%, n=20) cases show bone marrow edema, reveals it is the common feature seen and can be detected only on MRI whereas X-Ray has its limitation in diagnosing Bone marrow edema.

On MRI 16(80%, n=20) cases shows double line sign i.e., on T2W sequences inner bright line representing granulation tissue and outer dark line suggestive of sclerotic bone.

13 (65%, n=20) cases diagnosed as normal or stage 1 (FICATS) on plain X-Ray shows stage 1 or 2 changes on MRI.

Of 7(35%, n=20) cases detected on plain X-Ray 2 (10%, n=20) cases are staged as stage 2 (FICATS) which shows stage 3 (MITCHELLS) giving fluid signal intermediate signal on T1W and T2W shows bright signal. 4 (20%, n=20) cases which are staged as stage 2 (FICATS) shows stage 4 on MRI (MITCHELLS) giving fibrosis signal, dark on both T1W and T2W sequences, reveals that MRI

evaluates better than X-Ray in staging and assess the extent of the pathological involvement in already proven cases of AVN on plain radiography that helps in appropriate treatment plan by the clinician based on the stage of AVN.

Our study is compared to the study done by Robinson HJ Jr. et.al 52 in which 23 of the 96 hips that were suspected of having early-stage necrosis of the femoral head but showed slight or no radiographic changes were studied by repeat radiographs. Of the 23 hips, 18 (78 per cent) had positive changes on magnetic resonance imaging; In our study out of 20 hips MRI detects 20 cases (100%), whereas radiography detects only 7 cases (35%).

### Osteoarthritis:

In our study, 2(4%, n=50) cases are diagnosed as osteoarthritis.

Both the cases are detected both on plain X-Ray and MRI.

Out of 2 cases on plain X-Ray, 1(50%, n=2) cases shows stage 1 (Kellgren and Lawrence staging) that is possible narrowing of joint space and possible osteophytes.

1(50%, n=2) cases showing stage 2 that is definite narrowing of joint space inferiorly, minimal sclerosis and osteophytes.

Out of 2 cases detected on MRI, 1(50%, n=2) cases show stage 2 (Higgs and Aiesen staging) that is inhomogeneity of articular cartilage high signal on T2W sequences and indistinct trabeculae or signal intensity loss in femoral head & neck on T1W sequences.

1(50%, n=2) cases show stage 3 that is having criteria of stage 1&2 as mentioned above and indistinct zone between femoral head & acetabulum, subchondral signal loss due to bone loss.

1 (50%, n=2) cases showing stage 1 on X-Ray shows stage 2 on MRI.

1 (50%, n=2) cases showing stage 2 on X-Ray shows stage 3 on MRI.

Thus, MRI reveals better delineation of cartilage destruction and reveals accurate pathological involvement and staging of osteoarthritis which helps in appropriate plan of treatment or intervention by the clinician.

### Tuberculosis of hip joint:

In our study 6(12%, n=50) cases are diagnosed as TB of hip joint.

4 (66.6%, n=6) cases are diagnosed on plain X-Ray. Among which, 1 (25%, n=4) case shows only osteopenia, joint effusion and soft tissue swelling.

4 (100%, n=4) cases shows along with osteopenia, marginal joint erosions and diminution of joint space. 2(50%, n=4) cases show osteopenia, joint erosions, joint space reduction and subchondral cysts.

2(50%, n=4) case shows joint destruction and bony ankylosis.

All 6 cases are diagnosed on MRI (100%, n=6)  
Among which, 3 (50%, n=6) case shows only synovial T2W hyperintensity and joint effusion in the form of high signal intensity within the joint space in T2W and STIR sequences, that is diagnosed as normal on plain X-Ray.

It reveals the importance of MRI in early detection of TB where plain X-Ray remains normal in spite of strong clinical suspicion.

3(50%, n=6) case shows synovial hyper intensity, joint effusion and bone marrow edema as high signal intensity within the marrow on STIR sequence.

3(50%, n=6) case shows sub articular T2 hyper intense cysts and joint space reduction.

2(33.33%, n=6) cases show joint deformity along with bone marrow edema, joint space reduction and para articular soft tissue hyperintense signal on T2W.

2(33.33%, n=6) case shows marked joint destruction and bony ankylosis seen as hypo intensity on both T1W and T2W and para articular soft tissue involvement also.

Thus, MRI helps in better delineation of synovial involvement and detection of joint effusion in early stages of TB Hip where plain X-Ray has limitation in diagnosis.

MRI also helps in detection of bone marrow edema in early stages of TB Hip.

In diagnosed cases on plain X-Ray, MRI helps in better evaluation of the extent of the articular cartilage destruction and also para articular soft tissue involvement.

#### **Perthes disease:**

In our study 2(4%, n=50) cases are diagnosed as Perthes disease.

The 2 cases are diagnosed both on X-Ray and MRI(100%, n=2).

#### **On plain X-Ray**

1(50%, n=2) case shows cessation of femoral epiphyseal growth in the form of small epiphyses.

1(50%, n=2) case shows complete resorption of femoral epiphyses in healed/residual stage.

#### **On MRI**

1(50%, n=2) case showing only cessation of femoral epiphyses growth on plain X-Ray, shows epiphyseal abnormality in the form of T1 Hypointensity, T2W hyperintensity and bone marrow edema in the form of PDFS hyperintensity and metaphyseal T2W hyperintensities.

Our study is compared to the study done by Toby EB, Koman LA, Bechtold RE<sup>51</sup> in the assessment of pediatric hip disease by scanning the hips of 24 children (30 scans). Twelve patients with Legg-Calvé-Perthes disease (17 hips) showed characteristic areas of low-intensity signal representative of necrotic areas of the capital epiphysis. In our study both the cases are showing

small epiphyses which are hypointense on T1W and hyperintense on T2W.

Thus, MRI helps in better evaluation of femoral epiphyses along with detection of bone marrow edema on STIR sequence.

#### **Developmental dysplasia of hip (DDH):**

In our study 2(4%, n=50) cases are diagnosed as DDH.

2 case is diagnosed both on plain X-Ray and MRI (100%, n=2).

1(50%, n=2) case shows displacement of femoral epiphyses lateral to the Perkin's line but, inferior to the Hilgenrein's line.

On MRI the same case shows along with the displacement of epiphyses, hyperintensity of the epiphyses on T2W and bone marrow edema as hyperintensity on STIR sequence.

1(50%, n=2) case shows complete femoral head dislocation with broken Shenton's line and epiphyses displaced superior to the acetabular rim.

On MRI along with the displacement of epiphyses, dislocation of femoral head it shows small epiphyses and hypointense epiphyses on both T1W & T2W.

Thus, X-Ray remains as the first line of investigation to diagnose DDH.

However, MRI helps in better evaluation of epiphyses & femoral head pathological involvement and also to detect associated bone marrow edema, along with evaluation of displacement of epiphyses and femoral head.

#### **Metastasis:**

In our study 1(2%, n=50) cases of metastasis to the hip joint diagnosed.

The case is diagnosed both on plain X-Ray and MRI (100%, n=1).

1(100%, n=1) case shows osteoblastic lesions and sclerosis within the femoral head on plain X-Ray.

On MRI it shows altered contour of femoral head and altered signal intensity in the form of hyperintense signal on T2W sequence with associated para articular soft tissue involvement in the form of hyperintense signal on T2W sequence.

Thus, MRI lies superior in the evaluation of metastatic lesions by not only detecting the abnormal signal intensity lesions, also evaluates the cartilaginous and the extent of soft tissue involvement accurately, which helps in the appropriate treatment plan.

#### **Osteoid osteoma:**

In our study 1(2%, n=50) cases of Osteoid Osteoma to the hip joint diagnosed.

The case is diagnosed both on plain X-Ray and MRI (100%, n=1).

1(100%, n=1) case shows oval radiolucent nidus with cortical thickening in the inter-trochanteric region of neck of left femur.

On MRI it shows nidus in the left femoral neck with surrounding bone marrow edema on T2FS sequence. Moderate amount of joint effusion is also seen. Thus, MRI lies superior in the evaluation of Osteoid Osteoma by accurately detecting the nidus with surrounding bone marrow edema and joint effusion.

#### **Osteomyelitis:**

Out of the 50 cases, 10 cases (20%) are diagnosed with Osteomyelitis.

Out of 10 Cases of Osteomyelitis, 3(30%) cases detected on X-Ray, whereas all the 10 (100%) cases detected on MRI.

Out of 3 cases detected on X-Ray, 01 cases (33.3%, n=3) shows joint space reduction in the right hip with sclerosis and loss of contour of right femoral head. In the 02 cases (66.67%, n=3), there is a lytic lesion with peripheral sclerosis and juxta articular osteopenia. In 01 case (33.3%, n=3), joint destruction is seen.

Out of 10 cases detected on MRI, 6 cases(60%, n=10) show increased signal intensity on T2WI/PD in the involved areas of the hip joint which on contrast administrations show heterogenous enhancement.

4 cases (40%, n=10) shows areas of cortical breach/lysis in the involved areas with sinuses communicating with adjacent/overlying muscles.

2 cases (20%, n=10) also shows periosteal reaction in the involved areas.

01 case (10%, n=10) shows destruction of the hip joint. Well defined Collections which show peripheral enhancement on contrast are seen in 04 cases(40%, n=10), out of which 02 collections are seen to be communicating with the hip joint.

Thus, MRI helps in better delineation of bone marrow edema, cortical bone destruction and periosteal/adjacent soft tissue collections.

#### **Subcapital Femoral Epiphyses of Hip Joint (SCFE):**

Out of the 50 cases, 02 cases (4%) are diagnosed with SCFE.

Both the cases were detected on X-Ray and MRI.

One case detected on X-Ray shows the subluxation/slip of the metaphyses over the epiphyses and widening of growth plate with irregularity of physal edges along with decreased epiphyseal height.

On MRI, this case shows low signal on T1WI with metaphyseal displacement and high signal intensity in epiphyses and metaphyses on T2 with joint effusion

The other case detected on X-Ray shows only mild subluxation/slip of the metaphyses over the epiphyses.

On MRI, this case shows bone marrow edema, subtle physal widening and irregularity suggestive of pre slip stage.

Our theory is compared to the study done by Khaladkar SM et al that shows MRI detects early

physal changes of both preslip and SCFE even when radiographs and computed tomography are normal. MRI should be routinely used to diagnose early SCFE in preslip stage to avoid further complications.

#### **Transient Osteoporosis of Hip Joint (TOH):**

Out of the 50 cases, 01 case (2%, n=50) diagnosed with Transient Osteoporosis (TOH).

In our study 1(2%, n=50) case of TOH is diagnosed.

On X-Ray, subtle osteopenia is seen in left femoral head and neck, however joint space is preserved.

On MRI, there is decreased signal intensity with loss of normal fatty marrow signal on T1WI. T2WI shows high signal intensity in the involved area. Mild joint effusion is seen, however Joint space is preserved.

Radiographs are frequently unremarkable, but may reveal subtle periarticular osteopenia. There is no radiographic evidence of demineralization during the early phase of syndrome, as a result advanced imaging is required. Magnetic resonance imaging is the most sensitive and predictable test for an early diagnosis and monitoring of disease progression.

## CONCLUSION

In our study total 50 cases complaining of acute and chronic hip pain underwent both plain radiography and MRI consecutively. Maximum number of patients are between the age group of 31-45(34%), followed by the age group of 16-30(26%). Out of 50 cases 38 (76%) are males and 12(24%) are females thus, showing male preponderance.

In our study of 50 cases, 20 cases are diagnosed as AVN, 10 cases as Osteomyelitis, 2 cases showing Joint effusion, 2 cases showing Osteoarthritis, 6 cases as TB Hip, 2 cases as DDH, 2 cases Perthe's, 3 cases showing Metastatic disease/tumors to Hip joint, 2 cases of SCFE and 1 case of Osteoporosis..

Out of 20 cases diagnosed as AVN only 6(33.3%) cases are diagnosed on plain radiography, where as all the 20 cases are diagnosed on MRI which shows MRI is more sensitive for the detection of AVN even in early stages where plain radiography shows normal or subtle findings. MRI also helps in detection of bone marrow edema for which plain radiography shows its limitation in detection. In proven cases of AVN on plain radiography the MRI helps in accurate staging of the disease that helps in appropriate treatment plan by the clinician.

Out of 2 cases showing the joint effusion only 1(50%) cases are diagnosed on plain radiography showing widened tear drop distance, where as both the cases (100%) are diagnosed on MRI. Thus, it reveals the higher sensitivity of MRI in detection of joint effusion.

2 cases show osteoarthritis though, both the cases are detected on plain radiography as well as MRI, MRI reveals better delineation of cartilage



destruction, accurate pathological involvement and staging of osteoarthritis.

6 cases are diagnosed as TB Hip. Plain radiography helps in detection of obvious findings such as joint space reduction, altered contour of the articular surface, osteopenia and joint destruction. MRI adds to the findings of the plain X-Ray by detection of minimal joint fluid collection, hyperintensity of the articular cartilage which will be the only finding in the very early stage of TB Hip. MRI also helps in detection of bone marrow edema, better delineation of the extent of the articular cartilage destruction and proper delineation of the para articular soft tissue involvement.

2 cases show DDH. Plain X-Ray showing imaginary lines like Perkin's line, Hilgenrein's line and Shenton's line are highly useful in diagnosing the displacement of epiphyses and dislocation of Hip joint.

2 cases show Perthe's disease. Even in Perthe's disease plain radiography helps to detect the evaluation of cessation of epiphyseal growth in the form of small epiphyses. Also it helps in evaluation of resorption of femoral head. However, MRI helps in detection of the early stages of DDH and Perthe's by showing the involvement of epiphyses in the form of T2W hyperintensity before the actual displacement of epiphyses is noted. It also helps in evaluation of bone marrow edema.

1 case show metastasis to the Hip joint. Plain X-Ray detects well defined osteolytic lesions and also osteoblastic lesions. But, MRI helps in the evaluation of the involvement articular cartilage in the form of T2W hyperintensity. It also helps in evaluation of soft tissue involvement along with detection of bone marrow edema.

1 cases show Osteoid Osteoma of left Hip joint. Plain X-Ray detects radiolucent nidus with cortical thickening. But, MRI helps in the evaluation of the bone marrow edema and joint effusion along with the nidus in the left femoral neck.

10 cases are diagnosed as Osteomyelitis. Plain radiograph helps in detection of joint space reduction, juxta articular osteopenia and joint destruction. MRI adds to the findings of the plain X-Ray by detection of mild joint effusion, better delineation of bone marrow edema, cortical bone destruction and perosteal/adjacent soft tissue collections.

Hip is a stable, major weight-bearing joint with significant mobility. Different Hip pathologies are encountered in adults and children. In adults, avascular necrosis, arthritis, joint effusion, tuberculosis and metastatic disease are commonly seen. In children common pathologies include DDH, Perthe's disease and infections like tuberculosis. Imaging modalities used to evaluate hip pain and the appropriateness of particular studies in different clinical scenarios should be considered. The history and physical examination, play a key role to develop

a differential diagnosis prior to the selection of imaging tests.

Plain radiography is a widely established, economical investigation readily available in all kinds of health setups for imaging the hip joint. Plain film radiography is used in the initial evaluation of any cause of hip pain, including suspected avascular necrosis, arthritis, infection, dysplasia, and tumor. Plain film may not detect early pathologies like AVN, also cannot define the articular cartilage pathologies and soft tissue involvement.

In the setting of chronic hip pain, a normal-appearing radiograph, a nonspecific history and clinical findings can be a difficult diagnostic dilemma. MRI is a valuable tool in the evaluation of hip disorders because it enables assessment of articular structures, extra-articular soft tissues, and the osseous structures that can be affected by hip disease. MRI is an imaging technique that does not require exposure to radiation. MRI of the hips should be performed early in patients with persistent pain and negative radiography findings.

MRI is becoming increasingly useful in the diagnosis and management of pediatric hip disorders. MRI offers several advantages that are especially important in the pediatric population. Because much of the pediatric hip is cartilaginous, it is often not optimally imaged with plain radiography. Most disorders classified as dysplasia can be readily diagnosed with MRI; thus, MRI is commonly employed in the routine work-up of patients with bone dysplasias.

MRI is performed to detect AVN in its early stages, thus allowing early treatment and prevention of subsequent bone destruction. MRI has been shown to be the most sensitive modality for imaging AVN. MRI is uniquely capable of depicting the soft-tissue abnormalities that occur in arthritis, including synovial inflammation, joint effusion, and articular cartilage destruction.

Joint effusion and synovial proliferation can be identified better by MRI than by conventional radiography. In proven cases on plain radiography like Perthe's and metastatic disease of Hip, MRI helps in better staging of the disease, extent of pathological involvement and soft tissue extension. MRI is extremely sensitive to alterations in the bone marrow that may represent pathology occult to plain radiography of the hip.

## REFERENCES

1. Ragab Y, Emad Y, Abou-Zeid A. Bone marrow edema syndromes of the hip: MRI features in different hip disorders. *Clinical rheumatology*. 2008;27(4):475-82.
2. Pfirrmann CW, Duc SR, Zanetti M, Dora C, Hodler J. MR arthrography of acetabular cartilage delamination in femoroacetabular cam impingement1. *Radiology*. 2008;249(1):236-41.
3. Boniatis I, Costaridou L, Cavouras D, Kalatzis I, Panagiotopoulos E, Panayiotakis G. A morphological index for assessing hip osteoarthritis severity from radiographic

- images. The British journal of radiology. 2008;81(962):129-36.
4. Mamisch TC, Zilkens C, Siebenrock KA, Bittersohl B, Kim YJ, Werlen S. MRI of hip osteoarthritis and implications for surgery. Magnetic Resonance Imaging Clinics. 2010;18(1):111-20.
  5. Stoica Z, Dumitrescu D, Popescu M, Gheonea I, Gabor M, Bogdan N. Imaging of avascular necrosis of femoral head: familiar methods and newer trends. Current health sciences journal. 2009;35(1):23.
  6. Sankey RA, Turner J, Lee J, Healy J, Gibbons CE. The use of MRI to detect occult fractures of the proximal femur: a study of 102 consecutive cases over a ten-year period. The Journal of bone and joint surgery. British volume. 2009;91(8):1064-8.
  7. Roemer FW, Hunter DJ, Winterstein A, Li L, Kim YJ, Cibere J, Mamisch TC, Guermazi A. Hip Osteoarthritis MRI Scoring System (HOAMS): reliability and associations with radiographic and clinical findings. Osteoarthritis and cartilage. 2011;19(8):946-62.
  8. Gemmel F, Van der Veen HC, Van Schelven WD, Collins JM, Vanneville I, Rijk PC. Multi-modality imaging of transient osteoporosis of the hip. Acta Orthopaedica Belgica. 2012;78(5):619.
  9. Toby EB, Koman LA, Bechtold RE. Magnetic resonance imaging of pediatric hip disease. Journal of pediatric orthopedics. 1985;5(6):665-71.
  10. Robinson JH, Hartleben PD, Lund G, Schreiman J. Evaluation of magnetic resonance imaging in the diagnosis of osteonecrosis of the femoral head. Accuracy compared with radiographs, core biopsy, and intraosseous pressure measurements. The Journal of bone and joint surgery. American volume. 1989;71(5):650-63.
  11. Szwedowski D, Nitek Z, Walecki J. Evaluation of transient osteoporosis of the hip in magnetic resonance imaging. Polish journal of radiology. 2014;79:36.
  12. Pugmire BS, Shailam R, Gee MS. Role of MRI in the diagnosis and treatment of osteomyelitis in pediatric patients. World journal of radiology. 2014;6(8):530.
  13. Khaladkar SM, Sherawat P, Jantre MN, Thakkar DK, Kulkarni V M. Early diagnosis of slipped capital femoral epiphysis on magnetic resonance imaging: A case report with review of literature. Med J DY Patil Univ 2015;8:72-6
  14. Pierce TP, Jauregui JJ, Cherian JJ, Elmallah RK, Mont MA. Imaging evaluation of patients with osteonecrosis of the femoral head. Current reviews in musculoskeletal medicine. 2015;8(3):221-7.
  15. Manenti G, Altobelli S, Pugliese L, Tarantino U. The role of imaging in diagnosis and management of femoral head avascular necrosis. Clinical Cases in Mineral and Bone Metabolism. 2015;12(Suppl 1):31.
  16. Haubro M, Stougaard C, Torfing T, Overgaard S. Sensitivity and specificity of CT-and MRI-scanning in evaluation of occult fracture of the proximal femur. Injury. 2015;46(8):1557-61.
  17. Gayana S, Bhattacharya A, Sen RK, Singh P, Prakash M, Mittal BR. F-18 fluoride positron emission tomography/computed tomography in the diagnosis of avascular necrosis of the femoral head: Comparison with magnetic resonance imaging. Indian journal of nuclear medicine: IJNM: the official journal of the Society of Nuclear Medicine, India. 2016;31(1):3.
  18. Collin D, Geijer M, Göthlin JH. Computed tomography compared to magnetic resonance imaging in occult or suspect hip fractures. A retrospective study in 44 patients. European radiology. 2016;26(11):3932-8.
  19. Agrawal K, Tripathy SK, Sen RK, Santhosh S, Bhattacharya A. Nuclear medicine imaging in osteonecrosis of hip: Old and current concepts. World journal of orthopedics. 2017 Oct 18;8(10):747.
  20. Singhania A, Dhande R, Gupta S, Singhania S, Jain S sensitivity of MRI in evaluation of pain of hip joint. IJRSM 2018; 4(02): 071-5.
  21. The Hip Joint: Part One By Tracy Anderson <http://www.lfonline.com/HIPJOINT.pdf>.

**How to cite this article:** Chander R, Sohi S, Ohri P, Neki NS, Bhagat T. A Prospective Comparative Study of Conventional Radiographs with MRI in the Diagnosis of Hip Pathologies. Ann. Int. Med. Den. Res. 2020; 6(2):RD08-RD17.

**Source of Support:** Nil, **Conflict of Interest:** None declared