

# Papillary Cystadenocarcinoma of Salivary Gland: Report of a Diagnostic Pitfall and Literature Review

Zachariah Chowdhury<sup>1</sup>, Jaya Mishra<sup>2</sup>, Neizekhotuo Brian Shunyu<sup>3</sup>

<sup>1</sup>Assistant Professor, Department of Pathology, North Eastern Indira Gandhi Regional Institute of Health & Medical Sciences, Shillong, India

<sup>2</sup>Associate Professor, Department of Pathology, North Eastern Indira Gandhi Regional Institute of Health & Medical Sciences, Shillong, India

<sup>3</sup>Associate Professor, Department of Otorhinolaryngology, North Eastern Indira Gandhi Regional Institute of Health & Medical Sciences, Shillong, India.

Received: June 2020

Accepted: June 2020

## ABSTRACT

Papillary cystadenocarcinoma (PCA) is a rare low-grade malignant tumor of the salivary gland which usually affects major salivary glands such as parotid. It is predominantly cystic often exhibiting intraluminal papillary growth. We report a case of PCA arising from the parotid gland in the right cheek of a 67-year old female patient. A prior punch biopsy from the lesion was performed, on the histopathological examination of which a diagnosis of mucoepidermoid carcinoma was tendered. Conservative right-sided parotidectomy with right supraomohyoid neck dissection was performed which however revealed features of PCA with multiple lymphovascular emboli and invasion into the interlobular septa and surrounding tissue, as well as lymph node metastasis. Low-grade PCA is a clinicopathologically distinctive salivary gland neoplasm, with histologic features unlike those of other papillary salivary gland tumors. Distinguishing this entity from mucoepidermoid carcinoma is critical because it necessitates less radical surgery and has a better prognosis. A high index of suspicion is desired to discern incidental squamous metaplasia sometimes seen in PCA from the neoplastic squamoid component of mucoepidermoid carcinoma. However, there have been several reports indicating that PCA may be more aggressive than conventionally thought with higher grade pathological features. Supraomohyoid neck dissection is recommended for cases presenting with neck lymph node metastasis because the prognosis of these cases has found to be poor.

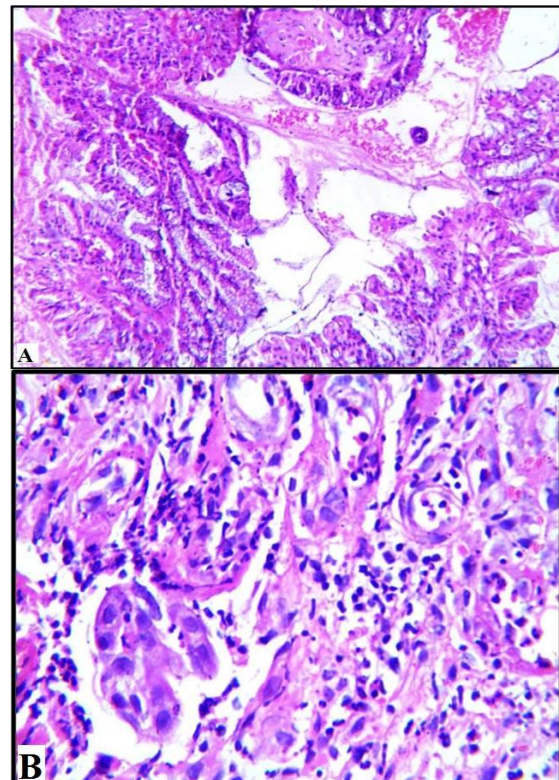
**Keywords:** Cystadenocarcinoma, Histopathology, Parotid, Salivary Gland Neoplasm, Squamous.

## INTRODUCTION

Papillary cystadenocarcinoma (PCA) is a rare low-grade malignant tumor of the salivary gland accounting for about 2% of all salivary gland tumors. It was first defined in 1991 by the World Health Organisation as a separate entity and further reclassified as cystadenocarcinoma in 2005.<sup>[1-3]</sup> In the more recent 2017 classification, cystadenocarcinoma and mucinous adenocarcinoma have been lumped under adenocarcinoma, not otherwise specified (NOS). Such revisions in classifications and potential confusion are further confounded by archival synonyms, including mucus-producing adenopapillary carcinoma, low-grade papillary adenocarcinoma, and malignant papillary cystadenoma. PCA is a distinct group of epithelial malignancy characterized by cystic and solid areas with luminal papillary projections, but lacking features that characterize cystic variants of several more common salivary gland carcinomas: polymorphous low-grade adenocarcinoma, mucoepidermoid carcinoma, and the papillary cystic variant of acinic cell carcinoma.<sup>[1,4,5]</sup> We report a case of PCA arising from the right-sided parotid

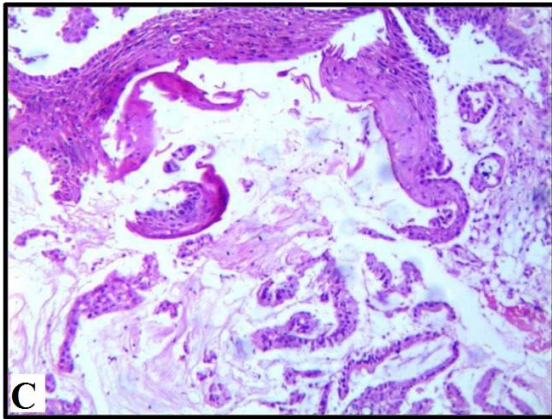
gland of a 67-year old female patient, and discuss herein the associated diagnostic pitfalls, especially on small biopsies.

## CASE REPORT

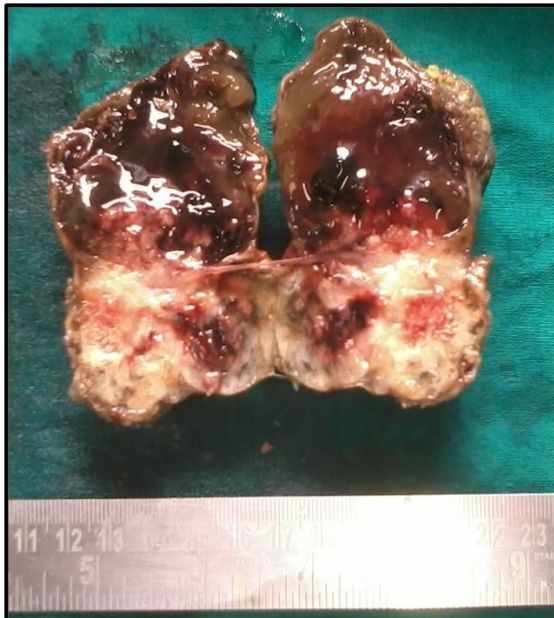


### Name & Address of Corresponding Author

Dr. Zachariah Chowdhury,  
Assistant Professor,  
Department of Pathology,  
North Eastern Indira Gandhi Regional Institute of Health &  
Medical Sciences,  
Shillong, India.



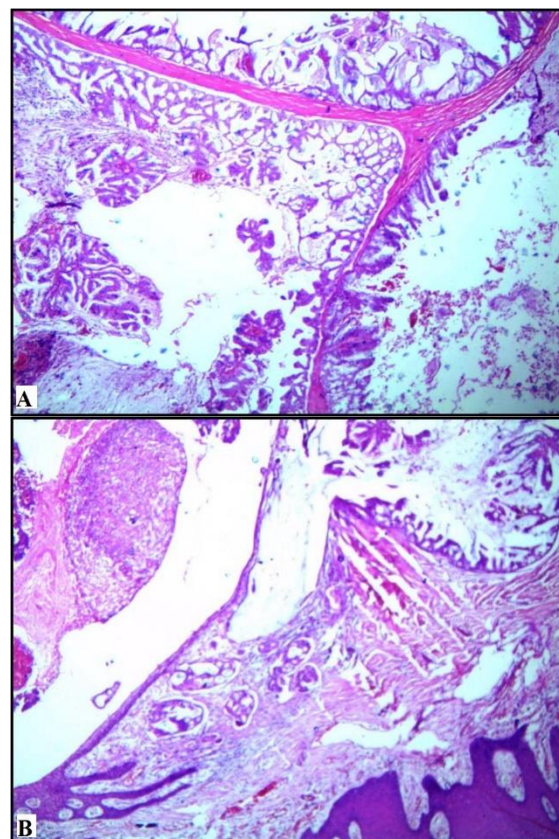
**Figure 1:** (A) Histopathological examination of the punch biopsy specimen showing the tumor composed of mucin-filled cysts lined by columnar mucous cells with vague papillary architecture. (B) Infiltration of the stroma by atypical epithelial cells, and (C) squamous components, both of these mistaken for squamoid elements of mucoepidermoid carcinoma. H & E, (A) 10X, (B) 40X, (C) 10X.

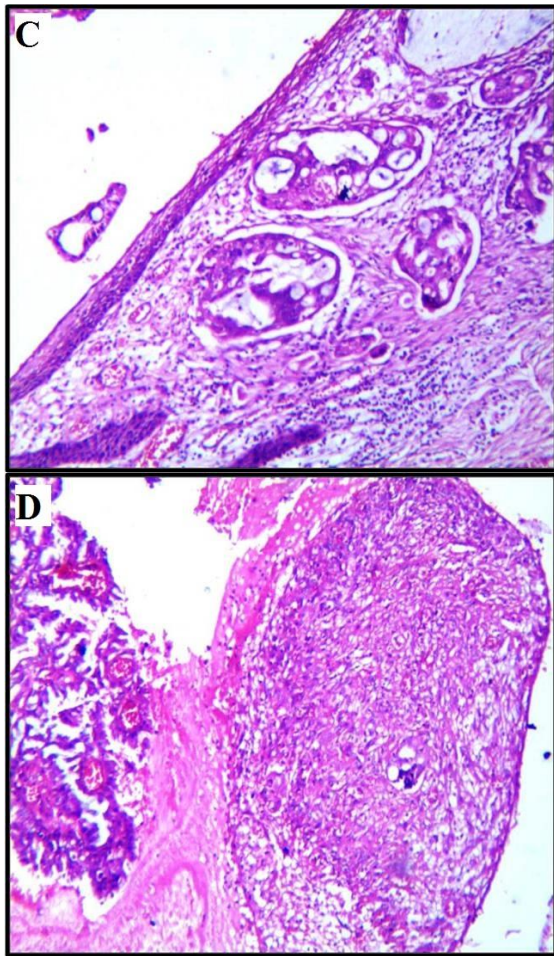


**Figure 2:** Gross specimen exhibiting a well-circumscribed unencapsulated mass comprising partly solid and cystic areas containing mucoid jelly-like material on cut section.

A 67-year-old female presented with a swelling in the right cheek, which she noticed 6 months back. The swelling began as a pea-sized growth on the inner side of the cheek, which reached the present size within 1 month. It was associated with pain on and off. On examination, there was a firm swelling measuring 6x5 cm in size over the right cheek along with cervical lymphadenopathy. X-Ray imaging study revealed a soft tissue mass lesion in the right parotid region without any erosion of the surrounding bony structures. Punch biopsy from the lesion was undertaken, histopathological examination (HPE) of which revealed haphazardly dispersed mucin-filled cysts lined by columnar

mucous cells, along with squamous components. Few areas of vague papillary architecture were discerned accompanied by infiltration of stroma by atypical epithelial cells. A diagnosis of mucoepidermoid carcinoma was proffered [Figure 1]. The patient underwent superficial conservative parotidectomy with right supraomohyoid neck dissection. Macroscopic examination of the main lesion disclosed a partial skin covered well-circumscribed globular soft tissue mass measuring 7x6x4 cm. The cut section revealed partly solid and cystic areas, which contained mucoid jelly-like material [Figure 2]. A total of 14 lymph nodes was dissected out from the neck dissection specimen. HPE of the salivary gland specimen divulged a subepithelial unencapsulated tumor comprising variably sized mucin-filled cysts with intraluminal well-defined papillary proliferation. The cyst lining was mostly degenerated with other areas of columnar cells exhibiting moderate nuclear atypia and pseudostratification. The tumor showed invasion into the interlobular septa and the surrounding tissue, along with multiple lymphovascular emboli and areas of necrosis. Squamous metaplasia of the duct lining was noted, without any evidence of neoplastic squamous elements. Tumor metastasis to a matted lymph node was detected as well. The case was finally diagnosed as papillary cystadenocarcinoma with lymph node metastasis [Figure 3]. Considering the fact that PCA is a low-grade malignancy, no adjunctive therapy was required. After 20 months of follow-up, there has been no sign of recurrence.





**Figure 3: Histopathological examination of the resected specimen disclosing a subepithelial unencapsulated tumor consisting of variably sized mucin-filled cysts lined by columnar cells with intraluminal well-defined papillary proliferation (A), and invasion into the interlobular septa and the surrounding tissue (B). Squamous metaplasia of the duct lining was noted at places (C) along with few necrotic areas (D). H & E, (A, B) 10X, (C, D) 20X.**

## DISCUSSION

Salivary gland tumors account for 1-6% of all neoplasms of the head and neck and have a diverse origin and pathology. Up to 80% of the minor salivary glands masses are malignant, whereas the vast majority of major salivary gland tumors are benign.<sup>[6]</sup> Papillary cystadenocarcinoma (PCA) usually involves the parotid and sublingual gland but is also seen in minor salivary glands of buccal mucosa, lip, and palate. It is defined by WHO as a low-grade malignant tumor characterized by predominantly cystic mass that often exhibits intraluminal papillary growth. As the intracystic papillary projections were not always a prominent feature, the term papillary was dropped from the nomenclature in 2005 WHO classification.<sup>[3,5]</sup> Nuclear pleomorphism, mitosis and infiltrative growth pattern corroborate the malignant nature of the tumor.<sup>[1]</sup> Most of the patients present as a slowly

growing asymptomatic mass. In the largest series of 57 cases reported by Foss et al., PCA was found to involve predominantly the parotid gland (71%), followed by the minor salivary glands (20%), and the sublingual glands (3.5%). Grossly cysts of varying sizes (0.4-6.0cm) were identified. Microscopically, all tumors revealed cystic areas with stromal invasion and approximately 75% of cases demonstrated intraluminal cystic papillary projections. Cell sorts described were small cuboidal (60%), tall cuboidal (16%), and tall columnar (12%) with mixed cell types of mucous, clear, oncocytic and rarely, focal epidermoid cells. The majority of the cases evinced minimal atypia and low mitotic rate (0-1/10 high power field), consistent with low-grade features. Lymph node metastasis was rarely observed in the cases implicating the parotid and only seen in one instance.<sup>[7,8]</sup> The tumor in our case displayed stromal invasion and predominantly mild with focal moderate nuclear pleomorphism. The presence of regional lymph node metastases ratified the malignant nature of the neoplasm.

PCAs of the salivary glands can be unambiguously recognized on FNAC. In a review by Kapila et al., the diagnostic accuracy for PCAs of the parotid glands in an optimal Fine Needle Aspiration Cytology (FNAC) material was 80-95%.<sup>[9]</sup> In our case, however, FNAC was not done. Rather, the diagnostic misinterpretation occurred on the trucut/punch biopsy. Delineating this entity from mucoepidermoid carcinoma (MEC) is essential because PCA requires less radical surgery and has a better prognosis. Incidental squamous metaplasia sometimes seen in this tumor has to be distinguished from the neoplastic squamoid component of MEC. That PCA shares the mucous element with mucoepidermoid carcinoma can be another potential pitfall, as befell in our case. The extent of papillary morphology in PCA can be variable, and this has to be borne in mind while differentiating it from MEC as well as other entities such as a papillary cystic variant of acinic cell carcinoma, polymorphous low-grade adenocarcinoma (PLGA), salivary duct carcinoma and metastatic thyroid papillary carcinoma.<sup>[1,10-12]</sup> PCAs most importantly need to be differentiated from cystadenoma that depends on the identification of infiltrative growth into adjacent salivary parenchyma or surrounding tissues. Nuclear atypia in PCAs is usually mild to moderate with one or two small distinct hyperchromatic nucleoli and eosinophilic to vacuolated cytoplasm.<sup>[1,7]</sup> In the present case, there was an infiltration of the cystic and solid epithelium of the tumor into the fibrotic stroma. A papillary cystic variant of acinic cell carcinoma shows characteristic acinar differentiation and is often accompanied by a microcystic growth pattern, a feature not expected in PCA. Both PLGA and PCA are low-grade papillary salivary carcinomas. PLGA, however occurs exclusively in minor salivary glands and arrays stromal fragments

and hyaline globules resembling pleomorphic adenoma or adenoid cystic carcinoma. Salivary duct carcinoma usually has large pleomorphic nuclei, ample eosinophilic cytoplasm and expresses androgen receptor, HER2 and Gross Cystic Disease Fluid Protein 15 (GCDFF-15). Metastatic papillary thyroid carcinoma possesses characteristic nuclear features and manifests thyroid transcription factor 1 (TTF-1).<sup>[1,13,14]</sup>

Despite its low-grade nature, there have been several reports indicating that PCA may harbor more aggressive behavior and higher grade pathological features.<sup>[10,11,14-16]</sup> Although there is no universally advocated grading system, high-grade PCAs tend to proclaim locally aggressive features, cytologic atypia, high mitotic rate, necrosis, and the absence of papillary features.<sup>[5]</sup> Pollett et al. have described a case of PCA with high-grade features and Mustafa et al. have reported a case with intermediate-grade features.<sup>[11,16]</sup> Accordingly, another study stratified PCAs into well- and poorly-differentiated subtypes and observed an association between differentiation and nodal metastases and recurrence.<sup>[16]</sup>

The management propounded for low-grade PCAs is similar to that advocated for other low-grade salivary gland adenocarcinomas. Conservative but complete surgical excision (superficial parotidectomy) is the treatment of choice. Higher stage and higher-grade parotid tumors, including the presence of an encased functional or impaired facial nerve, are strongly considered for complete parotidectomy. Moreover, neck dissection is recommended for high-grade tumors, those  $\geq 4$  cm in size, or in cases of clinicoradiological positive nodal disease. In many case reports of PCAs, additional postoperative radiation therapy was also considered.<sup>[1,5,6,14]</sup>

## CONCLUSION

Papillary cystadenocarcinoma of the salivary gland is a rare entity that can be reliably diagnosed on histopathological examination of the resected specimen. However, missing it or misinterpreting it on small (punch/trucut) biopsies cannot be repudiated. Awareness of this uncommon entity and familiarity with the challenges of the histopathologic diagnosis will enable veracious recognition and reporting of similar cases in the future.

## REFERENCES

1. Telugu RB, Job AJ, Manipadam MT. Papillary cystadenocarcinoma of the parotid gland: a rare case report. *J Clin Diagn Res.* 2016;10(6):01-03.
2. Seifert G, Sobin LH. The World Health Organization's histological classification of salivary gland tumors. A commentary on the second edition. *Cancer.* 1992;70(2):379-85.
3. Thompson L. World Health Organization classification of tumors: pathology and genetics of head and neck tumors. *Ear Nose Throat J.* 2006;85(2):74.

4. Seethala RR, Stenman G. Update from the 4th edition of the World Health Organization classification of head and neck tumours: tumors of the salivary gland. *Head Neck Pathol.* 2017;11(1):55-67.
5. Wang KY, Kim DH, Rad MG, Lincoln CM. High-grade features of papillary cystadenocarcinoma of the parotid gland. *Oman Med J.* 2019;34(2):164-8.
6. Sarairoh OA, Eid S. Parotid duct bleeding, presentation of malignant parotid gland papillary cystadenocarcinoma: a rare case report. *J Otolaryngol ENT Res.* 2018;10(4):233-5.
7. Foss RD, Ellis GL, Auclair PL. Salivary gland cystadenocarcinomas. A clinicopathologic study of 57 cases. *Am J Surg Pathol.* 1996;20(12):1440-7.
8. Ellis GL, Auclair PL. Tumours of the salivary glands. In: *Atlas of tumour pathology, 3rd series.* Washington DC: Armed Forces Institute of Pathology; 1996. p 289-96.
9. Kapila K, Verma K. Cytomorphologic features of papillary cystadenocarcinoma of the parotid. *Diagn Cytopathol.* 2002;26(6):392-97.
10. Nakagawa T, Hattori K, Iwata N, Tsujimura T. Papillary cystadenocarcinoma arising from minor salivary glands in the anterior portion of the tongue: a case report. *Auris Nasus Larynx.* 2002;29:87-90.
11. Pollett A, Perez-Ordenez B, Jordan RCK, Davidson MJ. High grade papillary cystadenocarcinoma of the tongue. *Histopathology.* 1997;31:185-8.
12. U'nal M, Polat A, Akbas Y, Pata YS. Polymorphous low-grade adenocarcinoma of the tongue. *Auris Nasus Larynx.* 2004;31:85-8.
13. Chan JKC, Cheuk W. Tumours of the salivary glands. In: Christopher D.M. Fletcher, editor. *Diagnostic histopathology of tumours, 4th edition.* Saunders, Elsevier Limited; 2013; p 270-377.
14. Mardi, K., Sharma, S., & Gupta, N. Papillary cystadenocarcinoma of submandibular salivary gland: A rare case report. *J Cancer Res Ther.* 2010;6:330-2.
15. Koç M, Yanilmaz M, Yildirim H, Gök U, Cobanoğlu B. MRI findings of papillary cystadenocarcinoma of the submandibular gland. *Diagn Interv Radiol* 2010;16:20-3.
16. Chen XM. Papillary cystadenocarcinoma of the salivary glands: Clinicopathologic analysis of 22 cases. *Zhonghua Kou Qiang Yi Xue Za Zhi.* 1990;25:102-4.

**Copyright:** © Annals of International Medical and Dental Research. It is an open-access article distributed under the terms of the Creative Commons Attribution Non-Commercial License, which permits unrestricted non-commercial use, distribution, and reproduction in any medium provided the original work is properly cited.

**How to cite this article:** Chowdhury Z, Mishra J, Shunyu NB. Papillary Cystadenocarcinoma of Salivary Gland: Report of a Diagnostic Pitfall and Literature Review. *Ann. Int. Med. Den. Res.* 2020; 6(4):PT12-PT15.

**Source of Support:** Nil, **Conflict of Interest:** None declared