

# Cytological Diagnosis of Actinomycotic Mycetoma - A Case Report

Nausheen Kauser<sup>1</sup>, Swarna Sri A<sup>2</sup>, Swarajya Kumari K<sup>3</sup>, Triveni B<sup>4</sup>

<sup>1</sup>Postgraduate, Upgraded Department of Pathology, Osmania Medical College, Hyderabad, Telangana, India.

<sup>2</sup>Assistant Professor, Upgraded Department of Pathology, Osmania Medical College, Hyderabad, Telangana, India.

<sup>3</sup>Associate Professor, Upgraded Department of Pathology, Osmania Medical College, Hyderabad, Telangana, India.

<sup>4</sup>Professor & HOD, Upgraded Department of Pathology, Osmania Medical College, Hyderabad, Telangana, India.

Received: October 2020

Accepted: October 2020

## ABSTRACT

Mycetoma is a chronic granulomatous infection endemic in tropical and subtropical areas. It is a disorder of the skin, subcutaneous tissue and bones mainly of feet with a triad of localized swelling, underlying sinus tracts and production of grains. It can be caused by bacteria or fungi. Early laboratory diagnosis by cytology and differentiation of causative agent is emphasized to decide a correct therapeutic modality. Here we present a case of a 40-year-old male with mycetoma foot where a diagnosis of bacterial mycetoma was offered cytologically. Difficulties in the management can be avoided by early diagnosis using the fine needle aspiration technique.

**Keywords:** Mycetoma, sinus, fine needle aspiration.

## INTRODUCTION

Mycetoma is a chronic suppurative infection affecting the skin, subcutaneous tissue, and bones prevalent in tropical and subtropical regions. The oldest description of this disease dates back to the ancient Indian Sanskrit text Atharva Veda in which reference is made to padavalmikam, meaning "anthill foot."<sup>[1]</sup>

In more modern times, Gill first recognized mycetoma as a disease entity in 1842 in the southern province of Madura from where the commonly used name "Madura's foot" got prevalent. Godfrey first documented a case of mycetoma in Madras, India.

The term "Mycetoma" (meaning fungal tumor) was proposed by Carter, who established the fungal etiology of this disorder.<sup>[2]</sup>

He classified his cases by the color of the grains. Pinoy recognized the possibility of classifying the cases of mycetoma by grouping the causative organisms, and the formal classification was put into place by Chalmers and Archibald who divided them into two groups.<sup>[3,4]</sup>

**Group 1:** Maduramycosis, caused by true fungi, and  
**Group 2:** Actinomycosis, caused by Actinomyces (higher bacteria).

## CASE REPORT

### Case Details and History

A 40-year-old male presented to the surgical OPD

#### Name & Address of Corresponding Author

Dr. Swarna Sri A  
Upgraded Department of Pathology,  
Osmania Medical College, Hyderabad,  
Telangana,  
India.

with nodular swelling of right foot who was referred to the Department of Pathology for imprints of serosanguinous discharge. There is a history of swelling of the right foot for 1 year. He is a laborer by occupation with a history of smoking and alcohol intake. There is a history of injury due to falls.

#### Local examination:

The dorsum of the right foot showed hyperpigmentation of the skin, with multiple nodules and signs of both healed and active sinuses.

#### Investigations:

- Peripheral blood examination:** Hb of 11.2%, with a total leukocyte count of 6,200/cumm, Differential leucocyte count: neutrophils: 68%, lymphocytes: 28%, monocytes: 02%, eosinophil: 02%, basophils: nil, platelet: adequate, and a normocytic hypochromic picture.
- Culture:** The discharge showed no bacterial growth.
- Radiological findings:** AP and Lateral view of the right foot shows soft tissue swelling and osteolytic lesion.

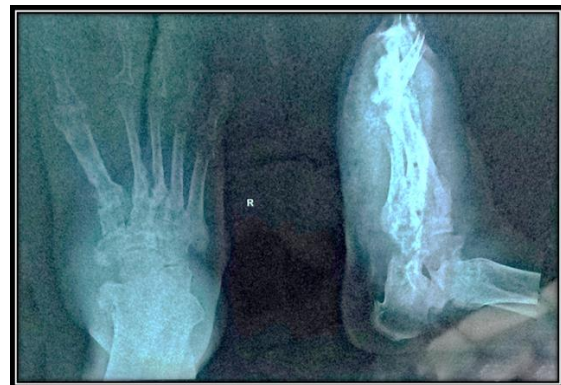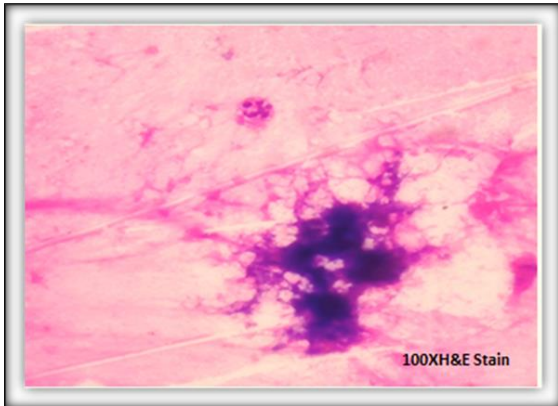


Figure 1: X-RAY AP and Lateral view of the foot.

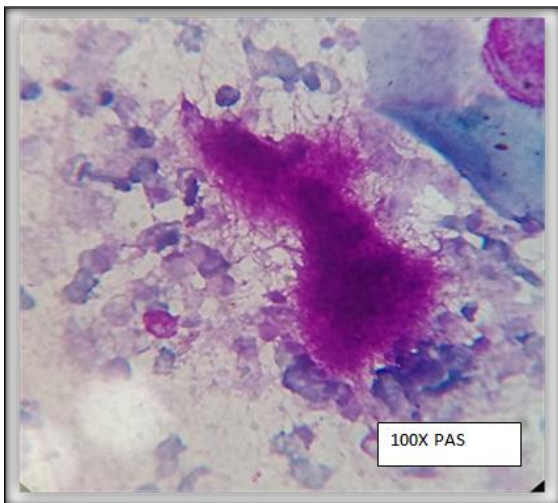
**4. FNAC:**

Blood mixed material was aspirated, smears were submitted for Hematoxylin and Eosin, Periodic acid Schiff, Grams stain and KOH.


Cytosmear studies showed eosinophilic dense colonies surrounded by polymorphs. Also showed nucleated and anucleate squamous cells in a necrotic background. Few of the eosinophilic bodies showed radiating filamentous structures with surrounding neutrophils.



**Figure 2: H&E section studies showed filamentous bacterial colonies.**



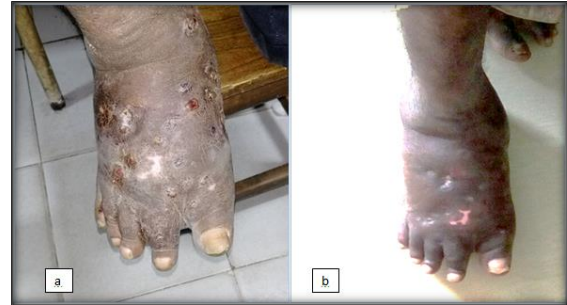**Figure 3: PAS stain studies showed eosinophilic dense colonies.**



**Figure 4: Grams stain studies showed elongated filamentous bacilli.**

**Results:** A diagnosis of Actinomycotic mycetoma was made on cytomorphological basis.

**Follow-up:** Patient is on Rifampicin 600mg and septran currently and the follow-up result show marked improvement.



**Figure 5: a) Before treatment, b) After treatment.**

**DISCUSSION**

Mycetoma is reported to occur worldwide. It is endemic in tropical and subtropical regions, particularly between latitudes 15° S and 30° N, also known as the “Mycetoma belt” (Sudan, Somalia, Senegal, India, Yemen, Mexico, Venezuela, Colombia, and Argentina), the actual endemic area extends beyond this belt.<sup>[5]</sup>

Overall, most cases occur in arid and hot climates, which have a short period of heavy rainfall with milder temperatures. Actinomycetoma is more prevalent in drier areas, whereas eumycetoma is more common in sites with more rainfall.

Around 75% of mycetomas are actinomycotic in certain parts of India.<sup>[6]</sup> Mycetoma is more commonly reported in males than females (3:1), probably attributable to men being more commonly involved in agricultural work.<sup>[7,8]</sup> The condition is most common in young adults (16–40 years old) and is uncommon in children.<sup>[9]</sup>

Features	Actinomycetoma	Eumycetoma
Etiological agent	Aerobic species of actinomycetes belonging to the genera <i>Nocardia</i> , <i>Streptomyces</i> , and <i>Actinomadura</i>	Fungi
Epidemiology	Prevalence more in drier areas	Prevalence more in sites with rainfall
Epidemiology (India)	75% of Indian cases	More common in northern India
Course	Rapid progression	Slow progression
Destruction	More destructive	Less destructive
Bone involvement	Early bone invasion	Late bone invasion
Lymph node spread	More common	Uncommon
Gram stain	Tabulated above	
Histopathology	Homogeneous eosinophilic material around the grain in a star-shaped manner	Suppurative granulomas composed of neutrophils are seen surrounding characteristic grains
Culture	Lowenstein-Jensen media, thioglycollate broth, Columbia agar, and brain heart infusion agar, at least for 10 days	Sabouraud 4% dextrose agar or Kimmig's agar, for 4-6 weeks
Ultrasonography	Grains produce fine echoes that are found at the bottom of the cavities	Produce single or multiple thick-walled cavities, without acoustic enhancement, with grains represented as distinct hyper-reflective echoes
Treatment	Antibiotics, surgery sometimes needed	Surgery usually needed along with antifungals

**CONCLUSION**

Mycetoma, being a relatively painless condition, is often diagnosed at an advanced stage where permanent deformity and disability of the affected part has already occurred. The chronic nature of the disease leads to a high possibility of superimposed bacterial infection which can worsen the disease. The challenge in such cases is to differentiate between Actinomycotic mycetoma and Eumycotic

mycetoma as it has an immense bearing on the treatment outcome. Cytomorphological studies can help to distinguish Eumycetoma vs Actinomycetoma.

## REFERENCES

1. Kwon-Chung KJ, Bennett JE. Mycetoma. In: Medical Mycology. Philadelphia: Lea & Febiger; 1992. p. 560-93. Back to cited text no. 3
2. Carter HV. On a New and Striking form of Fungus Disease Principally Affecting the Foot and Prevailing Endemically in Many Parts of India. Transactions of the Medical and Physical Society of Bombay 1860;6:104-42. Back to cited text no. 4
3. Pinoy E. Actinomycoses and mycetomas. Bull Inst Pasteur 1913;11:929. Back to cited text no. 5
4. Chalmers AJ, Archibald RG. A Sudanese maduromycoses. Ann Trop Med 1916;10:169. Back to cited text no. 6
5. Hay RJ, Mackenzie DW. Mycetoma (madura foot) in the United Kingdom – A survey of forty-four cases. Clin Exp Dermatol 1983;8:553-62. Back to cited text no. 9
6. Chaudhuri BN, Maiti PK, Sil J. Antibiotic sensitivity patterns of actinomycetes isolated from patients of actinomycetoma. Indian J Med Res 1997;105:162-6.
7. Fahal AH, Sabaa AH. Mycetoma in children in Sudan. Trans R Soc Trop Med Hyg 2010;104:117-21. Back to cited text no. 13.
8. Zarei Mahmoudabadi A, Zarrin M. Mycetomas in Iran:a review article. Mycopathologia 2008;165:135-41. Back to cited text no. 14.
9. López Martínez R, Méndez Tovar LJ, Lavalle P, Welsh O, Saúl A, Macotela Ruíz E. Epidemiology of mycetoma in Mexico: Study of 2105 cases. Gac Med Mex 1992;128:477-81.

**Copyright:** © the author(s), 2020. It is an open-access article distributed under the terms of the Creative Commons Attribution License (CC BY 4.0), which permits authors to retain ownership of the copyright for their content, and allow anyone to download, reuse, reprint, modify, distribute and/or copy the content as long as the original authors and source are cited.

**How to cite this article:** Kauser N, Sri AS, Kumari KS, Triveni B. Cytological Diagnosis of Actinomycotic Mycetoma- A Case Report. Ann. Int. Med. Den. Res. 2020; 6(6):PT04-PT06.

**Source of Support:** Nil, **Conflict of Interest:** None declared