

# Comparative Analysis of Peripapillary Retinal Nerve Fibre Layer Thickness and Macular Thickness Parameters Using Spectral Domain Optical Coherence Tomography between Normal and Glaucomatous Eyes

Kirti Aggarwal<sup>1</sup>, Ajai Agrawal<sup>2</sup>, Anupam Singh<sup>2</sup>, Sanjeev Kumar Mittal<sup>3</sup>, Ramanuj Samanta<sup>4</sup>, Mohd Ghaniul Hasan<sup>1</sup>

<sup>1</sup>Junior Resident, Department of Ophthalmology, All India Institute of Medical Sciences, Rishikesh, Uttarakhand, India.

<sup>2</sup>Additional Professor, Department of Ophthalmology, All India Institute of Medical Sciences, Rishikesh, Uttarakhand, India.

<sup>3</sup>Professor, Department of Ophthalmology, All India Institute of Medical Sciences, Rishikesh, Uttarakhand, India.

<sup>4</sup>Assistant Professor, Department of Ophthalmology, All India Institute of Medical Sciences, Rishikesh, Uttarakhand, India.

Received: November 2020

Accepted: December 2020

## ABSTRACT

**Background:** Based on recent literature, macular Ganglion cell complex (GCC) plays an important role in evaluation of glaucomatous damage in addition to Peripapillary Retinal Nerve Fibre Layer (pRNFL). Objectives: The purpose of this study was to compare the diagnostic accuracy of pRNFL thickness and macular thickness parameters using Spectral Domain Optical Coherence Tomography (SD-OCT) in distinguishing between normal and glaucomatous eyes. **Methods:** This is a cross sectional study conducted at a tertiary care centre in Uttarakhand. 79 eyes [38 eyes in Primary Open Angle Glaucoma (POAG) group and 41 eyes in control group] were enrolled in this study. All participants underwent comprehensive ocular examination and Standard Automated Perimetry (SAP) using the 30-2 threshold testing protocol. Peripapillary and macular imaging was performed at the same visit to determine pRNFL thickness and Macular Ganglion Cell Inner Plexiform Layer (GC/IPL) thickness. Receiver operator characteristic (ROC) curves were studied to compare the diagnostic accuracy of both parameters for evaluating glaucomatous damage. **Results:** Statistical analysis obtained after plotting ROC curves showed high diagnostic performance for both GC/IPL (0.931) and pRNFL (0.912) thickness for glaucoma detection. However, there was no significant difference on comparative analysis (De Long's Test  $p = 0.568$ ). Among all the tomographical parameters, the superotemporal GC/IPL thickness (0.919) and the superior pRNFL thickness (0.896) showed the highest Area Under Receiver operator characteristic (AUROC) curves. **Conclusion:** Macular GC/IPL thickness parameters showed excellent diagnostic performance. However, they did not outperform the pRNFL thickness parameters for diagnosis of glaucoma.

**Keywords:** Ganglion Cell Inner Plexiform Layer; Peripapillary Retinal Nerve Fibre Layer; Primary Open Angle Glaucoma; Spectral Domain Optical Coherence Tomography.

## INTRODUCTION

Glaucoma is a multifactorial and progressive optic neuropathy that is clinically diagnosed as optic disc cupping associated with corresponding functional defect in visual field (VF). However, the underlying disease process is loss of retinal ganglion cells (RGC's) and their axons in the retinal nerve fibre layer (RNFL).<sup>[1]</sup>

POAG accounts for 74% of all glaucoma cases worldwide posing significant health burden on society. According to a recent review, the global number of POAG cases in 2013 was 44 million, projected to increase to 53 million by 2020.<sup>[2,3]</sup> POAG patients are often asymptomatic until it progresses to advanced stage, frequently delaying the diagnosis and treatment. When a glaucomatous

visual field is detected, approximately 28% of RGC's and 17% of RNFL thickness has already been damaged irreversibly.<sup>[4,5]</sup>

There have been several advances in technology in recent years that allow for the quantitative assessment of pRNFL to detect glaucoma early using SD-OCT. As RNFL is comprised of RGC axons, GCC as detected by SD-OCT may prove to be a more direct way to detect early glaucomatous damage than pRNFL measurements. Further, macular RGC layer contains more than 50% of RGC's of entire retina and is thicker than RNFL,<sup>[6]</sup> it is now possible to look for glaucoma progression using macular GC/IPL thickness as a valuable alternative method for identifying structural damage from glaucoma.

Thus, in recent literature, increased attention has been directed towards the macular region for evaluation of glaucomatous damage. Several studies have shown that macular GCC thickness measurement has good discriminating power in diagnosis of glaucoma when compared to pRNFL

### Name & Address of Corresponding Author

Dr. Ajai Agrawal  
Department of Ophthalmology,  
All India Institute of Medical Sciences,  
Rishikesh, Uttarakhand, India.  
E-mail address: ajaiagrwal@rediffmail.com

thickness. However, there is paucity of data in South Asian eyes due to limited number of studies.

The current study was conducted in view of recent literature which favours quantifying RGC loss in the macula in addition to pRNFL thickness measurements as a means of detecting glaucomatous damage.

## **MATERIALS AND METHODS**

This was a cross sectional study in which comparative analysis was done for pRNFL and GC/IPL thickness for diagnosis of glaucoma. The study was conducted in the Outpatient Department (OPD) of Ophthalmology of a tertiary care institute in Rishikesh, India over a period of 12 months. Institute Ethics Committee clearance was obtained (Reference no: AIIMS/IEC/18/128). Informed and written consent was taken from all the study participants.

Patients with clinical diagnosis of POAG were prospectively identified and constituted the study group. Normal subjects were recruited from among those who came for a routine eye examination and hospital staff. Thus, a total of 79 patients (38 POAG and 41 normal subjects) were enrolled for the study.

All patients were subjected to detailed history taking and a comprehensive ocular examination. Subjects included in this study were required to have >18 years age with best corrected visual acuity more than 20/40, refractive error <6 spherical diopters and open angles on gonioscopy. Corrected Intraocular Pressure (IOP) was measured using applanation Goldmann's Tonometer after taking into consideration central corneal thickness measurements. Patients with history of previous intraocular surgery or laser, coexisting retinal or macular pathology and neurological diseases were excluded. Any pathological condition affecting visual fields eg. Diabetes Mellitus, pituitary lesions and secondary causes of raised Intraocular Pressure such as corticosteroid use, trauma and iridocyclitis were also ruled out.

POAG patients were defined as IOP > 21 mm Hg, open angle on gonioscopy with glaucomatous optic disc abnormalities and visual field defects. Characteristic glaucomatous optic disc changes include vertical cup-to-disc ratio >0.6, or the vertical cup-to-disc ratio difference >0.2 between the two eyes, focal notching, diffuse neuro-retinal rim thinning, or retinal nerve fiber layer defects.

All subjects underwent SAP on the Humphrey's Field Analyser (Carl Zeiss-Humphrey Systems, Dublin, CA), using the 30-2 threshold testing protocol by SITA strategy. Reliability of test was ensured. Fixation losses of more than 20% and false-positive and false-negative rates of more than 20% were excluded.

Glaucomatous visual field defects were defined by any two of the following three Andersons criteria on SAP to pick up minimal abnormality:

- 1) The presence of a cluster of three non-edge points on pattern deviation probability plot with a P-value as follows:
  - Two points  $P < 5\%$
  - One point  $P < 1\%$
- 2) A pattern standard deviation with a P-value less than 5%
- 3) Glaucoma hemifield test result outside normal limits.

Peripapillary and macular imaging was performed using SD Cirrus™ OCT (Carl Zeiss Meditec, Dublin, CA; software version-3.0.0.64) at the same visit. To be acceptable for inclusion, the scans were properly centered on the optic disc or macula. Only good quality scans with signal strength >6 were used for analysis. Care was taken to ensure no discontinuity or misalignment in the scan due to blinks or eye motion.

The optic disc 200 × 200 scan was used for pRNFL thickness measurements. Each optic disc scan generated a cube of data through a 6 mm square grid consisting of 200 horizontal scan lines each composed of 200 A-scans. Average pRNFL thickness and pRNFL thickness in quadrants was calculated on a measurement circle of 3.6 mm diameter. Their deviation from a normative database was provided in a color-coded scheme.

The macular images were obtained using macular cube 200 × 200 scan protocol for ganglion cell analysis (GCA). In the SD-OCT, GCA consists of the combined thickness of GCL and IPL. Unlike GCC, it does not include the RNFL, thus less affected by RNFL thickness variations. The Macular Cube measured GC/IPL parameters in 6 wedge-shaped sectors after excluding the central foveolar region (1 mm in diameter) and provided the data in colour coded scheme for the GC/IPL thickness.

All tomographical parameters were compared in the glaucomatous and normal subjects for their diagnostic efficacy.

### **Statistical Analysis**

Data was entered in a Microsoft Excel Spread Sheet (Microsoft Corporation, USA) and analysed using Statistical Package for the Social Sciences (SPSS) Statistics Version 21.0. Qualitative data was analysed using chi square test. For quantitative parameters, which were normally distributed between the 2 subgroups, parametric test (t test) was used for comparison. Quantitative variables which were not normally distributed were compared using non parametric tests (Wilcoxon test). Mean value and p value was reported for each of the pRNFL and macular parameters. Further, sensitivity, specificity, diagnostic accuracy and AUROC was calculated for each variable in each sector and De Long's test was used for comparison between normal and POAG group.

**RESULTS**

A total number of 79 patients were recruited and analysed in the present study. 38 cases were of POAG and rest 41 were normal subjects. Table 1 summarizes the demographic and clinical data of all the study participants in both groups. The mean age in POAG group was 51.95 ± 12.27 and that of control group was 50.41 ± 9.87. Majority of the patients were male in both POAG group and control group. Optic disc cupping was significantly increased in POAG patients. Central cornea was thicker in control group as compared to POAG group. There was no statistically significant difference between the groups in terms of Corrected IOP and Axial length.

The Average pRNFL was significantly thinner in glaucoma patients (p<0.001) and showed good diagnostic ability for glaucoma. The mean (SD) of Average pRNFL (µm) in the POAG group was 73.74 (16.14). There was also a significant difference between the two groups in terms of Average GC/IPL Thickness (µm) (t = -8.891, p = <0.001), with the mean Average GC/IPL Thickness being highest in the Control group: 81.51 (5.99). Sensitivity and specificity at 95 % CI, cut off points, AUROC values and diagnostic accuracy was

calculated for all the parameters evaluated in this study as shown in Table 2. Based on AUROC curves, there was no significant difference in the diagnostic performance of Average pRNFL and Average GC/IPL measurements (De Long's Test p = 0.568) (Fig1). The best parameters of the respective layers in terms of AUROC, minimum thickness of GC/IPL and the average thickness of pRNFL were also compared and did not show significant difference in diagnostic performance (De Long's Test p = 0.342). The best parameters in terms of sensitivity at 95% CI were Average GC/IPL Thickness and Superior GC/IPL Thickness while in terms of specificity at 95% CI was Inferior Outer Macular Thickness.

This study also evaluated the macular thickness parameters for their role in glaucoma diagnosis. There was no significant difference between the groups in terms of Central Foveal Thickness (p = 0.311). However, most of the macular parameters showed significant decrease in thickness except nasal inner macular thickness (p=0.195). The highest diagnostic accuracy was for Inferior Outer Macular Thickness with AUROC of 0.82 which also came out to be the best parameter in terms of specificity.

**Table 1: Demographic and clinical characteristics of study groups**

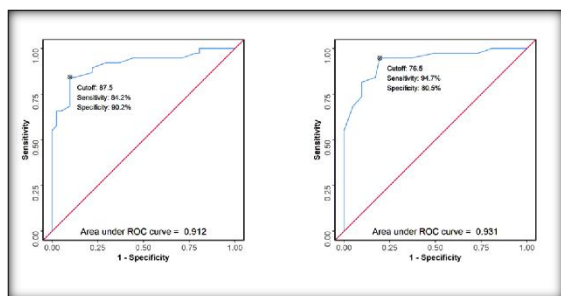
Variables	POAG Group (n=38)	Control Group (n=41)	p value
Age (years)	58.95 (12.27)	50.41 (9.87)	0.001
Gender (male/female)	32/6	23/18	0.007
Optic disc cupping	6.87 (2.08)	4.71 (2.27)	<0.001
Baseline IOP (mm Hg)	16.89 (4.64)	16.95 (13.67)	0.089
Central corneal thickness (µm)	512.26 (32.67)	527.49 (27.44)	0.029
Axial Length (mm)	23.35 (1.07)	22.83 (0.85)	0.067
Visual Field Mean Deviation (dB)	-7.97(6.11)	-2.42 (2.21)	<0.001

Values are shown in mean ± SD

**Table 2: Comparison of the Diagnostic Performance of Various Predictors in Study Group: POAG vs Control Group (n=79)**

Predictor	AUROC	95% CI	P	Sn	Sp	DA
Average RNFL (µm)	0.912	0.845-0.979	<0.001	84.2%	90.2%	45.6%
Superior RNFL (µm)	0.896	0.83-0.962	<0.001	78.9%	85.4%	45.6%
Nasal RNFL (µm)	0.703	0.587-0.819	0.002	60.5%	70.7%	44.3%
Temporal RNFL (µm)	0.774	0.665-0.883	<0.001	76.3%	70.7%	51.9%
Inferior RNFL (µm)	0.863	0.779-0.947	<0.001	84.2%	78.0%	51.9%
Central Foveal Thickness (µm)	0.578	0.451-0.706	0.233	76.3%	41.5%	67.1%
Superior Inner Macular Thickness (µm)	0.673	0.551-0.795	0.008	71.1%	65.9%	51.9%
Inferior Inner Macular Thickness (µm)	0.76	0.648-0.871	<0.001	65.8%	82.9%	40.5%
Nasal Inner Macular Thickness (µm)	0.585	0.457-0.713	0.195	42.1%	78.0%	31.6%
Temporal Inner Macular Thickness (µm)	0.697	0.577-0.816	0.003	63.2%	78.0%	41.8%
Superior Outer Macular Thickness (µm)	0.79	0.687-0.893	<0.001	78.9%	73.2%	51.9%
Nasal Outer Macular Thickness (µm)	0.815	0.716-0.915	<0.001	78.9%	82.9%	46.8%
Inferior Outer Macular Thickness (µm)	0.82	0.725-0.915	<0.001	55.3%	97.6%	27.8%
Temporal Outer Macular Thickness (µm)	0.702	0.583-0.821	0.002	73.7%	63.4%	54.4%
Average GC/IPL Thickness (µm)	0.931	0.876-0.986	<0.001	94.7%	80.5%	55.7%
Minimum GC/IPL Thickness (µm)	0.941	0.894-0.987	<0.001	76.3%	95.1%	39.2%
Superotemporal GC/IPL Thickness (µm)	0.919	0.858-0.98	<0.001	81.6%	87.8%	45.6%
Superior GC/IPL Thickness (µm)	0.884	0.811-0.956	<0.001	94.7%	70.7%	60.8%
Superonasal GC/IPL Thickness (µm)	0.82	0.726-0.914	<0.001	89.5%	63.4%	62.0%
Inferonasal GC/IPL Thickness (µm)	0.886	0.812-0.959	<0.001	86.8%	82.9%	50.6%
Inferior GC/IPL Thickness (µm)	0.883	0.803-0.963	<0.001	86.8%	80.5%	51.9%
Inferotemporal GC/IPL Thickness (µm)	0.87	0.793-0.947	<0.001	71.1%	90.2%	39.2%

AUROC: Area under ROC curve; CI: Confidence interval; DA: Diagnostic Accuracy; P: P value; Sn: Sensitivity; Sp: Specificity.



**Figure 1: AUROC Curve Analysis Showing Diagnostic Performance of Average pRNFL and Average GC/IPL measurements for discriminating between POAG and Control Group (n = 79).**

## DISCUSSION

Glaucoma typically presents as clinically asymptomatic disease that may progress to irreversible blindness.<sup>[4,7-8]</sup> Visual field loss is not obvious in early stages. This leads to high probability for missed diagnosis until it progresses to an advanced stage.

In glaucoma, the damage starts at the GCL and then proceeds to the RNFL.<sup>[9]</sup> Several studies were performed in the previous years to assess the diagnostic ability of GC/IPL which included preperimetric glaucoma patients. Some of these studies suggested that both macular GC/IPL and mean pRNFL thickness were decreased in early glaucoma but the ability of GC/IPL to discriminate normal eyes with early glaucoma is high and comparable to that of the pRNFL.<sup>[9-13]</sup>

Indeed, recent reports regarding macular GC/IPL analysis support the postulation that this modality may be more useful for evaluation of moderate to advanced glaucoma rather than preperimetric glaucoma assessment.<sup>[6]</sup> This may be supported by the fact that the papillomacular bundle is resistant to glaucomatous structural damage and usually remains intact until the advanced stages of the disease are attained.<sup>[14,15]</sup> Thus, combined evaluation of macular GCC and pRNFL thickness has been found to enhance the glaucoma detection rate in both preperimetric and perimetric groups.

This study was performed on patients with established glaucoma where the damage had already occurred. As expected, vertical cup to disc ratio showed significant optic disc cupping when compared to normal subjects ( $P < 0.001$ ). Visual field analysis also showed field defects in majority of the patients. The main objective was to evaluate and compare the diagnostic accuracy of SD-OCT parameters (pRNFL and macular thickness parameters) to discriminate between normal subjects and POAG.

In the present study, a significant reduction was noted in both the pRNFL and mGC/IPL thickness, which can be explained by the fact that glaucomatous damage results in the loss of RGC's that constitute 30 to 35 per cent of the macular

retinal thickness.<sup>[16,17]</sup> Further, the results of the analysis obtained after plotting AUROC curves showed high diagnostic performance for both GC/IPL (0.931) and pRNFL (0.912) thickness for glaucoma detection. This can be explained by large difference in the thickness values of both parameters between the glaucoma patients and normal subjects.

In comparison to the Average pRNFL, average mGC/IPL did not show any significant difference in diagnostic performance (DeLong's Test  $p = 0.568$ ). This is in agreement with few previous studies, which reported similar diagnostic accuracy of GC/IPL and pRNFL parameters. In a recent review, Assad et al,<sup>[9]</sup> evaluated the extent of GC/IPL damage caused by moderate and severe glaucoma. They found that the diagnostic ability of this layer is high and comparable to pRNFL in this group of patients.

The best parameters in this study in terms of highest AUROC's were the minimum GC/IPL thickness and average pRNFL thickness, which is in consonance with previous studies.<sup>[18-20]</sup> It was also found that the diagnostic ability of these two best parameters was comparable in both groups (DeLong's Test  $p = 0.342$ ).

A significant decrease in the macular thickness parameters was also noted in POAG group compared to healthy eyes, except central foveal thickness and nasal inner quadrant of macula. Few studies also have demonstrated the early involvement of macula in glaucoma.<sup>[21-26]</sup> These findings were consistent with the findings of Saha et al,<sup>[27]</sup> who showed similar discriminating power of macular thickness parameters between the groups and emphasized on its role as a new method for detection of glaucomatous damage.

In addition, mGCC parameters may be useful in conditions like staphyloma or tilted discs, where pRNFL analysis may not be reliable. Since this is a cross sectional study and did not include long term follow up of patients, so the role of serial GCC scans in glaucoma progression could not be assessed.

## CONCLUSION

Although macular GC/IPL thickness parameters showed excellent diagnostic performance, they did not outperform pRNFL thickness parameters for diagnosis of glaucoma.

## REFERENCES

1. Quigley HA, Miller NR, George T. Clinical evaluation of nerve fiber layer atrophy as an indicator of glaucomatous nerve damage. *Arch Ophthalmol.* 1980; 98:1564-71.
2. Quigley HA, Broman AT. The number of people with glaucoma worldwide in 2010 and 2020. *Br J Ophthalmol.* 2006; 90:262-7.
3. Tham YC, Li X, Wong TY, Quigley HA, Aung T, Cheng CY. Global prevalence of glaucoma and projections of glaucoma

- burden through 2040: a systematic review and meta-analysis. *Ophthalmology*. 2014; 121:2081–90.
4. Medeiros FA, Zangwill LM, Bowd C, Vessani RM, Susanna R, Weinreb RN. Evaluation of retinal nerve fiber layer, optic nerve head, and macular thickness measurements for glaucoma using optical coherence tomography. *Am J Ophthalmol*. 2005; 139:44-55.
  5. Wollstein G, Kagemann L, Bilonick RA, Ishikawa H, Folio LS, Gabriele ML, et al. Retinal nerve fiber layer and visual function loss in glaucoma: the tipping point. *Br J Ophthalmol*. 2012; 96:47–52.
  6. Sung KR, Wollstein G, Kim NR, Na JH, Nevins JE, Kim CY, et al. Macular assessment using optical coherence tomography for glaucoma diagnosis. *Br J Ophthalmol*. 2012; 96:1452–5.
  7. Kaushik S, Kataria P, Jain V, Joshi G, Raj S, Pandav SS. Evaluation of macular ganglion cell analysis compared to retinal nerve fiber layer thickness for preperimetric glaucoma diagnosis. *Indian J Ophthalmol*. 2018; 66: 511-6.
  8. Weinreb RN, Friedman DS, Fechtner RD, Cioffi GA, Coleman AL, Girkin CA, et al. Risk assessment in the management of patients with ocular hypertension. *Am J Ophthalmol*. 2004; 138:458-67.
  9. Asaad A, Sabry D, Kamel R, Ghafar A. Glaucomatous changes in macular ganglion cell detected by spectral domain optical coherence tomography: comparison with peripapillary retinal nerve fiber layer. *Int Eye Sci*. 2016; 16(3):409-15.
  10. Lisboa R, Paranhos A, Weinreb RN, Zangwill LM, Leite MT, Medeiros FA. Comparison of different spectral domain OCT scanning protocols for diagnosing preperimetric glaucoma. *Invest Ophthalmol Vis Sci*. 2013; 54(5):3417-25.
  11. Mwanza JC, Durbin MK, Budenz DL, Sayyad FE, Chang RT, Neelakantan A, et al. Glaucoma diagnostic accuracy of ganglion cell-inner plexiform layer thickness: comparison with nerve fiber layer and optic nerve head. *Ophthalmology*. 2012; 119(6):1151-8.
  12. Kim KE, Yoo BW, Jeung JW, Park KH. Long Term Reproducibility of Macular Ganglion Cell Analysis in Clinically Stable Glaucoma Patients. *Invest Ophthalmol Vis Sci*. 2015; 56(8):4857-64.
  13. Karti O, Yuksel B, Uzunel UD, Karahan E, Zengin MO, Kusbeci T, et al. The assessment of optical coherence tomographic parameters in subjects with a positive family history of glaucoma. *Clin Exp Optom*. 2017; 100:663-7.
  14. Takayama K, Hangai M, Durbin M, Nakano N, Morooka S, Akagi T, et al. A novel method to detect local ganglion cell loss in early glaucoma using spectral domain optical coherence tomography. *Invest Ophthalmol Vis Sci*. 2012; 53:6904-13.
  15. Jeung JW, Choi YJ, Park KH, Kim DM. Macular ganglion cell imaging study: glaucoma diagnostic accuracy of spectral-domain optical coherence tomography. *Invest Ophthalmol Vis Sci*. 2013; 54:4422–9.
  16. Khanal S, Davey PG, Racette L, Thapa M. Comparison of retinal nerve fiber layer and macular thickness for discriminating primary open-angle glaucoma and normal-tension glaucoma using optical coherence tomography. *Clin Exp Optom*. 2016; 99:373–81.
  17. Guedes V, Schuman JS, Hertzmark E, Wollstein G, Correnti A, Mancini R, et al. Optical coherence tomography measurement of macular and nerve fiber layer thickness in normal and glaucomatous human eyes. *Ophthalmology*. 2003; 110(1):177–89.
  18. Jung HH, Sung MS, Heo H, Park SW. Macular inner plexiform and retinal nerve fiber layer thickness in glaucoma. *Optom Vis Sci*. 2014; 91(11):1320-7.
  19. Karasheva G, Goebel W, Klink T, Haigis W, Grehn F. Changes in macular thickness and depth of anterior chamber in patients after filtration surgery. *Graefes Arch Clin Exp Ophthalmol*. 2003; 241:170-5.
  20. Sesar A, Cavar I, Sesar AP, Geber MZ, Sesar I, Laus KN, et al. Macular thickness after glaucoma filtration surgery. *Coll Antropol*. 2013; 37:841-5.
  21. Seong M, Sung KR, Choi EH, Kang SY, Cho JW, Um TW, et al. Macular and peripapillary retinal nerve fiber layer measurements by spectral domain optical coherence tomography in normal-tension glaucoma. *Invest Ophthalmol Vis Sci*. 2010; 51:1446–52.
  22. Hood DC, Raza AS, De Moraes CG, Johnson CA, Liebmann JM, Ritch R. The nature of macular damage in glaucoma as revealed by averaging optical coherence tomography data. *Transl Vis Sci Technol*. 2012; 1:3.
  23. Nakano N, Hangai M, Nakanishi H, Mori S, Nukada M, Kotera Y. Macular ganglion cell layer imaging in preperimetric glaucoma with speckle noise-reduced spectral domain optical coherence tomography. *Ophthalmology*. 2011; 118:2414-26.
  24. Parikh RS, Parikh SR, Thomas R. Diagnostic capability of macular parameters of Stratus OCT 3 in detection of early glaucoma. *Br J Ophthalmol*. 2010; 94:197-201.
  25. Barisi F, Sicaja AJ, Ravli MM, Novak-Laus K, Ivekovi R, Mandi Z. Macular thickness and volume parameters measured using optical coherence tomography (OCT) for evaluation of glaucoma patients. *Coll Antropol*. 2012; 36:441-5.
  26. Tan O, Li G, Lu AT, Varma R, Huang D. Advanced Imaging for Glaucoma Study Group. Mapping of macular substructures with optical coherence tomography for glaucoma diagnosis. *Ophthalmology*. 2008; 115:949-56.
  27. Saha M, Bandyopadhyay S, Das D, Ghosh S. Comparative analysis of macular and peripapillary retinal nerve fiber layer thickness in normal, glaucoma suspect and glaucomatous eyes by optical coherence tomography. *Nepal J Ophthalmol*. 2016; 8:110-8.

**Copyright:** © the author(s), 2020. It is an open-access article distributed under the terms of the Creative Commons Attribution License (CC BY 4.0), which permits authors to retain ownership of the copyright for their content, and allow anyone to download, reuse, reprint, modify, distribute and/or copy the content as long as the original authors and source are cited.

**How to cite this article:** Aggarwal K, Agrawal A, Singh A, Mittal SK, Samanta R, Hasan MG. Comparative Analysis of Peripapillary Retinal Nerve Fibre Layer Thickness and Macular Thickness Parameters Using Spectral Domain Optical Coherence Tomography Between Normal and Glaucomatous Eyes. *Ann. Int. Med. Den. Res*. 2021; 7(1):OT01-OT05.

**Source of Support:** Nil, **Conflict of Interest:** None declared