

# Study of Clinical Outcome of Management of Medial Compartment Osteoarthritis of Knee by Proximal Fibular Osteotomy

Arijit Saha<sup>1</sup>, Sourav Chatterjee<sup>2</sup>, Pratyay Mukherjee<sup>3</sup>, Soumya Ghosh<sup>4</sup>

<sup>1</sup>Senior Resident, Department of Orthopaedics, Jangipur Super Speciality Hospital, Raghunathganj, West Bengal, India.

<sup>2</sup>Senior Resident, Department of Orthopaedics, Calcutta National Medical College. Gorachand Rd, Beniapukur, Kolkata, India.

<sup>3</sup>Junior Resident, Department of Orthopaedic Surgery, Burdwan Medical College, Bardhaman, West Bengal, India.

<sup>4</sup>Professor, Department of Orthopaedics, Rampurhat Medical College, Birbhum, West Bengal, India.

Received: October 2020

Accepted: October 2020

## ABSTRACT

**Background:** Osteoarthritis causes considerable pain and is a leading cause of disability in affected individual. Various surgical managements are also present but the procedures are complex and have certain restrictions, contraindications and long rehabilitation protocol. Proximal fibular osteotomy (PFO) is emerging as a new option and is safe, simple, less expensive and requires less rigorous rehabilitation, and ideal for our socioeconomic situation. **Aims & Objectives:** To delineate the effect of Proximal Fibular Osteotomy (PFO) for pain relief and functional outcome in medial condyle osteoarthritis of knee. **Methods:** This is an institution based prospective study done in the Department of Orthopaedics, Burdwan Medical College over a period of 18 months with sample size of 20 with minimum follow up for 12 months. **Results:** In our study, most of the patients reported pain relief with dropping of Visual Analogue Scale score from 7.2 to 3.1. And improvement of average Knee Society Score (KSS) of 51.2 to 77, with significant patient satisfaction. **Conclusion:** Our study shows that Proximal Fibular Osteotomy shows good outcome in pain relief and improving joint function if proper indications are met.

**Keywords:** Proximal Fibular Osteotomy (PFO), Medial condyle osteoarthritis, VAS score, Knee Society Score.

## INTRODUCTION

Osteoarthritis of knee is one of most common musculoskeletal disorders that result in considerable amount of pain due to loss of articular cartilage leading to disability, deformity and loss of function of knee. Excessive loading over knee joints results in accelerated loss of cartilage. In gait cycle adduction of knee in stance phase is main contributing factor of medial compartment knee osteoarthritis.<sup>[1]</sup> Varus and valgus deformity develop due to malalignment; medial joint space reduction is very common as it bears 60-80% of load distributed along mechanical axis.<sup>[2]</sup> High Tibial Osteotomy (HTO) is usually the first choice of treatment in younger population whereas Unicompartmental Knee Arthroplasty (UKA) is the choice in elderly in medial condyle osteoarthritis.<sup>[3,4]</sup> Though Total Knee Arthroplasty (TKA) provides best of results in pain management, however it has some limitation in lower alignment correction. Proximal fibular

osteotomy (PFO) is becoming widely accepted treatment modality in management of medial compartment osteoarthritis due to its simple procedure, lesser costs and require less rigorous rehabilitation protocol. The lateral support provided to the osteoporotic tibia by fibula-soft tissue complex may lead to non-uniform weight distribution on tibial plateau and shifting to load further medially, aggravating the progression.<sup>[5]</sup> PFO acts to redistribute this load.

### Aims & objectives:

1. To study clinical and radiological outcome of proximal fibular osteotomy in medial condyle knee osteoarthritis.
2. To study of associated complications, immediate or late.

## MATERIALS AND METHODS

**Study design:** Institution based prospective study

**Study Area:** Department of Orthopaedics, Burdwan Medical College.

**Study Population:** 20 knees (18 patients, two had b/l PFO)

**Study duration:** March 2018 to March 2019

### Inclusion Criteria:

1. Varus Knee (>5 degree)

### Name & Address of Corresponding Author

Dr. Arijit Saha,  
Senior Resident,  
Department of Orthopaedics,  
Jangipur Super Speciality Hospital  
Raghunathganj, West Bengal, India.  
Email id: arijitsaha91@gmail.com

2. Medial compartment OA
3. Age >40 years

**Exclusion Criteria:**

1. Age < 40yrs
  2. Obese patient
  3. Tri-compartmental Osteoarthritis
  4. Varus knee >10 degree
- Parameters to be studied: Visual Analogue Scale Score (VAS SCORE).<sup>[6]</sup>  
Knee Society Score (KSS).<sup>[7]</sup>

**RESULTS**

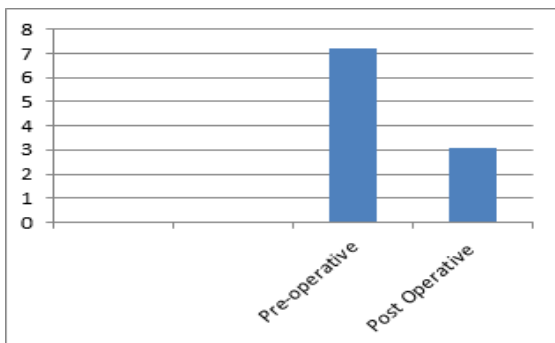
**Age & Sex distribution:** In our study, the youngest patient was 42 years old and the oldest pt was 65 years old. The mean age was 49.1years. 45% of patients belong in the 40-50 year age group. Out of 20 knees 12 knees belongs to female patients. Females constituted 60% of cases where males were 40% cases.

**Scoring on follow up:** Among the 20 knees (18 patients; 2 have bilateral PFO done), 19 knees are followed up for at least 12 months; one patient is lost to follow up after 8 months. Most of the patients have good pain relief and functional outcome. VAS score is used for analysis of pain severity. The average pre-operative score was 7.2, with 7 patients having maximum VAS score of 8. Post operatively the average VAS score is 3.1, showing significant pain improvement. The minimum post op VAS score was 2 and the maximum was 7.

VAS Score	
Pre-operative	7.2
Post-Operative	3.1

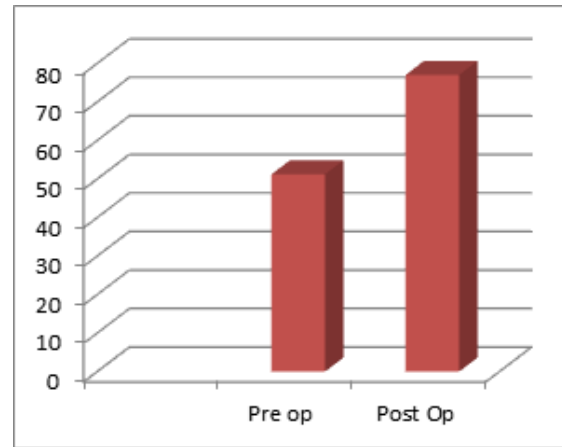
Knee activity was assessed by using Knee Society Score (KSS). Pre-operatively in our study average of KS Score is 51.2, which becomes 77 post operatively in average. There is massive improvement of movement & ambulation. Maximum Knee Society score post operatively was 88.

Knee Society Score	
Pre-operative	51.2
Post-Operative	77

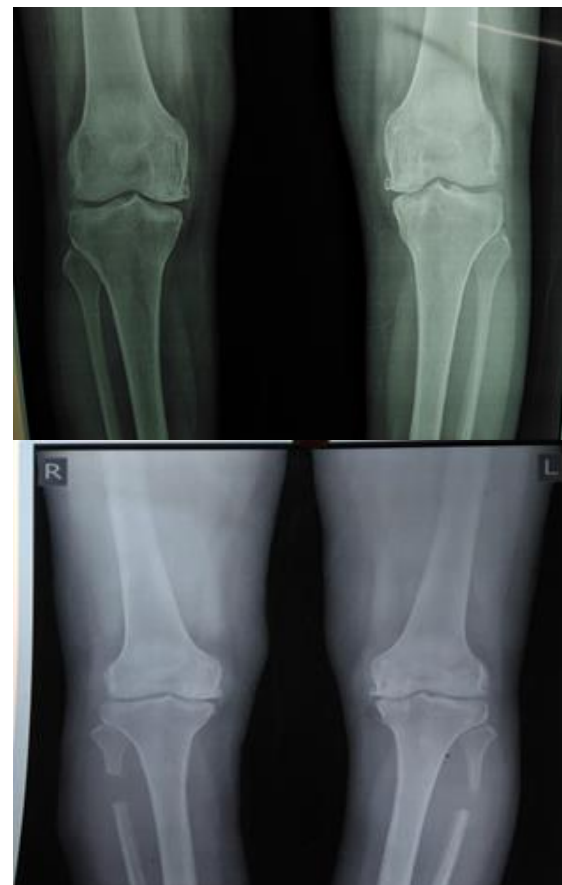

VAS Score

The average duration of surgery was 20-30 min. Among 20 knees, one developed superficial infection at surgical site and 3 patients developed tingling, numbness as a complication.



Knee Society Score



**DISCUSSION**

The surgical options available for medial condyle knee osteoarthritis are limited to High Tibial Osteotomy and Unicdylar Knee Replacement. High tibial osteotomy corrects the varus deformity associated with medial compartment arthritis of the knee and Unicdylar knee arthroplasty produced mixed results according to various studies found in

literature.<sup>[8]</sup> The benefit of PFO is first reported by Zhang et al.<sup>[9]</sup> in 2015. The most important finding in this study was medial pain relief and improvement of medial joint space. The ageing process leads to decrease bone mass in elderly. At proximal tibia, the lateral support of fibula to lateral tibial plateau leads to non-uniform weight distribution. The slope of tibial plateau arising from non-uniform settlement results in transverse shearing force with a cycle of increasing load on medial side. Proximal fibular osteotomy weakens the lateral fibular support, leading to correction of varus deformity and subsequently shifting the loading force from the medial compartment to the lateral compartment.

In our study, symptomatic pain relief seen in all our patients. The average VAS score was significantly reduced to 3.1 from preoperative score of 7.2. In the study of Zhang et al.<sup>[9]</sup> (2015), the found that preoperative VAS score of 7 was reduced to 2 post operatively. In another study of Wang et al.<sup>[10]</sup> (2017) mean visual analogue scale scores significantly decreased from  $8.02 \pm 1.50$  preoperatively to  $2.74 \pm 2.34$  postoperatively. In another study Subash & Naidu in 2018 found that average VAS score 6.9 was reduced to 2.1 postoperatively.<sup>[8]</sup> Knee mobility was measured by knee society scoring, significant improvement 51.2 pre operatively to 77 post operatively was found in our study. The result is similar to the study of Yang et al,<sup>[11]</sup> 150 patients with medial compartment arthritis were followed up for a period of more than 2 years. The preoperative KSS score was  $45 \pm 21.3$  while postoperatively it was  $92.3 \pm 31.7$ . In study of Bo Liu et al.<sup>[12]</sup> with 111 knees, the average preoperative KSS was  $49.14 \pm 10.95$  while postoperatively it was  $67.77 \pm 11.08$ .

Among 3 knees, who developed numbness due to superficial peroneal nerve injury symptoms of nerve injury resolved for 2 patients in 6 months follow up, but in one patient it didn't resolve even with 12 month follow up, though the area of sensory deficit reduced. Qin D et al,<sup>[13]</sup> also had overall complication rate of 11.94%.

## CONCLUSION

The overall results have encouraged us to perform the proximal fibular osteotomy as it reduces pain and improves function. Though patient selection is very important and surgical outcome depends on severity of disease and pre-operative knee function. Success of PFO depends on correct level of osteotomy. Although provide good outcome in short term follow up and a simple, economical surgery, yet to reach to a reasonable conclusion a long term follow up period is needed.

## REFERENCES

1. Andriacchi TP. Dynamics of knee malalignment. *Orthop Clin North Am.* 1994 Jul;25(3):395-403. PMID: 8028883.
2. Miyazaki T, Wada M, Kawahara H, Sato M, Baba H, Shimada S. Dynamic load at baseline can predict radiographic disease progression in medial compartment knee osteoarthritis. *Ann Rheum Dis.* 2002 Jul;61(7):617-22. doi: 10.1136/ard.61.7.617. PMID: 12079903; PMCID: PMC1754164.
3. Andrew H, Crenshaw Jr. Soft tissue procedures and corrective osteotomy about the knee. Elsevier. Campbell's operative orthopedics. 13th Ed.
4. Sprenger TR, Doerzbacher JF. Tibial osteotomy for the treatment of varus gonarthrosis. Survival and failure analysis to twenty-two years. *J Bone Joint Surg Am.* 2003 Mar;85(3):469-74. Erratum in: *J Bone Joint Surg Am.* 2003 May 85-A(5):912. PMID: 12637433.
5. Zheng, Z., Sun, Y., Zhang, X., Chen, W., Li, S., & Zhang, Y. (2014). The pathogenesis and clinical imageology research of the knee osteoarthritis. *Journal of Hebei Medical University*, 35(5), 599-600.
6. Boonstra AM, Schiphorst Preuper HR, Reneman MF, Posthumus JB, Stewart RE. Reliability and validity of the visual analogue scale for disability in patients with chronic musculoskeletal pain. *Int J Rehabil Res.* 2008 Jun;31(2):165-9. doi:10.1097/MRR. 0b013e3282fc0f93. PMID: 18467932.
7. Scuderi GR, Bourne RB, Noble PC, Benjamin JB, Lonner JH, Scott WN. The new Knee Society Knee Scoring System. *Clin Orthop Relat Res.* 2012 Jan;470(1):3-19. doi: 10.1007/s11999-011-2135-0. PMID: 22045067; PMCID: PMC3237971.
8. Dr. Yeshwanth Subash and Dr. Gunalan K Naidu. The role of proximal fibular osteotomy in the management of medial compartment osteoarthritis of the knee. *International Journal of Orthopaedics Sciences.* 2018; 4(3): 369-372. DOI: 10.22271/ortho.2018.v4.i3g.63
9. Zhang Y, Li C, Li J. The pathogenesis research of non-uniform settlement of the tibial plateau in knee degeneration and varus. *J Hebei Med Univ.* 2014;35(2):218-9
10. Wang X, Wei L, Lv Z, et al. Proximal fibular osteotomy: a new surgery for pain relief and improvement of joint function in patients with knee osteoarthritis. *J Int Med Res.* 2017;45(1):282-289. doi:10.1177/0300060516676630
11. Yang ZY, Chen W, Li CX, Wang J, Shao DC, Hou ZY, Gao SJ, Wang F, Li JD, Hao JD, Chen BC, Zhang YZ. Medial Compartment Decompression by Fibular Osteotomy to Treat Medial Compartment Knee Osteoarthritis: A Pilot Study. *Orthopedics.* 2015 Dec;38(12):e1110-4. doi: 10.3928/01477447-20151120-08. PMID: 26652332.
12. Liu B, Chen W, Zhang Q, Yan X, Zhang F, Dong T, Yang G, Zhang Y. Proximal fibular osteotomy to treat medial compartment knee osteoarthritis: Preoperational factors for short-term prognosis. *PLoS One.* 2018 May 24;13(5):e0197980. doi: 10.1371/journal.pone.0197980. PMID: 29795669; PMCID: PMC5967722.
13. Qin D, Chen W, Wang J, et al. Mechanism and influencing factors of proximal fibular osteotomy for treatment of medial compartment knee osteoarthritis: A prospective study. *J Int Med Res.* 2018;46(8):3114-3123. doi:10.1177/0300060518772715

**Copyright:** © the author(s), 2020. It is an open-access article distributed under the terms of the Creative Commons Attribution License (CC BY 4.0), which permits authors to retain ownership of the copyright for their content, and allow anyone to download, reuse, reprint, modify, distribute and/or copy the content as long as the original authors and source are cited.

**How to cite this article:** Saha A, Chatterjee S, Mukherjee P, Ghosh S. Study of Clinical Outcome of Management of Medial Compartment Osteoarthritis of Knee by Proximal Fibular Osteotomy. *Ann. Int. Med. Den. Res.* 2020; 6(6):OR07-OR10.

**Source of Support:** Nil, **Conflict of Interest:** None declared