

# Analysis of Outcome of Thoraco Lumbar Fractures by Posterior Spinal Stabilization

K. Vamshidhar Reddy<sup>1</sup>, G. Venu<sup>1</sup>, A. Pavan Kumar<sup>2</sup>, Ch.Ramu<sup>2</sup>, Balaga Revanth<sup>3</sup>, V.Abhishek<sup>3</sup>

<sup>1</sup>Associate Professor, Department of Orthopaedics, CAIMS, Karimnagar, Telangana.

<sup>2</sup>Professor, Department of Orthopaedics, CAIMS, Karimnagar, Telangana.

<sup>3</sup>Senior Resident, Department of Orthopaedics, CAIMS, Karimnagar, Telangana.

Received: October 2020

Accepted: October 2020

## ABSTRACT

**Background:** Thoracolumbar fracture is the most common skeletal injury of the axial skeleton and accounts for around 90% of all spinal fractures. Neurological symptoms may affect up to 40% of the patients, thereby explaining the high morbidity associated with these lesions. The management of these injuries largely depends on several factors, including demographic, socio-economic and infrastructural issues, apart from the general medical and injury-related patient status. Aims And Objectives: To evaluate the functional and neurological recovery of unstable thoracolumbar fractures treated by indirect decompression, posterior stabilization of short segment or long segment with pedicle screw fixation.

**Methods:** Twenty-Four patients of unstable thoracolumbar fractures involving T9 to L5 who were admitted between December 2016 to September 2018, in Chalmeda Anada Rao Institute of Medical Sciences, Karimnagar, Telangana were treated by posterior indirect decompression with short segment or long segment posterior instrumentation with pedicle screw system. This prospective study included 13 unstable burst fractures, 8 anterior wedge compression fractures and 2 fracture dislocations and 1 chance fracture. The unstable fracture was defined by clinical and radiological parameters. The study includes 20 males and 4 females. The age group involved in our study ranged between 17 years and 75 years. All the patients were admitted in the emergency ward and resuscitated appropriately. Complete clinical and neurological examination was done. The level of spine injury was assessed clinically and radiologically. The spinal injuries were classified based on Denis classification system in this study. The patient's neurological deficit was quantified as per Frankel's et al grading. All the patients underwent magnetic resonance imaging to know the status of the cord, integrity of the posterior longitudinal ligament, presence of disc herniations and the degree of canal compromise. Ultrasonogram abdomen was done and visceral injuries were ruled out. These patients underwent either short segment or long posterior instrumentation. **Results:** All patients showed improvement in denis pain scale and denis work scale. **Conclusion:** Early surgery had better outcome and rehabilitation. Posterior Stabilization with pedicle screw along with the orthotic appliances for a considerable period of time reduces the chances of implant failure and prevents further collapse of the injured vertebra and achieves a reasonable stability till the segment is fused. Short segment posterior instrumentation preserves the motion segment, improves functional outcome and rehabilitate the patients with minimal surgical morbidity where as long segment fixation decreases load on the vertebrae. Fixing of unstable spine is well rewarded with reduced fracture pain, making the patient to sit up and avoiding the complications of recumbency like pressure sore, urinary infections, deep vein thrombosis, pneumonitis and aids in neurological recovery especially in partial neurological deficit patients.

**Keywords:** Keywords: Fracture, Thoracolumbar, Spine.

## INTRODUCTION

Thoracolumbar fracture is the most common skeletal injury of the axial skeleton and accounts for around 90% of all spinal fractures.<sup>[1]</sup> They result from vertical compression to the slightly flexed spine, a rotational or shear component or some extension force can cause a different fracture

pattern. Neurological symptoms may affect up to 40% of the patients, thereby explaining the high morbidity associated with these lesions.<sup>[2]</sup> The common mode of spine injury is a fall from height or a road accident. Most of them involve patients in the young, active age group. This causes financial burden for the family in particular and the country in general. In the past few decades there have been advancements in diagnostic imaging techniques, more stable fixation devices and intra-operative monitoring. The management of these injuries largely depends on several factors, including demographic, socio-economic and infrastructural issues, apart from the general medical and injury-related patient status.<sup>[3]</sup>

### Name & Address of Corresponding Author

K.Vamshidhar Reddy  
Associate Professor,  
Department of Orthopaedics,  
CAIMS, Karimnagar, Telangana  
Email: [vamsidoc@yahoo.com](mailto:vamsidoc@yahoo.com)

Despite these advancements, managing these fractures still pose a challenge to orthopedic surgeons. The ideal treatment for thoracolumbar burst fractures is controversial regarding the use of short or long posterior fixation constructs.<sup>[4]</sup> Long posterior fixation with pedicle screws and rods two-levels above and below the fracture level provide better fixation; however, it results in potentially extraneous instrumentation and increased load on the lower discs.<sup>[5]</sup> Short posterior fixation using pedicle screws with interconnected rods one-level above and below the fracture level not only limits the number of fused segments, but also prevents excessive loads on the adjacent discs. The use of short posterior fixation for burst fractures describe high rates of failure in fixation and kyphotic collapse.<sup>[6]</sup>

A Short segment posterior instrumentation with Pedicle screw system in spinal injuries achieves a reasonable stability since the pedicle screw and rod system provides a three-column fixation in stabilizing the injured spinal column incorporating fewer motion segment in the fusion.<sup>[7,8]</sup> Surgical indirect decompression and posterior stabilization in spinal injuries enables the patient to become ambulant without much pain and gives a fair chance of neurological recovery when the compressed neural elements are released.<sup>[9]</sup>

It increases of the longevity of the patient and decreases the morbidity due to prolonged recumbency in case of complete cord lesions.<sup>[6]</sup> Moreover, operative management helps in executing better nursing care to paraplegics otherwise whose quality of life will decline.

#### **Aim of the Study**

To evaluate the functional and neurological recovery of unstable thoracolumbar fractures treated by indirect decompression, posterior stabilization of short segment or long segment with pedicle screw fixation.

## **MATERIALS AND METHODS**

Twenty-Four patients of unstable thoracolumbar fractures involving T9 to L5 who were admitted between December 2016 to September 2018, in Chalmeda Anada Rao Institute of Medical Sciences, Karimnagar, Telangana were treated by posterior indirect decompression with short segment or long segment posterior instrumentation with pedicle screw system.

This prospective study included 13 unstable burst fractures, 8 anterior wedge compression fractures and 2 fracture dislocations and 1 chance fracture.

The unstable fracture was defined by clinical and radiological parameters. The posterior ligaments have probably failed if there is greater than 30° of kyphosis and/or 50% of vertebral body height loss 10, wedge compression fractures involving middle

column with neurological deficit and fracture dislocations with neurological deficit. The study includes 20 males and 4 females.

The age group involved in our study ranged between 17 years and 75 years. All the patients were admitted in the emergency ward and resuscitated appropriately. Complete clinical and neurological examination was done. In our study only 3 patients presented to us within 8 hours and they had been given Methylprednisolone as per NACIS III protocol. The level of spine injury was assessed clinically and radiologically.

The spinal injuries were classified based on Denis classification system in this study.

#### **Inclusion Criteria**

Unstable burst fracture, Fracture dislocation, Anterior wedge compression fracture, Chance fracture.

#### **Exclusion Criteria**

Stable burst fracture, Stable anterior wedge compression fracture, Late presentation with large pressure sores, Elderly with severe osteoporosis and Poor anesthetic risk, poly trauma with head injury

The patient's neurological deficit was quantified as per Frankel's et al grading.

According to Frankel's et al grading, 11 patients with grade A, 3 patients with grade B, 7 patients with grade C and 3 patient with grade D.

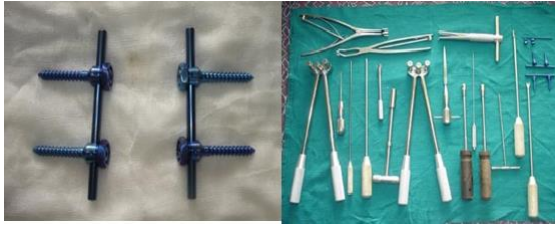All the patients underwent magnetic resonance imaging to know the status of the cord, integrity of the posterior longitudinal ligament, presence of disc herniations and the degree of canal compromise. Ultrasonogram abdomen was done and visceral injuries were ruled out. These patients underwent either short segment or long posterior instrumentation.

#### **Operative Technique**

General anesthesia was given by a cuffed endotracheal tube. The patient was placed in prone position in operating table such a way the abdomen is free from pressure. The level of the injured spine as marked by C arm was taken as center of the incision. The dorso-lumbar spine was approached by midline incision and the dorso-lumbar fascia was incised in line with skin incision. The spinous processes were identified and the plane between spinous processes and paraspinal muscles laterally was made. The paraspinal muscles were elevated sub periosteally and reflected laterally with a self-retaining spinal retractor. The pedicles were identified by a point where the middle of the transverse process and the longitudinal axis of the superior facet meet. The pedicle screws were passed under image intensifier control after probing the pedicle and measuring its depth. The commonly used screw size in our study include 5 mm for

thoracic pedicles and 6 mm for lumbar pedicles. Then the pedicle screws were bridged with two connecting rods fixed with an inner screw. Wound closed in layers with a negative suction drain after attaining perfect hemostasis.

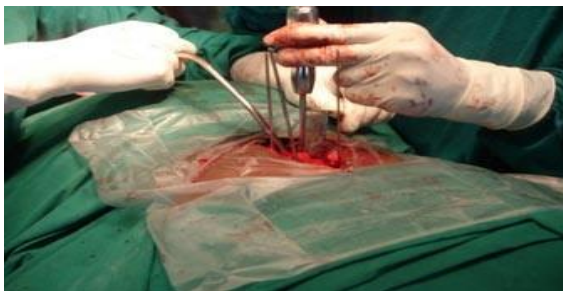**RESULTS**



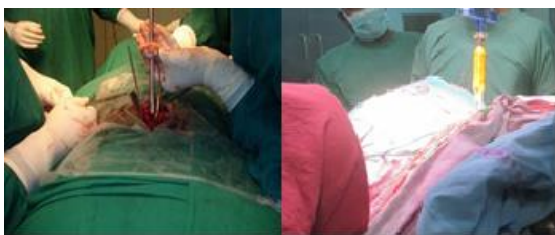**Figure 1: Instruments and Implants**



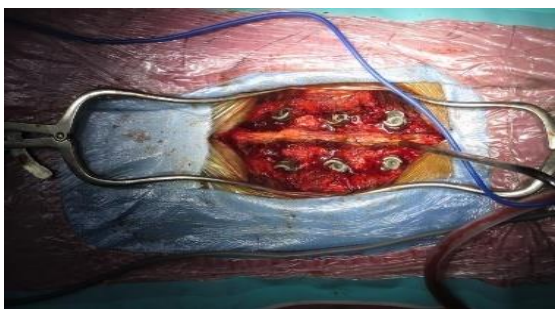
**Figure 2: Intraoperative Pictures Skinincision identification of pedicles**



**Figure 3: Entrywithawl.**



**Figure 4: Insertion Ofscrews**



**Figure 5: Pedicle Screws.**

The Following observations were made. In our study we had 20 males (83.33%) and 4 females (16.66%) patients who sustained spinal

injuries with neurological deficit and most of them had a fall from height (n=12). The male to female ratio was 5: 1.

The most common mode of injury in our study was fall from height (80 %).

The minimum age group was 17 years and the maximum age group was 75 years in our study. The mean age 35.37years.

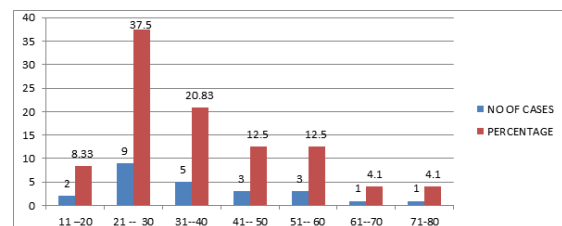
We had 13 burst fractures (54.16%), 8 wedge compression fractures (33.33%) and 2 fracture dislocations (13.33%),1 chance fracture in our study.

In our study all the cases underwent posterior indirect decompression with posterior stabilization. All the patients were operated between 4- and 8-days days of initial injury. Neurologic function improved by at least one Frankel grade in sixteen (16) (84.21%) patients with neurological deficit.

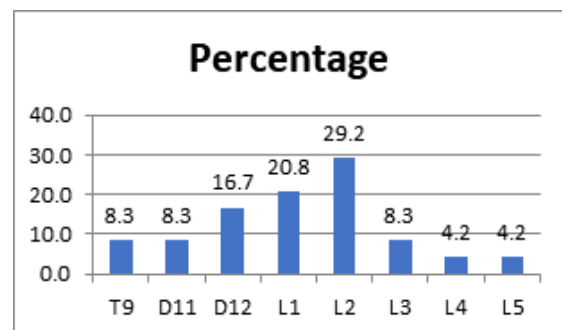
Neurologic function improved by at least one Frankel grade in fourteen (14) patients and two grades in four (4) patients with incomplete neurologic deficits. Neurologic function improved by at least two Frankel grades in six (6) and three grades in four patients. Neurologic function remained at the preoperative level in two patients with complete neurologic deficits.

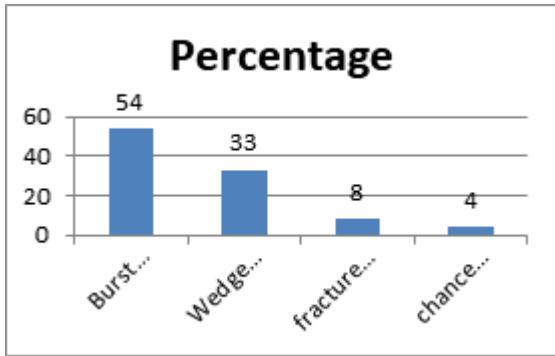
Considering white and Punjabi instability score surgery was considered for those in Frenkel grade E as they were unable to walk and has severe pain

In this study Denis pain scale showed that 33.3% of patients had minimal pain, 33.3 % of patient had moderate pain and 16.7% had moderate to severe pain with significant changes in daily activities and no pain in 16.7% the Denis work assessment scale showed that 37.5 % of patients had unable to return to the previous job but can able to work full time with job modification, 8.3 % of patients cannot able to work full time and 12.5% of patients were completely disabled.



**Graph 1: Percentage of Age Wise Distribution**





Graph 2: Level, And Their Percentage Of Distribution

Table 1: Percentage of the cases in frankel grade

Type of lesion	No of cases	Percent
A	11	45.83
B	3	12.5
C	7	29.16
D	3	12.5
E	0	0
Total	24	100

Table 2: Preoperative and postoperative neurological status

Pre op neurological status	Post op neurological status
Frankel Grade A - 11 Cases (45.83%)	A to D (3 Case) A to C (6 Cases) A to A (2 Cases)
Frankel Grade B - 3 Cases (12.5%)	B to D (3 Cases)
Frankel Grade C - 7 Cases (29.16%)	C to E (2 Case) C to D (5 Cases)
Frankel Grade D - 3 Cases (12.5%)	D to E (3 Cases)

Table 3: Percentage and Number According to Denis Pain Scale

Denis pain scale	No of patients	Percentage
P1	2	8.3
P2	10	41.7
P3	8	33.3
P4	4	16.7
P5	0	0.0
Total	24	100.0

Table 4: Percentage and Number of Patients According to Denis Work Scale

Denis work scale	No of patients	Percentage
W1	1	4.2
W2	6	25.0
W3	6	25.0
W4	5	20.8
W5	6	25.0
Total	24	100.0

**Illustrated Cases**

**Cases 1:**

In case 1 a 75 year old traumatize patient presented with L1 wedge compression fracture. Clinically in Frankel grade B neurology, underwent surgery at 2 weeks of injury with decompression, short segmented instrumentation with pedicle screw and rod construct. The postoperative course was uneventful At final follow up she was in Frankel

grade D. Dennis pain assessment scale was P3 and work assessment was W2.

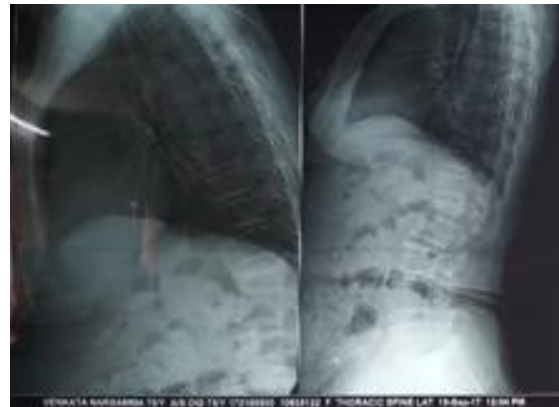

Image 1: Pre-Operative X-Ray Shows Wedge Compression of L1 Vetebrae

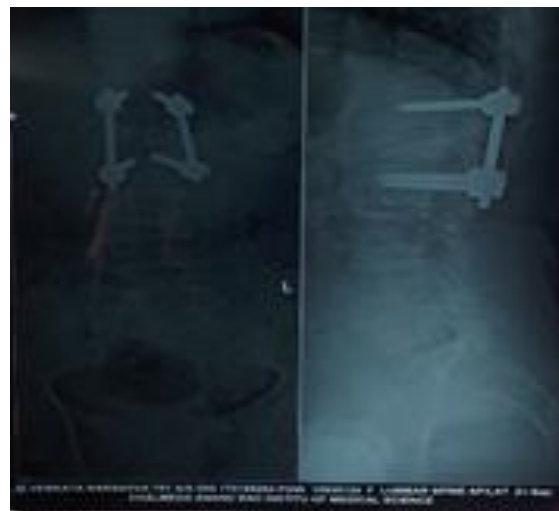

Image 2: Immediate Post-Operative Pictures

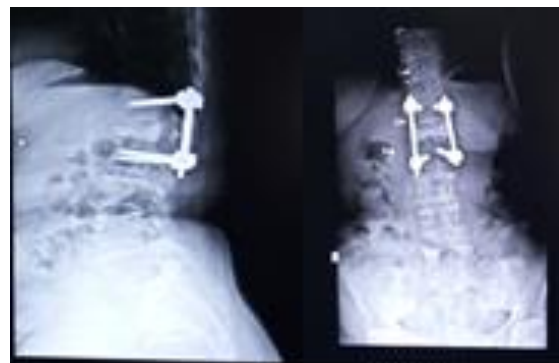
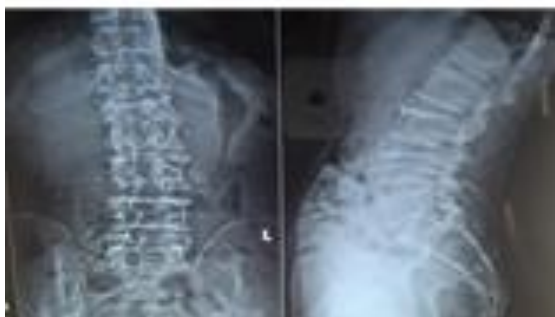
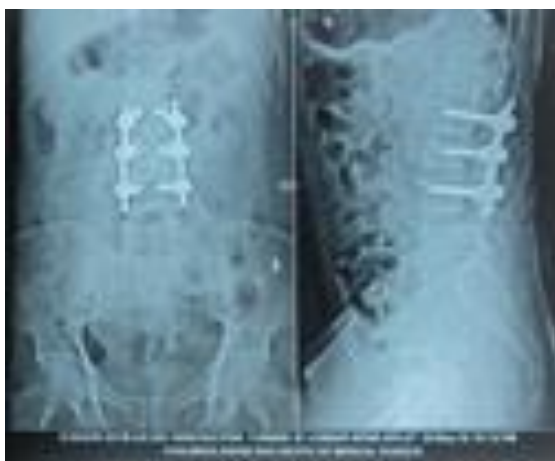Image 3: At 3 Months Follow Up Period

**Case 2:**

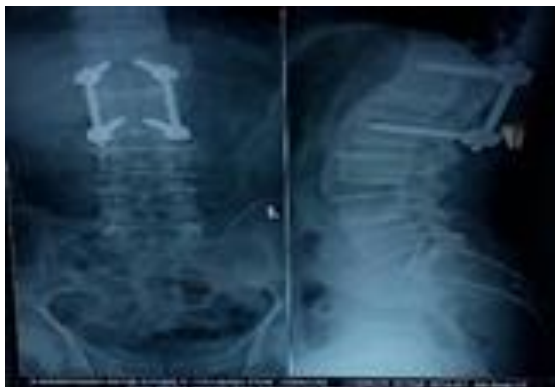In a 52 year old traumatize patient presented with L1 wedge compression fracture. Clinically in Frankel grade A neurology, Treated with decompression, short segmented instrumentation with pedicle screw and rod construct. The postoperative course was uneventful. At final follow up he was in Frankel grade D. Dennis pain assessment scale was P1 and work assessment scale was W2.



**Image 4: Pre op X-Ray showing wedge compression of 11 vertebrae**



**Image 5: Immediate postop**



**Image 6: At 3 Months Follow Up**



**Image 7: 3 Months Post Op - Clinical Picture**

## DISCUSSION

The most important aspect of the surgical management of thoracolumbar fractures is to minimize the complications and for early recovery. Pain relief and radiological correction are major outcome criteria for surgical treatment of thoracolumbar fractures.<sup>[11]</sup>

The mean age of presentation is 35.37 years in our study which is comparable to other studies. Arif et al. reported in their study the mean age of the patients was 32 years (range 20-65 years).<sup>[12]</sup> Butt et al. reported in their study mean age 33.6 years (range 20-50 years).<sup>[13]</sup> Knop et al. reported mean age 34 years.<sup>[14]</sup> Benzel reported mean age 36 years.<sup>[15]</sup> Danisa et al. reported mean age of patients to be 36.6 years. Benzel,<sup>[15]</sup> Knop et al.<sup>[14]</sup> Butt et al.,<sup>[13]</sup> Arif et al.,<sup>[12]</sup> Tezer et al. Siebenga et al. and Danisa et al. described male predominant studies.

In our study we have a male predominance males and female ratio is about 5:1.

The vast majority of these injuries affect the motion segments between T11 and L2 at the thoracolumbar junction.<sup>[16]</sup> The vertebrae mostly involved in our study was L2, with predominance of 12<sup>th</sup> Thoracic vertebrae and 1st Lumbar vertebrae.

In a study by Asifur Rahman Fall from height (79%) was most common and next is road traffic accident (21%)<sup>[17]</sup> Butt et al. in a study reported 90% cause was fall from height.<sup>[18]</sup>

Knop et al.<sup>[14]</sup> also reported in his study that fall from height as the major of cause of injury. Arif et al.<sup>[12]</sup> reported Road Traffic Accident as the major cause of injury in their studies.

In a study by Helton et al, Denis pain scale showed 44 % patients had no pain and 17 % had moderate pain to severe pain two years after surgery.

While in this study 33.3% patients had minimal pain, 33.3 % patient had moderate pain and 16.7% had moderate to severe pain with significant changes in daily activities and no pain in 16.7%.

In this study, Denis work assessment scale showed that, 37.5% patients had unable to returned to the previous job but can able to work full time with job modification, 8.3 % patients cannot able to work full time and 12.5 % patients were completely disabled.

Rex A.W. Marco et al reported that the neurological function improved by at least one Frankel grade in 83% of the patients with complete neurological deficit in his study.

In this study 84.21 % improvement in neurological function by one Frankel grade was observed in patients with complete neurological deficit.

The most important factor responsible for prognosis and neurological recovery is the neurological status at the time of injury. Surgical decompression (Direct or indirect) and stabilization with or without fusion improves the neurological recovery especially in incomplete cord lesions.

Out of 16 cases, 14 cases with incomplete lesions have recovered well when compared to complete lesions in our study. 71% of patients improved at least one Frankel grade in the entire series by a study done by S.Mondal.<sup>[19]</sup>

- Non-operative care avoids anesthetic risk and morbidity of surgery but increases the risks of prolonged recumbency and hospital stay.
- The current surgical management corrects the deformity, enhances the neurological recovery, and allows early mobilization and return to work, with minimal complication.<sup>[20,21]</sup>
- With improved investigations and advanced stabilization systems and intra operative monitoring of cord function the outlook for patients with thoracolumbar fractures with neurological deficits have improved and can be enhanced if an optimum environment for neurological recovery is provided.<sup>[22]</sup>

Posterior short segment fixation including the proximal and distal adjacent normal vertebrae are the most commonly performed surgeries for the vast majority of thoracolumbar fractures (unstable burst fractures with intact neurology, flexion distraction injury, Chance fractures).

Disadvantages include instrumentation failure, pseudarthrosis, infection, risks of Spina Cord Injury, inadequate neurological decompression, insufficient correction of kyphosis and the need for late instrumentation removal.<sup>[27]</sup>

The pedicle screw systems with large fixation screws implanted through the pedicle into the vertebral body are better systems biomechanically. They are the only device which allows three column fixations of the vertebral column and in areas where the lamina have been removed. They provide excellent stability in fracture spine. A short segment fixation with pedicle screw achieves reasonable stability till the segment is fused. This is so because a pedicle screw achieves a three column fixation and proper stability than the other posterior systems that were used previously.

The main advantage of short segment posterior instrumentation is that it preserves the motion segment resulting in less spinal stiffness and also avoiding flat back syndrome.<sup>[23,24]</sup> When short-segment fixation was compared to long-segment fixation, the radiographic parameters were more favorable in the latter but the clinical outcome was the same for both methods,<sup>[25,26]</sup> short posterior fixation alone has also shown to provide good clinical and radiological outcomes in certain fractures, especially in the more lordotic middle and lower lumbar spine, in which the compressive forces act more posteriorly.<sup>[28]</sup>

Ayberk et al,<sup>[29]</sup> reported the posterior approach is better in the short term and in follow-up, with advantages being.

1. The posterior approach is simple, with less trauma, blood loss, cost, and better recovery of neurologic function;
2. Anterior decompression could be completed through the inside of the pedicle; and
3. Through internal fixation, the posterior longitudinal ligament pulls the bone block of the anterior canal back, achieving decompression indirectly.

## CONCLUSION

Early surgery had better outcome and rehabilitation. Posterior Stabilization with pedicle screw along with the orthotic appliances for a considerable period of time reduces the chances of implant failure and prevents further collapse of the injured vertebra and achieves a reasonable stability till the segment is fused. Short segment posterior instrumentation preserves the motion segment, improves functional outcome and rehabilitate the patients with minimal surgical morbidity where as long segment fixation decreases load on the vertebrae. Fixing the unstable spine is well rewarded with reduced fracture pain, making the patient to sit up and avoiding the complications of recumbency like pressure sore, urinary infections, deep vein thrombosis, pneumonitis and aids in neurological recovery especially in partial neurological deficit patients.

## REFERENCES

1. Aligizakis A, Katonis P, Stergiopoulos K, Galanakis I, Karabekios S, Hadjipavlou A. Functional outcome of burst fractures of the thoracolumbar spine managed non-operatively, with early ambulation, evaluated using the load sharing classification. *Acta Orthop Belg.* 2002;68(3):279–287.
2. McAfee PC, Yuan HA, Lasda NA. The unstable burst fracture. *Spine (PhilaPa1976)*1982;7(4):365–373.
3. Burke DC, Murray DD. The management of thoracic and thoraco-lumbar injuries of the spine with neurological involvement. *J Bone Joint Surg Br.* 1976;58:72–78
4. Modi HN, Chung KJ, Seo IW, et al. Two levels above and one level below pedicle screw fixation for the treatment of unstable thoracolumbar fracture with partial or intact neurology. *J Orthop Surg Res.* 2009;4:28
5. Tezeren G, Gumus C, Bulut O, Tukenmez M, Oztemur Z, Sever G. Anterior versus modified combined instrumentation for burst fractures of the thoracolumbar spine: a biomechanical study in calves. *J Orthop Surg (Hong Kong)*2008
6. McLain RF, Sparling E, Benson DR. Early failure of short-segment pedicle instrumentation for thoracolumbar fractures: a preliminary report. *J Bone Joint Surg Am.* 1993;75:162–167.
7. Jeffrey WP, Joel RL, Eldin EK, Robert WG. Successful Short-Segment Instrumentation and Fusion for Thoracolumbar Spine Fractures A Consecutive 4 1/2-Year Series. *Spine.*2000;25:1157–1169.
8. Broom MJ, Jacobs RR. Current Status of Internal Fixation of Thoracolumbar Fractures. *J Orthop Trauma*1989;3:148.
9. Sanderson PL, Fraser RD, Hall DJ, Cain CM, Osti OL, PotterGR. Short segment fixation of thoracolumbar burst fractures without fusion. *Eur Spine J.* 1999;8(6):495-500.

10. Rechtine GR. Nonsurgical treatment of thoracic and lumbar fractures. Instr Course Lect. 1999;48:413–6.
11. Reid DC, Hu R, Davis LA, Saboe LA. The nonoperative treatment of burst fractures of the thoracolumbar junction. J Trauma. 1988;28:1188–1194
12. Arif M, Inam M, Satar A, Saeed M, Shabir M (2009) Management of thoracolumbar spinal fractures by pedicular screws and rods. Gomal Journal of Medical Sciences 7: 109-113.
13. Sasso RC, Costler HB : Posterior Instrumentation and fusion for unstable fractures and fracture-dislocations of the thoracic and lumbar spine. Spine 1993;18:450–60
14. Jacobs RR, Casey MP. Surgical management of thoracolumbar spinal injuries. Clin Orthop Relat Res 1984;189:22–35.
15. Aebi M, Etter C, Kehl T. Stabilization of the lower thoracic and lumbar spine the internal spine skeletal fixation system. Indication, technique, and first results of treatment. Spine 1987;12:544–51.
16. Gertzbein S. Scoliosis Research Society. Multicenter spine fracture study. Spine 1992;17:528–40.
17. SH Lee et al: Short segment fixation for thoracolumbar fractures IJO April – June 2009; 43 Issue (2) 199
18. Olerud S, Karlstrom G, Sjostrom L. Transpedicular fixation of thoracolumbar vertebral fractures. Clin Orthop Relat Res. 1988;227:44-51.
19. Rex A.W. Marco and Vivek P. Kushwaha unstable burst fractures treated with balloon-assisted calcium phosphate reconstruction J Bone Joint Surg Am. 2009; volume 91 number 1 P26
20. Dashti et al: Decision making in thoracolumbar fractures Neurology India December 2005;53 Issue (4) 538
21. Glaser JA, Estes WJ. Distal short segment fixation of thoracolumbar and lumbar injuries. Iowa Orthop J. 1998;(18):87-90.
22. Parker JW, Lane JR, Karakovic EE, Gaines RW. Successful short- segment instrumentation and fusion for thoracolumbar spine fractures: a consecutive 41/2-year series. Spine (Phila Pa 1976). 2000; 25(9):1157-1170.
23. Sanderson PL, Fraser RD, Hall DJ, Cain CM, Osti OL, Potter GR. Short segment fixation of thoracolumbar burst fractures without fusion. Eur Spine J. 1999;8(6):495-500.
24. SH Lee et al: Short segment fixation for thoracolumbar fractures IJO April – June 2009; 43 Issue (2) 201
25. Tezeren G, Kuru I. Posterior fixation of thoracolumbar burst fractures: Short segment pedicle fixation versus long segment instrumentation J Spinal Disord Tech 2005; 18 : 485-8
26. Qian BP, Qiu Y, Wang B, Yu Y, Zhu ZZ. Effect of posterolateral fusion on thoracolumbar burst fractures. Chin J Traumatol. 2006; 9(6):349-355.
27. Long-term results of thoracolumbar and lumbar burst fractures after short-segment pedicle instrumentation, with special reference to implant failure and correction loss.
28. Short Segment versus Long Segment Pedicle Screws Fixation in Management of Thoracolumbar Burst Fractures: Meta-Analysis. Asian Spine J. 2017;11(1):150-160.
29. Ayberk G, Ozveren MF, Altundal N, Tosun H, Seckin Z, Kilicarslan K. Three column stabilization through posterior approach alone: transpedicular placement of distractable cage with transpedicular screw fixation. Neurol Med Chir (Tokyo) 2008;48(1):8–14.

**Copyright:** © the author(s), 2020. It is an open-access article distributed under the terms of the Creative Commons Attribution License (CC BY 4.0), which permits authors to retain ownership of the copyright for their content, and allow anyone to download, reuse, reprint, modify, distribute and/or copy the content as long as the original authors and source are cited.

**How to cite this article:** Reddy KV, Venu G, Kumar AP, Ramu C, Revanth B, Abhishek V. Analysis of Outcome of Thoraco Lumbar Fractures by Posterior Spinal Stabilization. Ann. Int. Med. Den. Res. 2021; 7(1):OR01-OR07.