

Proximal Fibular Osteotomy: A Novel Technique for Management of Medial Compartment Knee Osteoarthritis.

Nitin Kumar Agrawal¹, Sukh Sagar Vaishya¹

¹Assistant Professor, Department of Orthopedics, Heritage institute of Medical Sciences, Varanasi.

Received: November 2018

Accepted: November 2018

Copyright: © the author(s), publisher. It is an open-access article distributed under the terms of the Creative Commons Attribution Non-Commercial License, which permits unrestricted non-commercial use, distribution, and reproduction in any medium, provided the original work is properly cited.

ABSTRACT

Background: For medial compartment knee OA, which is usually seen in the age group 40-50 years, total knee replacement is not recommended ideally. Hence, for these patients, there is need of a new procedure which would be safe, effective & affordable. **Objective:** The aim of this study is to evaluate the early benefits of proximal fibular osteotomy (PFO) in medial compartment knee OA. **Methods:** Total 50 patients (70 knees) with medial compartment OA included in this study from march 2017 to august 2017. All patients were managed by PFO and followed-up prospectively for minimum upto 12 months. Visual analogue scale to assess knee pain, American knee society score (AKSS) to evaluate knee functions and medial/lateral joint space ratio were used for radiological assessment. Statistical analysis done by using SPSS 20.0 software. **Results:** All patients observed significant relief in knee pain after PFO. AKSS and medial/lateral joint space ratio improved significantly post-operatively. Most of the patients showed increased walking distance post-operatively. **Conclusion:** This study concludes that PFO is a safe & effective method for the management of medial compartment knee OA. It relieves knee pain significantly and improves knee joint function.

Keywords: American knee society score, Medial compartment osteoarthritis, Proximal fibular osteotomy.

INTRODUCTION

Knee osteoarthritis is a chronic progressive disorder of the joint. Pathological characteristics include articular cartilage degeneration & degradation leading to joint pain, deformity, stiffness, dysfunction and decrease range of movement as the main symptoms.^[1,2] It is most commonly seen in older population (>40yrs), especially women. Risk factors associated with knee osteoarthritis are increasing age, obesity, certain lifestyle activities (like squatting, crossed-leg sitting) etc. Conservative management includes NSAIDs, physiotherapy and intra-articular injections (hyaluronic acid, platelet rich plasma or steroid) for early osteoarthritis.^[3,4] Surgical management includes High tibial osteotomy (HTO) or unicondylar knee arthroplasty (UKA) for isolated medial joint arthritis with varus deformity in younger patients and total knee arthroplasty (TKA) for tricompartmental OA in older patients.

But these procedures have certain limitations like prolonged hospitalization, longer post-op recovery, expensive & complex procedure etc. So there is requirement of a procedure which is easy to perform, safe, inexpensive, improves pain & functional results, with shorter hospitalization & recovery period.^[5] In this regard, proximal fibular osteotomy (PFO) is a relatively new procedure but based on previous & ongoing studies, it fulfills all the required criteria. The present study analysed the short term efficacy of PFO in medial joint knee OA.

MATERIALS AND METHODS

From march 2017 to august 2017, total 50 patients diagnosed with medial compartment arthritis and managed by PFO were included in this study. It is an institutional based prospective study. Approval from the institution ethical committee was obtained. Informed consent was taken from all the patients. Inclusion criteria were age > 45 yrs, isolated medial joint arthritis, BMI <30, mild to moderate symptoms. Exclusion criteria were age <45 yrs, tricompartmental OA, BMI >30, severe symptoms, valgus OA & inflammatory joint disease. At the time of admission, wt bearing x-rays (AP & Lat view) of affected knee were taken and

Name & Address of Corresponding Author

Dr. Nitin Kumar Agrawal,
Assistant Professor,
Department of Orthopedics,
Heritage institute of medical sciences,
Varanasi.

pt were assessed clinically & radiologically using visual analogue scale (VAS), American knee society score (AKSS), tibiofemoral angle & ratio of knee joint space (medial/lateral compartment). Patients were operated in supine position under spinal anaesthesia. Tourniquet was used in all cases. A 5-7 cm longitudinal incision was given over lateral aspect of fibula & exposure done between peroneus & soleus muscle. PFO was done removing a 2 cm fibular piece at a distance of 6 to 9 cm from the head of fibula. Bone wax applied over ends of the bone to stop profuse bleeding occasionally. All patients were allowed to stand & walk full wt bearing without support from next day. Post-op wt bearing x-rays were taken on 3rd post-op day & radiological parameters were documented. Pt discharged on 3rd day & stitch removal was done on 12th day. Pts were regularly followed-up in OPD at 1, 3, 6 & 12 months where radiological parameter, VAS & AKSS were evaluated and documented.

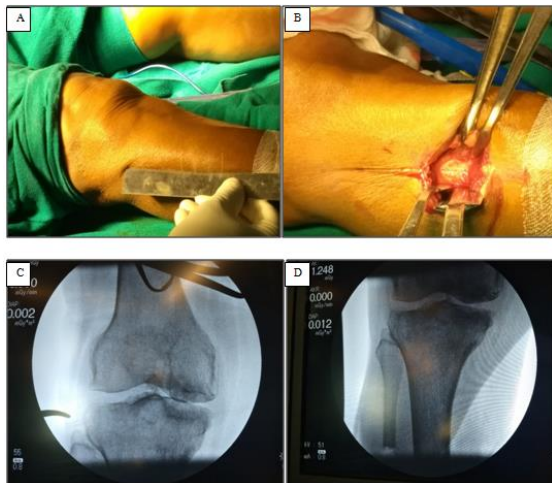


Figure 1A: marking a point 6-9 cm from head of fibula. **B:** dissection carried out through peroneus & soleus muscle. **C:** c-arm image before fibular osteotomy. **D:** c-arm image after fibular osteotomy showing increase in medial joint space.

Statistical analysis

SPSS 20.0 software used for statistical analysis. Data were recorded as mean \pm SD. Paired t-test & Wilcoxon's signed rank test were used to compare the differences in outcome scores (pre-op & post-op values). A value of <0.05 was considered to be statistically significant.

RESULTS

A total of 50 patients with 70 knees (20 bilateral & 30 unilateral OA) were managed with PFO & were followed-up for a minimum period of 12 months. There were 34 females & 16 males with the right knee being more commonly affected. These patients had an average age of 49.5 yrs (range 41-60 yrs) at the time of operation. The average

duration of unilateral PFO was 28.20 ± 8.13 minutes.

Knee pain relief was seen in all patients after surgery. At final follow-up, mean VAS decreased significantly from 7.02 ± 1.05 preoperatively to 2.20 ± 1.50 postoperatively. Mean AKSS was 45.25 ± 13.05 preoperatively, which improved significantly postoperatively 70.08 ± 22.05 . [Table 1]

Table 1: clinical parameters

Clinical score	Pre-op value	Post-op value
VAS	7.02 ± 1.05	2.20 ± 1.50
AKSS	45.25 ± 13.05	70.08 ± 22.05

Radiological parameters also changed significantly after surgery. At final follow-up, ratio of knee joint space (medial/lateral) improved significantly from 0.42 ± 0.26 preoperatively to 0.60 ± 0.30 postoperatively. Mean preoperative femorotibial angle (FTA) was 182.2 ± 1.6 while it was 179.2 ± 1.8 postoperatively. [Table 2]

Table 2: Radiological parameter.

Radiological parameter	Pre-op value	Post-op value
Med/lat joint space ratio	0.42 ± 0.26	0.60 ± 0.30
Femorotibial angle	182.2 ± 1.6	179.2 ± 1.8

Out of 50 patients, 4 developed paraesthesia in lower leg, all of which resolved within 3-9 months. No superficial or deep infection occurred. No other complication seen. No patient was lost to follow-up & all patients were satisfied with the outcome in terms of pain relief & improved knee functions.

DISCUSSION

Knee osteoarthritis is very common joint problem and it causes severe pain, stiffness & functional limitations. Conservative management can relieve the pain but cannot inhibit the progression of the disease. For medial joint knee OA, surgical options include HTO & Unicompartmental knee arthroplasty(UKA). HTO is very effective as it relieves pain & corrects varus deformity, but it has its own limitations like complex procedure, prolonged recovery period & delayed wt bearing until osteotomy site unites.^[6-9] Similarly, UKA has produced mixed results in the management of medial joint arthritis. Some studies suggest that UKA could be associated with problems like component loosening, poly wear or progression of arthritis resulting in high rate of revision surgeries.^[10,11]

So, we need a novel surgical procedure for medial joint OA which should be simple, safe, effective, affordable with shorter recovery period. PFO is a new procedure which fulfills all these needs. PFO relieves knee pain & improves the quality of life of the patients. The mechanism by which PFO works

is not very clear, but one theory suggests that there is uneven load distribution across both tibial plateau, more on medial plateau because lateral support provided to osteoporotic tibia by fibula-soft tissue complex shifts the load medially leading to cartilage destruction & medial joint OA and varus deformity.^[5,12] Thus, by doing PFO, lateral support to tibia weakens leading to increased medial joint space & correction of varus deformity, thus redistributing the load from medial to lateral plateau resulting in alleviation of pain & functional improvement.

In a study by Zou et al, 92 patients (40 PFO & 52 HTO) managed by osteotomy and followed up for 25 months. They compared the results between two groups and concluded that short-term & long-term surgical effects of PFO on varus knee OA are superior to those of HTO.^[1]

In a study by Wang et al, 47 patients with medial compartment arthritis were managed by PFO and followed up for minimum 12 months. Preoperative VAS score significantly decreased from 8.02 ± 1.50 to 2.74 ± 2.34 postoperatively. Preoperative functional American knee society score significantly improved from 41.24 ± 13.48 to 67.63 ± 13.65 postoperatively. They concluded that PFO effectively relieves pain and improves joint function in patients with medial compartment OA.^[13]

In our study, 50 pts (70 knees) with medial joint OA managed by PFO and followed up for a minimum period of 12 months. All patients reported significant relief in pain after surgery (VAS decreased from 7.02 ± 1.05 pre-op to 2.20 ± 1.50 post-op). AKSS also increased significantly from 45.25 ± 13.05 pre-op to 70.08 ± 22.05 post-op. This study confirms the efficacy & safety of PFO in the management of medial joint OA. The procedure is cost-effective, simple, faster recovery & allow full wt bearing from the next day of surgery. Limitations of our study were small sample size, absence of control group to compare the results & shorter follow-up period. Short-term results of PFO are excellent, but these outcomes will remain unchanged in longer follow-up, is not known. Hence, a longer follow-up study is essential.

CONCLUSION

PFO is a novel procedure for the management of medial joint OA knee which is simple, safe, cost-effective, with early recovery & lesser complications. It decreases knee pain significantly and improves the joint function & radiological appearance. PFO may be a suitable surgical option for many developing countries which have financial & medical delivery constraint. PFO may delay or even negate the need of TKR but a longer

follow-up period is required to evaluate whether its beneficial effects will persist in long term.

REFERENCES

1. Guoping Zou, Weibin Lan, Yuanyuan Zeng, Jianhong Xie, Shuanglong Chen, Yongrong Qiu. Early clinical effect of proximal fibular osteotomy on knee osteoarthritis. *Biomedical Research* 2017; 28 (21): 9291-9294.
2. Ringdahl E, Pandit S. Treatment of knee osteoarthritis. *Am Fam Physician*. 2011; 83:1287-92.
3. Kon E, Filardo G, Drobnic M, Madry H, Jelic M, Dijk N et al. Non-surgical management of early knee osteoarthritis. *Knee Surg Sports Traumatol Arthrosc*. 2012; 20:436-9.
4. Page CJ, Hinman RS, Bennell KL. Physiotherapy management of knee osteoarthritis. *Int J Rheum Dis*. 2011; 14:145-51.
5. Dr. Yeshwanth Subash, Dr. Gunalan K Naidu. The role of proximal fibular osteotomy in the management of medial compartment osteoarthritis of the knee. *International Journal of Orthopaedics Sciences* 2018; 4(3): 369-372
6. Fujisawa Y, Masuhara K, Shiomi S. The effect of high tibial osteotomy on osteoarthritis of the knee. An arthroscopic study of 54 knee joints. *Orthopedic Clinics of North America*, 1979; 10(3):585-608
7. Jackson JP. Osteotomy for osteoarthritis of the knee. *Proceedings of the Sheffield Regional Orthopaedic Club. The Journal of Bone and Joint Surgery*. 1958; 40(4):826.
8. Sprenger TR and Doerzbacher JF. Tibial osteotomy for the treatment of varus gonarthrosis. Survival and failure analysis to twenty-two years. *J Bone Joint Surg Am* 2003; 85-A: 469-474.
9. W-Dahl A, Robertsson O and Lidgren V. Surgery for knee osteoarthritis in younger patients. *Acta Orthop* 2010; 81: 161-164.
10. Yang S, Hadlow S. Unicompartmental knee arthroplasty: is it durable? *N Z Med J*. 2003; 116(1183):627.
11. Aleto TJ, Berend ME, Ritter MA, Faris PM, Meneghini RM. Early failure of unicompartmental knee arthroplasty leading to revision. *J Arthroplasty*, 2008, 159-63.
12. Yang ZY, Chen W, Li CX, et al. Medial compartment decompression by fibular osteotomy to treat medial compartment knee osteoarthritis: a pilot study. *Orthopedics* 2015; 38: e1110- e1114.
13. Xiaohu Wang, Lei Wei, Zhi Lv, Bin Zhao ,Zhiqing Duan, Wenjin Wu et al. Proximal fibular osteotomy: a new surgery for pain relief and improvement of joint function in patients with knee osteoarthritis. *Journal of International Medical Research* 2017, Vol. 45(1) 282-289.

How to cite this article: Agrawal NK, Vaishya SS. Proximal Fibular Osteotomy: A Novel Technique for Management of Medial Compartment Knee Osteoarthritis. *Ann. Int. Med. Den. Res.* 2019; 5(1):OR01-OR03.

Source of Support: Nil, **Conflict of Interest:** None declared