

A Case of True Hermaphroditism, 46, XY DSD.

Henna Naqash¹, Mohammad Hayat Bhat², Mushtaq Ahmad Mir³, Majid Jehangir⁴

¹Senior Resident, Department Of General Medicine, GMC, Srinagar, India.

²Lecturer, Department of General Medicine, GMC, Srinagar, India.

³Consultant , Department of Plastic Surgery, GMC, Srinagar, India.

⁴Consultant, Department of Radiodiagnosis, GMC, Srinagar, India.

Received: October 2018

Accepted: November 2018

Copyright: © the author(s), publisher. It is an open-access article distributed under the terms of the Creative Commons Attribution Non-Commercial License, which permits unrestricted non-commercial use, distribution, and reproduction in any medium, provided the original work is properly cited.

ABSTRACT

A 26 year old student reared as a female, presented with inability to menstruate and increased facial hair growth. On examination , patient had hyperandrogenic features including hirsutism, low pitched voice, microphallus with hypospadias. Investigations revealed a 46 XY karyotype with increased testosterone and imaging revealed both ovaries and testes with a hypoplastic uterus. The patient was managed with bilateral testicular gonadectomy, feminising genitoplasty and hormonal therapy.

Keywords: Hermaphrodite , Hirsutism , Microphallus , Follicular, Zygote.

INTRODUCTION

True hermaphroditism is a condition where an individual is born with both ovarian and testicular tissues. Such persons usually present with ambiguous genitalia. We are presenting a similar case of a 26 year old person who is labelled as a female.

CASE REPORT

26 year old student, reared as a female, unmarried, presented to us with complaints of inability to ever menstruate and increased facial hair growth [Figure 1 and Figure 9]. Reason for delayed seeking of medical consultation was the inability to disclose the fact due to shyness. There was a growth spurt at about 14 years of age, not associated with any breast development but with increased hair growth over upper lips, chin, face besides both armpits, perineal region and thighs. She needed shaving her face twice weekly. She had a slight change in voice at about the same age as it became low pitched. There has been no change in the size or features of external genitals as per the patient and her mother. Menarche was not achieved. Gender identity by the patient for self was female. Patient had never had menstrual cycles. There was no history suggestive of any periodic abdominal pain or any stressors at home. There was

sucked normally at birth. Thereafter, she achieved all milestones at proper age. no history of any hot flashes, discharge from nipples or any bone pains or fractures. Scholastic performance was good. She was literate upto class 8th, left school because of some domestic issues. She did not have any learning difficulties. Patient was 3rd in birth order with normal sibs, born as full term normal delivery at home, assigned female sex of rearing at birth, with average weight with no adverse perinatal history given, no features suggestive of hyperandrogenism in mother during any part of pregnancy. There was no need of any assisted reproduction in mother. She was not exposed to any medications including androgens. The patient was assigned female sex at birth by a midwife as she was born at home, she

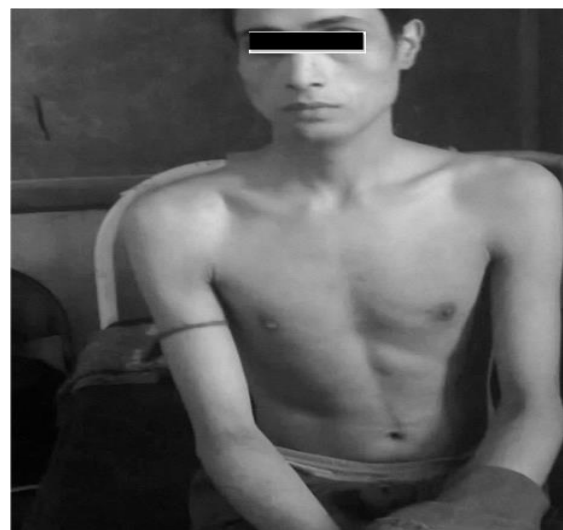

Figure 1: Patient.

Name & Address of Corresponding Author

Dr. Henna Naqash
Senior Resident,
Department Of General Medicine,
GMC, Srinagar, India.

cried and Gender role expressed by the patient as per aggression, peer and group interactions and behaviour (dressing, grooming) had been female all through. Her toy preferences in childhood had been feminine. Sexual orientation described by the patient as per behaviour, fantasies and attractions was heterosexual towards male. There was no history suggestive of any gender dissatisfaction or promiscuity.

There was no history of any addictions, and she took diet same as other family members with rice as staple diet. There were no food fads or allergy to any diet.

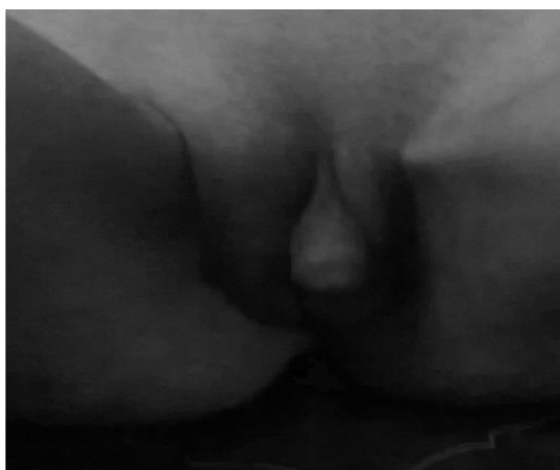


Figure 2: External genitals of the patient.

There was no history suggestive of hypertension or diabetes, fractures, hearing impairment. Bowel and bladder habits were normal, she was nonsmoker with no addictions. Family history was insignificant. There was no history suggestive of any DSD (disordered sexual development), adrenal disorders or infertility in family members or near relatives.

Examination revealed conscious, hemodynamically stable patient with no facial dysmorphism, no midline defects, no altered pigmentation. There were many hyperandrogenic features, she had a low pitched voice. She had a muscular build, had facial acne and a normal anterior hairline with no recession, no temporal balding. There were no typical female body contours. Hirsutism was present with a Ferriman Galleway hirsutism score 25. Wt 45 kg, Ht 161cm, BMI 17.36, Arm span 164 cm. Neck length 13.5 cm, Neck body ratio was 0.083(normal), Waist -hip ratio 0.82, upper segment: lower segment=1.20. All digits of hands and feet were normal. There was no edema, no webbing of neck or nuchal folds, no thyromegaly. No kyphosis or scoliosis, nails were normal, no nevi, acanthosis nigricans or skin tags. Normal carrying angle at elbow. ENT examination was normal. Examination of chest/ cardiovascular system /abdomen/ nervous system was normal. No hernia felt, gonads not palpable. Genital examination [Figure 2] revealed a hypoplastic penis (microphallus) with length of 4.1

cm and width of 1.9 cm, with hypospadias with urethral meatus 0.8 cm from the tip, with normal labia majora and a blind vagina. Prader stage scoring of external genitalia was IV. She had a female escutcheon. Per rectal examination was normal with no palpable prostate. SMR Tanner score B-1,P-4= 5, no galactorrhoea. I.Q. was normal for her age.

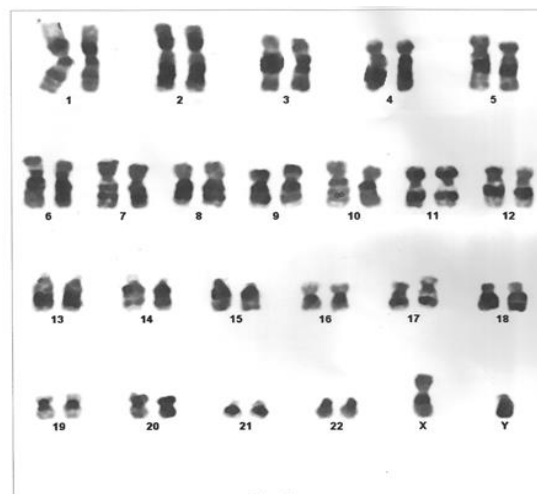


Figure 3: Karyotype of patient.

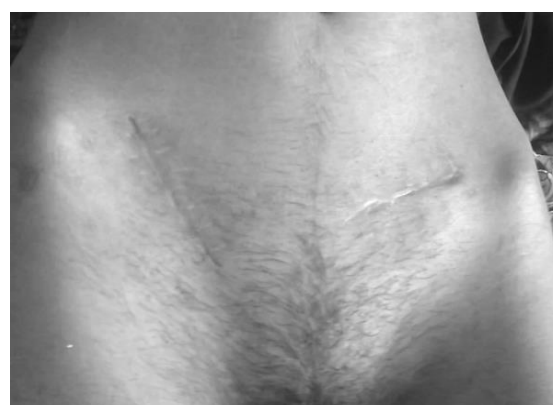

Figure 4: After excision of bilateral inguinal hernia.

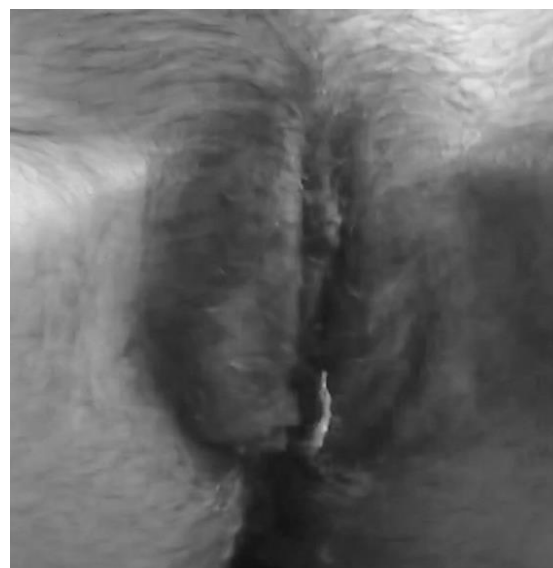

Figure 5: After perineoplasty.

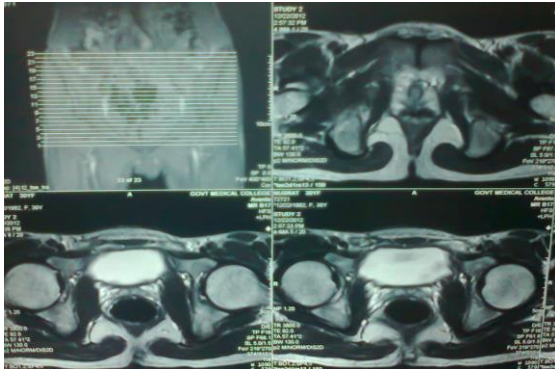

Figure 6: MRI Pelvis.

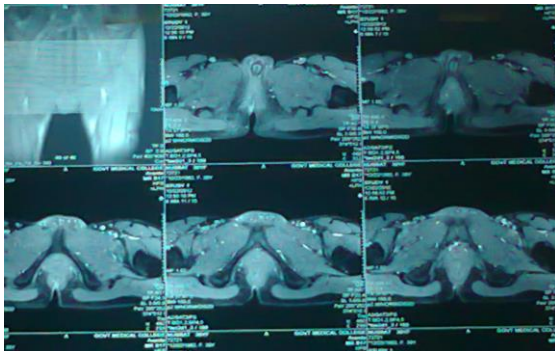


Figure 7: MRI Pelvis.

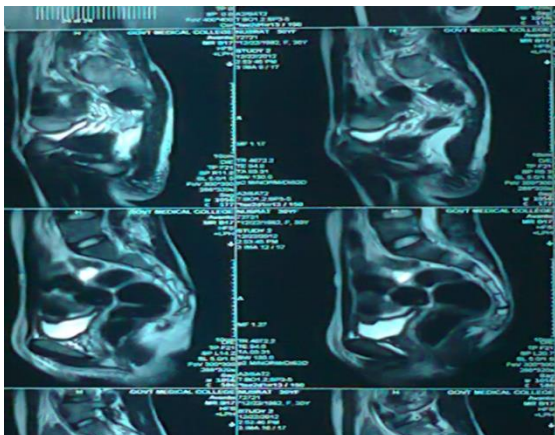


Figure 8: MRI Pelvis.

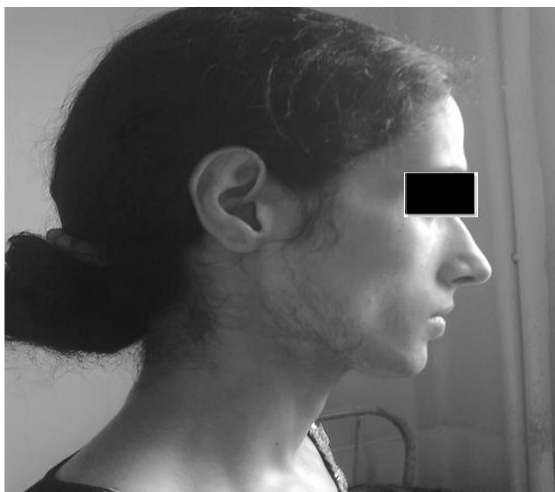

Figure 9: Patient.

Differentials made after this history and examination were as follows:

1. Mixed gonadal dysgenesis.
2. 46XY DSD with partial gonadal dysgenesis.
3. Congenital adrenal hyperplasia due to 21 hydroxylase deficiency.
4. Persistent Mullerian duct syndrome.
5. Aromatase deficiency
6. True hermaphrodite

The extent of virilisation in this patient indicates that exposure to androgens has occurred during initial pregnancy and we suspected an in utero abnormal sexual differentiation. We evaluated her as a case of primary amenorrhoea with virilisation or androgen excess.

Patient was investigated revealing normal hemogram, kidney and liver function tests, normal urine examination and electrolytes (no hypokalemia), electrocardiogram and chest X ray. Blood gas analysis was normal with no evidence of acidosis or alkalosis.

Hormonal profile FSH: 26.47mIU/mL (normal 2.5-10.2 in follicular phase and 3.5-33.4 in midcycle)

LH: 50.36mIU/mL (normal 1-18 follicular, 20-105 mid cycle)

Serum Testosterone: 1.58 ng/mL (normal range in females 0.02-0.48 ng/mL)

17OH Progesterone: 1.08ng/ml (normally 0.20-1.30 in follicular phase)

Estradiol: 48.06 pg/ml (normal 4-60 pg/ml)

Karyotype [Figure 3]: 46 XY done at 450-550 band resolution using GTG banding technique [Trypsin and Geimsa].

USG pelvis: Normal urinary bladder. A rudimentary hypoplastic uterus seen. Both ovaries are normal and bilateral inguinal testes seen. Upper abdominal structures normal.

MRI pelvis [Figures 6,7,8]: Hypoplastic uterus. Both ovaries were normal and bilateral inguinal testes seen.

HPE of gonadal biopsy: Both gonads were ovotestes.

Left gonad: Predominantly testicular elements with seminiferous tubules containing sertoli cells but no spermatozoa. Interstitial fibrosis seen. Areas of ovarian differentiation including follicles, oocysts and ovarian stroma were present. Stroma arranged in whorls.

Right gonad: Predominantly ovarian differentiation with some seminiferous tubules.

Final Diagnosis: 46 XY Disordered sex development or True Hermaphrodite.

Management: The family and the affected individual were fully engaged in decision making. After a joint discussion with a multidisciplinary team, parents as well as the patient wanted to continue as a female. So, with their consent, patient was advised excision of both testis with their biopsy and histopathology. An urologist performed bilateral inguinal gonadectomy [Figure 4]. Plastic surgeon

performed a feminising genital surgery including clitoroplasty and vaginoplasty using graft from the thigh [Figure 5]. Repeated dilatation of vagina was done. She was put on increasing doses of ethinyl estradiol, starting with 0.1 mg. After about 6-8 months, she started cyclic estrogens and progesterone as Tab. Novelon (Ethinylestradiol 0.03 mg + Desogestrel 0.15 mg). She has started with cyclic menstrual bleeding. She has undergone Laser epilation treatment for her hirsutism and bilateral silicon breast implantation was also done. Patient is now on regular follow up of a urologist, gynaecologist, psychologist, endocrinologist and dermatologist and is doing well.

DISCUSSION & CONCLUSION

Ovotesticular DSD is an uncommon condition that has been reported in approximately 500 individuals worldwide. Ambiguity of the external genitalia sufficient to prevent immediate sex assignment at birth is rare, but it is estimated that abnormalities of the external genitalia that need formal investigation occur in 1 of every 4000 births.^[1] In the process of sex differentiation in the male, Mullerian structures regress and Wolffian structures are stabilised; whereas in the female, at the time of puberty, estrogen synthesis stimulates breast and uterine development and follicular development results in regular menstrual cycles. Sex development has three components namely a. chromosomal sex (karyotype), b. Gonadal sex (presence of testis or ovary), c. phenotypic sex (appearance of external genitalia and internal structures). One additional component is the brain sex (psychosexual development). The primitive gonad remains bipotential until about 42 days post conception.

A majority of true hermaphrodite patients present with genital ambiguity with or without palpable gonads and most of them are reared as males.^[2,3] True Hermaphrodite [TH] is a medical term for an intersex condition in which an individual is born with ovarian and testicular tissue. External genitals are often ambiguous, the degree depending mainly on the amount of testosterone produced by testicular tissue between 8-16 weeks of gestation. It can be caused by 1. Division of one ovum, followed by fertilization of each and fusion of two zygotes; 2. one ovum fertilized by two sperms followed by trisomic rescue; 3. two ova fertilized by two sperms fuse to form chimera. One male and one female zygote fuse to result in a hermaphrodite individual. It is associated with mutation in SRY gene.^[4] True hermaphrodite or ovotesticular disorder of sexual differentiation is one of the rarest variety of disorders of sexual differentiation (DSD) and represents only 4-10% cases of all. Incidence of DSD is 1:4500-1:5000 live births. In about 90 % cases, patient has 46 XX karyotype and present as undervirilised males.^[5] Rarely 46XY/46XX

mosaicism may occur. There have been reports of 46XY karyotype also.^[6] In a study by Bhansali et al from a tertiary care centre in India, only one case of 46XY ovotesticular DSD was detected among 7 TH patients over 10 years.^[3]

The commonest presentation is an abnormal external genitalia, ranging from normal male to normal female, with or without palpable gonads; i.e., genital ambiguity with mild clitoromegaly, chordee, hypospadias and cryptorchidism may be noted. This can be explained by the differential sensitivity of pilosebaceous units to androgens in different patients.^[7] Other symptoms are hematuria, amenorrhea, lower abdominal pain and inguinal hernia.^[8] Features of hyperandrogenism are present in those reared as females. Progressive androgenisation can occur in girls with significant testicular tissue, which can result in voice changes and clitoral enlargement during adolescence if left untreated. Individuals raised as male may present with hypospadias and undescended testis, experience significant estrogenization at puberty and may have cyclic hematuria if a uterus is present.

On the basis of location of gonads and histology, Hinman's classification is as follows.^[9]

- a. Lateral..testis and contralateral ovary(20%);
- b. Bilateral..testis and ovarian tissue identified on both sides, usually as ovotestis (30%);
- c. Unilateral.. ovotestis on one side and testis or ovary on other side(50%). True hermaphrodite is rarely associated with gonadal tumours, few cases of malignancy like dysgerminomas and gonadoblastoma have been seen. Histologic variety of ovotestis is at risk of malignancy.

It is important to retain at least the ovarian tissue in case of true hermaphrodite patients with uterus as few cases with successful pregnancies are there in the literature.^[10] True hermaphrodite should be kept as one of the differential diagnosis of primary amenorrhea particularly in presence of hyperandrogenism. Presence of inguinal hernia associated with abnormality of external genitalia should stimulate the physician to make an accurate diagnosis. Not all patients develop cutaneous manifestations of androgen excess, e.g., hirsutism because of different sensitivity to androgens. Detailed physical examination and stepwise investigations including karyotyping will pick up these cases. Various factors include the possible diagnosis (gonadal dysgenesis versus true hermaphrodite), presence of Y chromosome, sex of rearing and the scope of fertility should be taken into consideration before doing gonadectomy.^[11]

A 46 XX woman with TH is reported who had an RSPO1 (R spondin 1) homozygous mutation; its pivotal role in sex determination has been recently determined.^[12]

These patients present themselves for diagnosis and for assistance in living as a more normal member of

the desired sex. Usually it is the presence of abnormal genitalia or development of secondary sex characteristics at variance with the assumed sex that brings the patient to the physician. A uterus is present in most cases and menstruation may occur. No close relation can be made between relative amounts of ovarian and testicular tissue, and development of secondary characters and the psyche. In our case, with the assumption that the patient was reared as a female, plans were made to maintain and improve female characteristics and suppress masculine characteristics. Psychologically she seemed to make a much better adjustment in her relation with her friends.

Correct diagnosis is with medical and surgical means. Disposition of undesired gonadal tissue; plastic procedures; hormone treatment; constructing a vagina; exogenous estrogen for feminisation are important considerations. Cooperation of endocrinologist, surgeon and urologist. The term TH is used to indicate that the person is bisexual in both the gonadal and secondary sex structures. A TH in the classic sense should be able to fertilise a female, be fertilised by a male, and fertilise itself, but no such instance is authoritatively reported in the literature. The word hermaphrodite comes from the myth of Hermaphroditus; a son of Hermes and Aphrodite, Greek gods.^[13]

Karyotyping reveals 60% 46 XX, 10% 46XY, remainder various forms of mosaicism XX/YY. In the TH with 46XY karyotype, the test element is usually dysgenetic and hence the risk of malignancy is 28% by the age of 20 years. According to Alonso et al., TSPY gene (testis specific protein, Y encoded) localised within the GBY locus (gonadoblastoma locus in Y chromosome) participates in the multistep malignant transformation.^[14] Gonadal differentiation occurs at 6-8 weeks gestation. TDF gene (Y chromosome) stimulates gonads towards testicular differentiation. Absence of TDF—gonads differentiate into ovaries. Intersex is a challenging and complicated situation, but when understood, can often be dealt with effectively.

Clitoral reduction, perineoplasty and follow up widening of vagina with vaginal dilators is needed. Removal of all contradictory gonadal tissue and appropriate hormonal substitution should be performed to allow gender specific development. Undescended and dysmorphic testicular tissue should be removed because of increased risk of malignant gonadal tumours.

TH with normal male external genitalia is a rare presentation.^[15] Long arm of Y has not been detected in TH. Testicular histology in TH is characterised by spermatogenic arrest, causing us to speculate that long arm of Y might be essential for germ cell maturation beyond the spermatogenic stage.^[16]

Although rare, TH should be suspected in male patients presenting with bilateral breast enlargement in adolescence.^[17]

REFERENCES

1. Sax L. How common is intersex? A response to Anne Fausto-Sterling. *J Sex Res.* 2002;39:174-178.
2. Damiani D, Fellous M, McElreavey K, Barbaux S, Barreto ES, Dichtchekekenian V, et al. True hermaphroditism: Clinical aspects and molecular studies in 16 cases. *Eur J Endocrinol.* 1997;136:201-4.
3. Bhansali A, Walia R, Singh R, Sriram M, Rao KL, Dhaliwal L, et al. Disorders of sex development. A study of 95 patients. *Endocrinologist* 2009;19:98-101.
4. Braun A, Kammerer S, Cleve H, Lohrs U, Schwarz HP, Kuhnle U. True Hermaphroditism in a 46 XY individual, caused by postzygotic somatic point mutation in the male gonadal sex determining locus (SRY): molecular genetics and histological findings in a sporadic case. *Am J Hum Genet* 52(3):578-85.
5. Hamerton JL, Canning N, Ray M, Smith S. A cytogenetic survey of 14,069 newborn infants : Incidence of chromosomal abnormalities. *Clin Genet* 1975;8:223-43.
6. Krob G, Braun A, Kuhnle U. True Hermaphrodite: geographic distribution, clinical findings, chromosomes and gonadal histology. *Eur J Pediatr.* 1994;153:2-7.
7. Rosenfield RL. Clinical Practice: Hirsutism. *N Engl J Med* 2005;353:2578-88.
8. M Zafar Iqbal, Mazhar Rafee Jam, M Saleem, Mushtaq Ahmad. True Hermaphrodite: A Case Report. *APSJ J Case Rep.* 2011 May-Aug; 2(2):16.
9. Hinman F: The Principles and Practice of Urology , Philadelphia , W.B. Saunders Company , 1935.
10. John I Brewer, Harold O Jones, Harry Culver. True Hermaphroditism. *The Journal of American Medical Association.* Feb 9, 1952. Vol 148, No. 6.
11. Lal Bahadur Palo, Mary Daniel, Alaganandam Padma, Jaya Prakash Sahoo. True Hermaphrodite presenting as primary amenorrhoea. *Indian Journal of Endocrinology and Metabolism.* 2012 Vol 16. Issue 4. Pages 640-642.
12. Tomaselli S, Megiorni F, De Bernardo C, Felici A, Grommatico P. Syndromic true hermaphrodite due to an R-Spondin 1 (RSO1) homozygous mutation. *Hum Mutat* 2008 Feb; 29 (2):220-6.
13. MacLaughlin DT, Donhoae PK. Sex determination and differentiation. *N Engl J Med.* 2004; 350: 367- 78.
14. Usha Kini, G Bantwal, V Ayyar, Jyothi Idiculla. Bilateral Gonadoblastomas with a left sided Dysgerminoma in a true hermaphrodite (Disorder of sexual differentiation) with 46,XY karyotype. *JAPI.* Vol 56. July 2008.
15. M Montero, R Mendez, D Valverde, JL Fernandez, M Gomez, C Ruiz. True hermaphrodite and normal male external genitalia : a rare presentation. *Alta Paediatrica* 09/1999;88(8): 909-11.
16. P K Donahoe, J D Crawford, W H Hendren. True hermaphrodite. A clinical description and a proposed function for the long arm of Y chromosome. *Journal of Paediatric Surgery* 1978 Jun; 13 (3): 293-301.
17. Sophia Onhilal, Jack Turco, Ajay Nangia, Mitchell Scotland, Paul D Manganiello. True hermaphrodite presenting as bilateral gynaecomastia in an adolescent phenotypic male. *Fertility and Sterility.* Vol 83, Issue 4, pages 1041e11-1041e13, Apr 2005.

How to cite this article: Naqash H, Bhat MH, Mir MA, Jehangir M. A Case of True Hermaphroditism, 46, XY DSD. *Ann. Int. Med. Den. Res.* 2019; 5(1):ME01-ME05.

Source of Support: Nil, **Conflict of Interest:** None declared