

# Third Molar in the Line of Mandibular Angle Fracture; its Prognosis and Effect on Healing

Aftab Ahmed Kumbhar<sup>1</sup>, Kashif Ali Channar<sup>2</sup>, Tarique Hussain Shaikh<sup>1</sup>, Attiya Nayab<sup>3</sup>, Ishrat Begum<sup>4</sup>, Hafsa Maqbool<sup>3</sup>, Salman Shams<sup>5</sup>

<sup>1</sup>FCPS Resident, Department of Oral and Maxillofacial Surgery, Faculty of Dentistry, Liaquat University of Medical and Health Sciences, Pakistan

<sup>2</sup>Associate Professor, Department of Oral and Maxillofacial Surgery, Faculty of Dentistry, Liaquat University of Medical and Health Sciences, Pakistan

<sup>3</sup>Resident, Department of Oral and Maxillofacial Surgery, Faculty of Dentistry, Liaquat University of Medical and Health Sciences, Pakistan

<sup>4</sup>Dental Surgeon, Department of Oral and Maxillofacial Surgery, Liaquat University Hospital Hyderabad, Pakistan

<sup>5</sup>Senior Lecturer, Department of Oral and Maxillofacial Surgery, Faculty of Dentistry, Liaquat University of Medical and Health Sciences, Pakistan

Received: November 2020

Accepted: November 2020

## ABSTRACT

**Background:** Mandible due to its relatively prominent position is more prone for fractures and accounts for most common facial bone injuries. In mandible, mandibular angle is the common site for fractures. These fractures have been subject of special interest because of their close or direct relationship with the lower molar teeth. The objective of this study is to determine the frequency of postoperative complications by removing and retaining the third molar tooth in the line of mandibular angle fracture. **Methods:** This is an analytical randomized control trial conducted at Oral and Maxillofacial Surgery Department of Liaquat University of Medical & Health Sciences, Jamshoro/Hyderabad, Pakistan from January 2019 to December 2019. A total of 100 clinically and radiographically confirmed mandibular angle fractures involving third molar in the line of fracture were randomly allocated into group A and group B by extracting and retaining respectively. The complications were assessed on follow up including infection and nonunion on the basis of clinical and radiographic examination. All data was recorded in pre-designed proforma. **Results:** The average age of the patients in group A was 35.6±12.13 years and in group B was 37.62±10.12 years. Rate of infection was high in group A as compare to group B at different time point but rate of non-union was very low. **Conclusion:** There was a statistically significant difference in postoperative complications between the extraction and non-extraction groups of third molars in the fracture line. If the third molar is partially impacted or completely nonfunctional, likely to be involved in pathologic conditions later in life, or possible to remove it with the plate simultaneously, extraction of the third molar in the fracture line should be considered during ORIF surgery of the mandible angle fracture.

**Keywords:** Third molar tooth, Mandibular angle fracture, Extraction, Retention

## INTRODUCTION

In mandible, mandibular angle is the common site for fractures. These fractures have been subject of special interest because of their close or direct relationship with the lower molar teeth.<sup>[1,2]</sup> The presence of impacted wisdom tooth often diminishes bone quantity and stability in this region. Additionally, the bony structure of this section of the mandible when compared with the dentate part and biomechanical reasons contribute to the fact that the mandibular angle is the site of predilection for fractures.<sup>[3]</sup> Fracture of the angle carry highest rate of complications of all fractures of lower jaw.<sup>[4]</sup> Incidence of mandibular angle fracture is about 27 to 30%.<sup>[5]</sup> Tooth which is involved in fracture line may become devitalized

due to injury or presence of pre-existing pulpal or periodontal pathology. These factors may become the cause of infection and interfere healing.<sup>[6]</sup> Treatment of angle fracture is complicated by presence of third molar in the line of fracture. Damage to tooth involved in the fracture line may include exposure of root surface, subluxation, avulsion, root fracture, and varied pathology all of which may interfere or complicate healing.<sup>[7]</sup> Shetty and Freymiller suggest some guidelines regarding the procedure to be followed when teeth are present in the line of fracture; healthy teeth in the line of fracture should be kept when they do not show great mobility or evidence of pathological alterations; impacted molars should be kept to provide a wider repositioning surface, except when associated with cyst or pericoronitis; teeth that prevent fracture reduction should be removed; teeth with coronal fracture should be kept provided emergency endodontic therapy is applied; tooth apices with exposed roots or when the line of fracture follows a root surface should be removed.<sup>[8]</sup> Although the tooth can be kept in the fracture line if its role in stabilizing the bone fragments exceed the possibility of development

### Name & Address of Corresponding Author

Dr Salman Shams  
Senior Lecturer,  
Department of Oral and Maxillofacial Surgery  
Liaquat University of Medical & Health Sciences.  
Jamshoro, Sindh, Pakistan  
Salman\_Omfs@Hotmail.Com

inflammatory complications.<sup>[9]</sup> Divergent opinions exist regarding the extraction or preservation of such teeth. The management of teeth positioned in line of fracture in recent years is more conservative.<sup>[5]</sup>

Nowadays, antibiotics are given peri-operatively and miniplates are used instead of wire sutures. According to Champey's technique, angle fractures are frequently treated by single plate placed over superior border of mandible. For this reason, maintaining the third molar may be beneficial for fracture reduction and fixation because extensive osteotomy necessary for tooth removal can be avoided, particularly for judging the remaining fracture line and attaching the osteosynthesis plate in adequate position.<sup>[10]</sup> Each case must be treated independently, and the dental professional should make sure that the tooth extraction is made on the basis of each individual clinical situation.<sup>[8]</sup>

In the light of facts that incidence of postoperative complications in the previous studies showing variability in outcomes following extraction of tooth in the fracture line i.e 11.1%,<sup>[3]</sup> and 30%,<sup>[11]</sup> while another study shows infection rate of 38.5% in extraction group and 0% in non-extraction group and nonunion being 0% in both groups.<sup>[12]</sup> Hence this study will help us in determining the choice whether to extract or not to extract the tooth in the line of mandibular angle fracture.

## MATERIALS AND METHODS

This is an analytical randomized control trial with Non Probability Consecutive sampling conducted at Oral and Maxillofacial Surgery Department of Liaquat University of Medical & Health Sciences, Jamshoro/Hyderabad, Pakistan from January 2019 to December 2019.

### Sample selection:

#### Inclusion Criteria:

- All clinically and radiographically confirmed mandibular angle fractures involving third molar in the line of fracture.
- Patients report within 72 hours of injury.
- Age range from 18 to 60 years.
- Male and Female

#### Exclusion Criteria:

- Patient not willing to participate in this study.
- Patients having any systemic illness (Hypertension, diabetes mellitus, Chronic obstructive pulmonary disorder, Renal failure, liver cirrhosis etc) which hampers the G.A fitness or surgical intervention or healing process.
- Patient lost to follow up.

#### Data collection procedure:

After getting approval from College of Physicians and Surgeons Pakistan, patients who met inclusion

criteria were included in the study. Informed written consent was taken for participation and for surgical intervention. Diagnosis of the patient was made upon clinical and radiographic basis which includes Panoramic, PA (anterioposterior view) and Computed tomography. Pre-operative assessment included status of occlusion (seen clinically), step defect (palpated clinically), degree of displacement of fracture (on radiograph), and status of third molar (on radiograph) by maxillofacial consultant with 7 years of experience. Patients were divided into two groups (Group A and Group B) by extracting and retaining the third molar through random number table. All patients were treated under general anesthesia with open reduction and internal fixation (by consultants having 7 years of experience) with non-compressive miniplates (2mm, 5 or 6 holes) via intraoral approach. Maxillomandibular fixation was used only intra-operatively to help in achieve occlusion. Antibiotics were administered parentally for 5 days. The complications were assessed on follow up includes infection and nonunion on the basis of clinical and radiographic examination. All data was recorded in pre-designed proforma preoperatively and two weeks, one month and three months post-operatively.

#### Data analysis procedure:

The data was analyzed using SPSS version 20.0. The categorical variables like gender, cause of fracture, postoperative complications such as infection and nonunion was presented as frequency and percentages. Postoperative complications were compared by using Chi-square test. Mean and standard deviation was calculated for quantitative variables like age in years at presentation.

## RESULTS

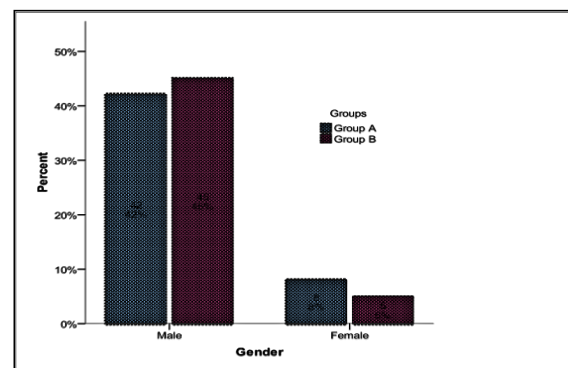


Figure 1: Gender Distribution with Respect to Groups n=100

A total of 100 clinically and radiographically confirmed mandibular angle fractures involving third molar in the line of fracture were randomly allocated into group A and group B by extracting and retaining respectively. Age distribution of the

patients with respect to groups is shown in Table 1. The average age of the patients in group A was 35.6±12.13 years and in group was 37.62±10.12 years. There were 87% male and 13% female. Gender distribution is shown in [Figure 1]. Most of the causes of injury was RTA as shown in [Figure 2].

Comparison of postoperative complication between groups with respect to follow-up is shown in table 2. Rate of infection was high in group A as compare to group B but significant difference was observed at one month's [14% vs. 2%; p=0.027] and three months [20% vs. 4%; p=0.014]. Rate of non-union was also high in group A than group B but no statistically significant was seen.

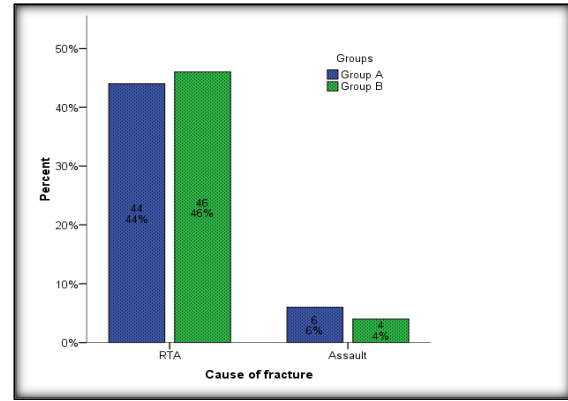


Figure 2: Cause of Fracture with Respect to Groups n=100

Table 1: Descriptive Statistics of Age with Respect To Groups

Statistics	Group A n=50	Group B n=50
Mean	35.60	37.62
Std. Deviation	12.13	10.12
95% Confidence Interval for Mean	Lower Bound	32.15
	Upper Bound	39.05
Median	34.00	36.00
Inter quartile Range	21	13

Group A= Extraction Group  
Group B= Retention Group

Table 2: Comparison of Postoperative Complication Between Groups with Respect to Follow-Up

Complication	Group A n=50	Group B n=50	P-Value
<b>Infection</b>			
At two weeks	3(6%)	1(2%)	0.307
At One Months	7(14%)	1(2%)	0.027
At Three Months	10(20%)	2(4%)	0.014
<b>Non-Union</b>			
At two weeks	3(6%)	1(2%)	0.307
At One Months	1(2%)	0(0%)	0.315
At Three Months	1(2%)	0(0%)	0.315

## DISCUSSION

Approximately 50% of fractures of the mandible occur in teeth bearing area and whether teeth situated in the line of fracture should be extracted or retained has always been a subject of heated debate.<sup>[13]</sup> Treating a mandibular fracture with a tooth in fracture line, a number of factors play a role in the development of complications. Those mentioned are retention or extraction of the tooth, closed or open reduction time from trauma to treatment, mobility after fixation and antibiotic treatment.<sup>[14]</sup>

Consistent extraction of teeth in the line of mandibular fracture has no scientific basis and has distinct disadvantages. Extraction of tooth entails further trauma to bone tissue and also presents technical difficulties when the fragments are highly mobile. Extraction of the tooth also increases the risk of the contamination of the fracture through the empty alveolus, which may sometimes be difficult to suture.<sup>[15,16]</sup> Subsequent prosthodontic treatment may also pose problems. A normal coagulum may not always form, occasionally leading to localized alveolar osteitis of the extraction site. The presence

of tooth constitutes an occlusal reference and provides a posterior stop.<sup>[15]</sup> In a recent experimental study, the pressure of tooth at the fracture site was found not to impede bone healing and had a stabilizing effect on the fractures.<sup>[17]</sup>

In present study there were 87% male and 13% female. Patel et al. <sup>[17]</sup> showed that the overwhelming majority of patients were men, comprising 85 of 103 patients (82.5%), whereas women accounted for 18 of 103 patients (17.5%) with mandibular angle fracture. Most fractures occurred at the left mandibular angle (34.9%), followed by the right side (34.9%) and both sides (5.8%).

In present study rate of infection was high in group A as compare to group B but significant difference was observed at one month's [14% vs. 2%; p=0.027] and three months [20% vs. 4%; p=0.014]. Rate of non-union was very low and no statistically significant difference was seen. Similar result was also reported in another study shows infection rate of 38.5% in extraction group and 0% in non-extraction group and nonunion being 0% in both groups.<sup>[12]</sup>

Management of the third molars in fracture lines has been controversial. Yadavalli et al.<sup>[18]</sup> proposed that the presence of third molars in fracture lines may be of great value in the repositioning of fractures because the presence of third molars prevents further injury to the bone tissue. The extraction of third molars makes it difficult to reduce the contact between fracture segments when the fragments are highly mobile. Because extraction of the tooth increases the risk of contamination through the empty alveolus,<sup>[18,19]</sup> Yadavalli et al.<sup>[18]</sup> used the following criteria for surgical removal of the third molars in the line of fracture: pericoronal or periodontal infection, cross caries, extensive periapical lesions, mobility, or exposure of the apical half or more of the root fracture.

McNamara et al.<sup>[20]</sup> noted that the risks involved with extraction of third molars includes loss of bone, greater difficulty in reduction and plating, increased surgical time, and increased risk to the inferior alveolar nerve. In their study, the incidence of nerve injury was 16% for the retention group compared to 39% for the removal group. Therefore, they stated that the removal of third molars creates an additional risk of nerve injury and increases operating time.<sup>[21]</sup>

The issue of postoperative infection has long been debated and represents a common complication of mandible angle fracture.<sup>[22]</sup> A 1994 study by Ellis and Walker,<sup>[23]</sup> found that the extraction of third molars in fracture lines seemed to increase postoperative infection. In 2002, they proposed that the risk of postoperative infection increased if teeth were left in the fracture line.<sup>[22,23]</sup> Patel et al.<sup>[22]</sup> defined infection as purulent discharge from the intraoral incision through a sinus tract to the skin, or a closed area of swelling that required incision and drainage of purulent material. They found no statistically meaningful relationship between tooth management in the line of the fracture and rate of postoperative infection.<sup>[22]</sup> They stated that the differences in rates of infection might be attributed to inherent differences in the socioeconomic status of patients, tobacco and alcohol use and abuse, nutritional status, and other medical comorbidities.<sup>[22]</sup>

## CONCLUSION

There was a statistically significant difference in postoperative complications between the extraction and nonextraction groups of third molars in the fracture line. If the third molar is partially impacted or completely nonfunctional, likely to be involved in pathologic conditions later in life, or possible to remove it with the plate simultaneously, extraction of the third molar in the fracture line should be considered during ORIF surgery of the mandible angle fracture.

## REFERENCES

1. Kumar PP, Sridhar BS, PalleR, Singh N, SingamaneniVK , Rajesh P. Prognosis of teeth in the line of mandibular fractures. Pharm Bio Allied Sci J. 2014;6:97–100.
2. Ramakrishnan J, Shingleton A, Reeves D, Key MJ, Vural E, Little Rock AR, et al. The effects of molar tooth involvement in mandibular angle fractures treated with rigid fixation. Otolaryngol Head Neck Surg. 2009;140(6):845–48.
3. Patil PM. Lower third molar in the line of mandibular angle fractures treated with stable internal fixation: To remove or retain. J Oral Maxillofac Surg Med Pathol. 2012;25(2):115–18.
4. Zanakis S, Tasoulas J, Angelidis I, dendrinos C. Tooth in the line of angle fracture: The impact in the healing process. A retrospective study of 112 patients. J Craniomaxillofac Surg. 2015;43:113–16
5. RaiS, Pradhan R. Tooth in the line of fracture: its prognosis and its effects on healing. J Indian Dent Res. 2011;22(3):495–6.
6. Chrcanovic BR. Teeth in the line of mandibular fractures. J Oral Maxillofac Surg. 2014;18(1):7–24.
7. Samson J, John R, Jaya KS. Teeth in the Line of Fracture: To Retain or remove. J Craniomaxillofac Trauma & Reconstr. 2010;3(4):177–84.
8. Bobrowski AN, Sonog CL, Chagas Junior OL. Postoperative infection associated with mandibular angle fracture treatment in the presence of teeth on the fracture line: a systematic review and meta-analysis. Int J Oral Maxillofac Surg. 2013;42(9):1041–48.
9. Macan D, Brajdić D, Zajc I. The fate of teeth in mandibular fracture line. Rad 514 Medical Sciences, 38(2012) : 93–103
10. Ulbrich N, Ettl T, Waiss W, Gosau M, Moralis A, Reichert T. E, Mueller S. The influence of third molars in the line of mandibular angle fractures on wound and bone healing. J Clin Oral Invest. 2016;20(6):1297–302.
11. Chatha A A, Tahir S, Warraich R A, Hanif S, Riaz N, Khan S R, Akhtar U B. Frequency of infection after extraction of involved third molar in mandibular angle fractures treated with rigid fixation. Annals King Edward Med Uni. 2013;19(1):25–8
12. Lin HY, Jung TY, Park SJ. Evaluation of postoperative complications according to treatment of third molar in mandibular angle fracture. J Korean Assoc Oral Maxillofac Surg. 2017 feb;43–41
13. Marker P, Eckerdal A, Smith SC. Incompletely erupted third molars in the line of mandibular fracture. Oral Surg Oral Pathol 1994; 78:426–31.
14. Lizukat, Lindquist C, Hallaikanen D. Infection after rigidinternal fixation of mandibular fractures: a clinical and radiological study. J Oral Maxillofac Surg 1991; 49: 585–93.
15. Shetty V, Freymiller E. Teeth in the line of fracture: a Review. J Oral Maxillfac Surg 1989;47: 1303–06.
16. Foreitag V, Landau H. Healing of dentate or edentulousmandibular fractures treated with rigid or semi rigid fixationplate fixation: an experimental study in dogs. J Craniomaxillofac Surg. 1996; 24: 83–87.
17. Patel MF. Fixation Techniques and mandibular osteosynthesis in: Langdon JD, patel MF. Operative Maxillofacial surgery. 1st ed. London: Chapman & Hall; 1998: 331–45.
18. Yadavalli G, Mythily PH, Shetty JN. Clinical evaluation of mandibular angle fractures with teeth in fracture line, treated with stable internal fixation. Indian J Stomatol 2011;2:216–21.
19. Ellis E, Walker L. Treatment of mandibular angle fractures using two non-compression miniplates. J Oral Maxillofac Surg. 1994;52:1032–6.

20. McNamara Z, Findlay G, O'Rourke P, Batstone M. Removal versus retention of asymptomatic third molars in mandibular angle fractures: a randomized controlled trial. *Int J Oral Maxillofac Surg.* 2016;45:571-4.
21. Rajandram RK, Nabil S, Shareif MS, Ishak I, Marhazlinda J, Nordin R, et al. Mandibular third molar and angle of mandible fractures: an unsolved clinical dilemma. *Sains Malaysiana* 2013;42:39-43.
22. Patel N, Kim B, Zaid W. A detailed analysis of mandibular angle fractures: epidemiology, patterns, treatments, and outcomes. *J Oral Maxillofac Surg* 2016;74:1792-9.
23. Ellis E, Walker L. Treatment of mandibular angle fractures using two non compression miniplates. *J Oral Maxillofac Surg.* 1994;52:1032-6.

**Copyright:** © the author(s), 2020. It is an open-access article distributed under the terms of the Creative Commons Attribution License (CC BY 4.0), which permits authors to retain ownership of the copyright for their content, and allow anyone to download, reuse, reprint, modify, distribute and/or copy the content as long as the original authors and source are cited.

**How to cite this article:** Kumbhar AA, Channar KA, Shaikh TH, Nayab A, Begum I, Maqbool H, Shams S. Third Molar in the Line of Mandibular Angle Fracture; its Prognosis and Effect on Healing. *Ann. Int. Med. Den. Res.* 2021; 7(1):DE31-DE35.

**Source of Support:** Nil, **Conflict of Interest:** None declared