

Endocrowns- An innovative Post Endodontic Restoration

Disha Arora¹, Munish Goel², Vijay Kumar², Shweta Verma², Prabhat Mandhotra³, Mahender Singh⁴

¹Post Graduate Student, Department of Conservative Dentistry & Endodontics, Himachal Dental College, Sundernagar, Himachal Pradesh.

²Professor, Department of Conservative Dentistry & Endodontics, Himachal Dental College, Sundernagar, Himachal Pradesh.

³Reader, Department of Conservative Dentistry & Endodontics, Himachal Dental College, Sundernagar, Himachal Pradesh.

⁴Oral & Maxillo-facial Surgeon, Government Health Services, Himachal Pradesh.

Received: February 2020

Accepted: February 2020

Copyright: © the author(s), publisher. It is an open-access article distributed under the terms of the Creative Commons Attribution Non-Commercial License, which permits unrestricted non-commercial use, distribution, and reproduction in any medium, provided the original work is properly cited.

ABSTRACT

Endodontically treated teeth are affected by a higher risk of biomechanical failure than vital teeth. The use of post-retained restorations has been questioned because of potential tooth weakening. With the development of adhesive dentistry and advent of reinforced-ceramic materials, restoration of teeth with extensive loss of coronal tissue became feasible by means of cuspal coverage restorations including endocrowns. It is an adhesive restoration with minimally invasive preparation satisfying the criteria that are primarily biomechanical in nature. The remaining tooth substance is thus more robust, resulting in increased longevity.

Keywords: Endocrown, adhesive restoration, endodontically treated teeth.

INTRODUCTION

After the tooth has undergone root canal therapy, it becomes structurally weak due caries removal, removal of previous restorations and subsequent use of files during the bio-mechanical preparation resulting in the tooth structure being weak and being at a risk of fracture under the occlusal load.^[1] Therefore, it is very important to restore the tooth with a suitable material so that the endodontically treated tooth should have a good prognosis and it can resume full function and serve satisfactorily as an abutment for a fixed dental prosthesis or a removable partial dental prosthesis if required.

There are numerous techniques which have been mentioned in the literature to restore the endodontically treated tooth.^[2,3] While selecting the method to be used to restore the endodontically treated tooth; one should keep the amount of remaining tooth structure in mind. To provide the best prognosis for longevity with respect to these teeth, clinician must minimize the risk of future tooth fracture by selecting a design and a material that suits best to maximize the function and appearance of tooth.^[4,5]

As field of dentistry is constantly evolving, newer techniques, materials are being developed. Options in restoring an endodontically treated has also

improved from cast post, thread post, fiber post, to ceramic post (CERCON) and Endocrowns.

An Endocrowns can be defined as a monolithic (one-piece) ceramic bonded construction characterized by a supra-cervical butt joint, retaining maximum enamel to improve adhesion.

The concept of endocrown was given by Pissis.^[6] The aim behind the fabrication of endocrown was to eliminate the metal and to get all -ceramic bonded reconstruction. The preparation for endocrowns is different from that for conventional complete crowns. The review article highlights the various clinical implications of endocrowns.

Treatment options to restore endodontically treated teeth:

Depending on amount of remaining tooth structure, there are different options available for endodontically treated teeth:

| Amount of tooth structure remaining | Treatment options available |
|--|--|
| 1.) Minimal loss of coronal structures | The restorative material of choice should be composite resin with suitable bonding system. ^[7] But certain point has to be kept in mind before restoring a tooth with a restorative material. - access cavity should be small / ideal - minimal / ideal enlargement of pulp chamber - no cracks present in the tooth (Vertical / Horizontal) <u>Contraindication:</u> Patients with para functional habits. Such patients would require crowns to provided |

Name & Address of Corresponding Author

Dr Mahender Singh
Oral & Maxillo-facial Surgeon,
Government Health Services,
Himachal Pradesh.

| | |
|--|--|
| | strength to avoid fracture of tooth. |
| 2.) Up to One-Half of the Coronal Tooth Structure Missing | Complete occlusal coverage with help of endocrown or onlay restoration is sufficient instead of post and core. ^[8] |
| 3.) More Than Half of the Coronal Tooth Structure is Missing | When more than half of the coronal tissue is lost, such cases post-core restoration is the only option to ensure tooth-restoration continuum strength and resistance to fracture. Preparation design (maintaining 1.0-1.5 mm of the walls), remaining coronal tooth structure should provide stability against rotational forces. A ferrule effect should be attained by extending restoration margins 1.5-2.0 mm below the foundation limits. ^[9,10] Occlusal anatomy and function are usually restored with a full crown. This option, however, presents a higher biomechanical risk of failure related directly to the amount of missing tooth structure. |
| 4.) Most of the Coronal Tooth Structure is Missing | Extraction and dental implants might be then acceptable as an alternative to conventional treatment of severely compromised posterior teeth. ^[11,12] This case presents the least favorable biomechanical situation and cannot be satisfactorily or safely approached in the long term. Since orthodontic extrusion is rarely performed on pluriradicular teeth, extensive crown lengthening to attain a ferrule effect and restoration stability should no longer be considered as a feasible option. |

Endocrown Restorations

As dentistry is moving towards minimally invasive preparations, with maximal tissue conservation, any method which achieve this will be considered ‘the gold standard’ for restoring ETT. By following this rationale, endocrowns can be used as a prosthetic option in restoration of endodontically treated incisors, premolars and molars with excessive tissue loss.^[13-16]

Pissis was the first person to describe about endocrown technique according to him it is as ‘mono-block porcelain technique’.^[6] In 1999, the endocrown was described for the first time by Bindle and Mormann as adhesive endodontic crowns and characterized as total porcelain crowns fixed to endodontically treated posterior teeth.^[17]

Retention of these crowns is achieved by the internal portion of the pulp chamber and on the cavity margins, so macromechanical retention is provided by the pulpal walls, and micromechanical retention is obtained by the use of adhesive cementation.

Indications:

1. Cases in which there is excessive loss of tissue of the crown, interproximal space is limited and traditional rehabilitation with post and crown is not possible because of inadequate ceramic thickness.^[18]
2. Molars with clinically low crowns.
3. Where the root canals are calcified or very slender roots.

Contraindications:

1. Less than 3mm pulp chamber depth.
2. When adhesion cannot be assured.
3. If only negligible remaining tooth structure is present.^[19]

Other advantages of endocrowns are easy to apply and require a short clinical time, low cost, short preparation time, ease of application, minimal chair time and increased aesthetic properties.^[20]

Tooth Preparation for Endocrown restoration as suggested by Bindl and Mormann.^[21]

After completion of the root canal preparation some preparation / modification is required for proper fabrication of endocrowns. There are no guidelines present in the literature which can be used for preparation but they certain steps have have to followed in preparation of endocrowns.^[22]

- Circumferential 1.0-1.2 mm depth butt margin
- 5 mm depth for the first maxillary premolars and a 5 mm diameter and a 5 mm depth for molars
- The thickness of the ceramic occlusal portion of endocrowns is usually 3-7 mm

Steps in Occlusal preparation

- a) The first step is to achieve an overall reduction in the height of the occlusal surface of at least 2 mm in the axial direction.
- b) This reduction is done by drilling 2-mm-deep grooves as guides [Figure 1], then using a green diamond wheel bur to reduce the occlusal surface
- c) The bur is oriented along the major axis of the tooth and held parallel to the occlusal plane [Figure 2] this allows a flat surface, which determines the position of the cervical margin or “cervical sidewalk.”
- d) The cervical margin should be supragingival; however, if clinical factors or esthetics require, the margin can follow the gingival margin.
- e) Differences in level between the various parts of the cervical margin must be linked by a slope of no more than 60° to avoid a staircase effect.
- f) Enamel walls less than 2 mm thick should be removed.

1. Steps in Axial Preparation

- a) In this step undercuts are eliminated in the access cavity. A total occlusal convergence of 7° is used to make the coronal pulp chamber and endodontic access cavity continuous with help of a cylindrical-conical green diamond bur
- b) The orientation of the bur is along the long axis of the tooth [Figure 3], the preparation is carried out without excessive pressure and without touching the pulpal floor.

- c) Removing too much tissue from the pulp chamber walls will reduce their thickness and the width strip of enamel.
- d) The depth of the cavity should be at least 3 mm.

Polishing the Cervical Band

- a) The bur used in this step has the same taper as the one used in axial preparation, but a larger diameter and a finer particle size.
- b) It should be guided around the entire surface of the cervical band to remove micro-irregularities and produce a flat, polished surface. [Figure 4] The margin line should appear as a regular line with a sharp edge [Figure 5a and 5b]

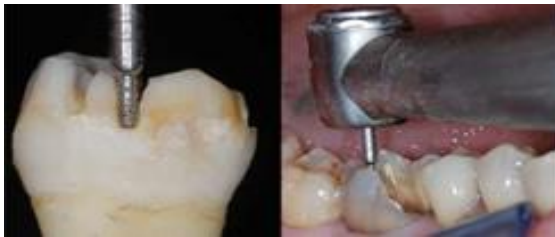

Figure 1: Making the guide grooves

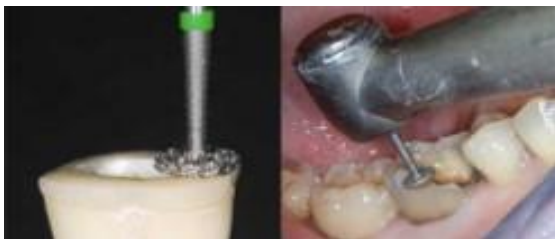

Figure 2: Preparation of the cervical margin or "cervical sidewalk" using a wheel bur held parallel to the occlusal plane.

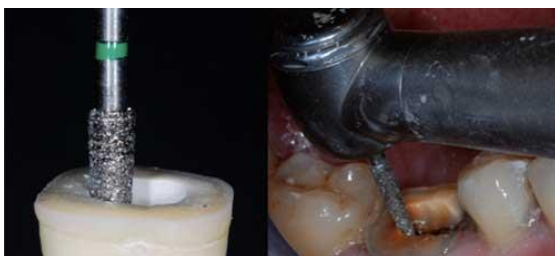

Figure 3: Axial preparation using a cylindro-conical drill to make the coronal pulp chamber continuous with the access cavity.

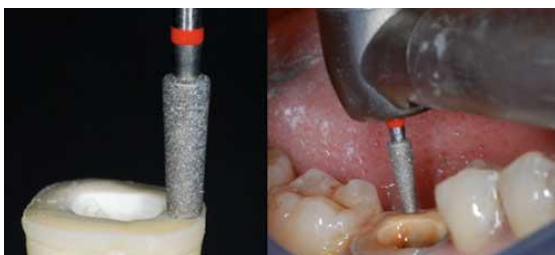


Figure 4: Polishing the Cervical Band

Preparation of the Cavity Floor

- a) The entrance to the pulpal canal is opened. Gutta percha is removed to a depth not exceeding 2 mm to

take advantage of the saddle-like anatomy of the cavity floor.

This should be done with a nonabrasive instrument to maintain the integrity of the canals entrance. No drilling of dentin is carried out. A hot small Burnisher can be used to remove the 2mm of Gutta Percha.

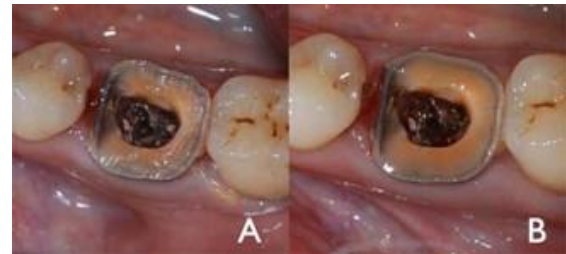

Figure 5: Cervical margin before (a) and after (b) polishing

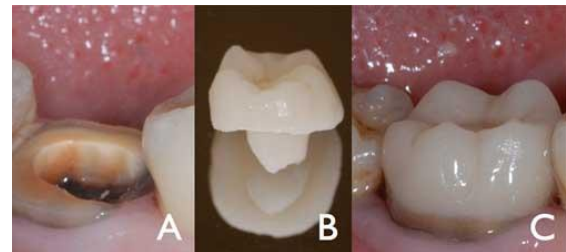


Figure 6: Prepared tooth (a), endocrown (b) and final result after bonding (c). Cementation

Cleaning the Pulp Chamber

Ultrasound is recommended to clean the pulp chamber and its floor thoroughly. Abrasion is not indicated. But Saline can also be with can be used with help of a syringe where Ultrasonic cleaning is not recommended

Cementation

Resin cements composed of Bis-GMA or UDMA resin matrix and inorganic filler particles are the most popular types of cements. They are used in comparison conventional cements as they have superior mechanical and aesthetic properties, resin cements have an increasing use in cementation of ceramic, metal and composite indirect restorations.^[23] When Eugenol Based sealers are used for the obturation it inhibits the polymerization of the resin cements. While during obturation if these sealers are used then before cementation of the endocrown is important removed them. Dual-polymerizable luting resins can be adequately polymerized when they are used for luting thick indirect endocrown restorations.^[24]

- Before bonding, precision fit and marginal adaptation of endocrowns is evaluated.
- Cementation of endocrowns were etched with 5% hydrofluoric acid for 20 seconds, rinsed with water for 30 seconds, ultrasonically cleaned in distilled water for 3 minutes, and dried.

- A silane coupling agent (RelyX Ceramic Primer, 3M ESPE) is applied and allowed to dry for 1 minute. Then light cured for 10 seconds.^[25]

DISCUSSION

In study done by Bindl and Mormann ‘evaluation of adhesively placed endocrowns after 2 years concluded that “the overall clinical quality of the endocrowns was very good”.^[17] In another study by Bernhart et al, they evaluated 14 endocrowns concluded that endocrowns “represent a very promising treatment alternative for endodontically treated molars.”

Mormann et al.^[27,28] reported that the fracture resistance of endocrowns with an occlusal thickness of 5.5 mm was two times higher than that of ceramic crowns with a classic preparation and an occlusal thickness of 1.5 mm. The butt joint, or cervical sidewalk, is the base of the restoration — with a band of peripheral enamel that optimizes bonding.^[28] The goal is to achieve a wide, even, stable surface that resists the compressive stresses that are most common on molars.^[29] Actually the root canals do not require any specific shape; therefore they are not weakened by the drilling and they will not be subject to the stresses associated with the use of post.^[29,30]

In 2012, Biacchi and Basting compared the fracture strength of 2 types of full ceramic crowns: indirect conventional crowns retained by glass fiber posts and endocrowns. They concluded that endocrowns were more resistant to compressive forces than conventional crowns.^[15]

CONCLUSION

Endocrowns have been used as an alternative to conventional post-core and fixed partial dentures in restoration of endodontically treated teeth with extensive coronal tissue loss. Compared to traditional methods, better aesthetics and mechanical performance, low cost and short clinical time are the advantages of endocrowns.

REFERENCES

1. Iris Slutzky-Goldberg, Hagay Slutzky, Colin Gorfil, And Ami Smidt. Restoration of Endodontically Treated Teeth Review and Treatment Recommendations
2. James W. Robbins. Guidelines for The Restoration of Endodontically Treated Teeth.
3. Ernest S. Reeh, Harold H. Messer. Reduction in Tooth Stiffness as a Result of Endodontic and Restorative Proc
4. Y.-H. Chang, W.-H. Lin, W.-C. Kuo, C.-Y. Chang, And C.-L. Lin, “Mechanical Interactions Of Cuspal-Coverage Designs And Cement Thickness In a Cusp-Replacing Ceramic Premolar Restoration: a Finite Element Study,” Medical And Biological Engineering And Computing, Vol. 47, No. 4, Pp. 367–374, 2009.
5. C.-L. Lin, Y.-H. Chang, And P.-R. Liu, “Multi-Factorial Analysis of a Cusp-Replacing Adhesive Premolar Restoration: a Finite Element Study,” Journal Of Dentistry, Vol. 36, No. 3, Pp. 194–203, 2008.
6. Pissis P. Fabrication of a metal-free ceramic restoration utilizing the monobloc technique. *Pract Periodontics Aesthet Dent*.1995;7(5): 83-94.
7. Krejci I, Stavridakis M. New perspectives on dentin adhesion—differing methods of bonding. *Pract Periodontics Aesthet Dent* 2000. October;12(8):727–732.
8. Dietschi D, Spreafico R. Current clinical concepts for adhesive cementation of tooth-colored posterior restorations. *Pract Periodontics Aesthet Dent* 1998. Jan-Feb;10(1):47–54
9. Cathro PR, Chandler NP, Hood JA. Impact resistance of crowned endodontically treated central incisors with internal composite cores. *Endod Dent Traumatol* 1996. June;12(3):124–8. 10.
10. Sorensen JA, Engelman MJ. Ferrule design and fracture resistance of endodontically treated teeth. *J Prosthet Dent* 1990. May;63(5):529–36.
11. Cho GC. Evidence-based approach for treatment planning options for the extensively damaged dentition. *J Calif Dent Assoc* 2004. December;32(12):983–90.
12. Mordohai N, Reshad M, Jivraj SA. To extract or not to extract? Factors that affect individual tooth prognosis. *J Calif Dent Assoc* 2005. April;33(4):319–28.
13. Zarone F, Sorrentino R, Apicella D, Valentino B, Ferrari M, Aversa R et al.Evaluation of the biomechanical behavior of maxillary central incisors restored by means of endocrowns compared to a natural tooth: a 3D static linear finite elements analysis. *Dent Mater* 2006. November;22(11):1035–44.
14. Lin CL, Chang YH, Pai CA. Evaluation of failure risks in ceramic restorations for endodontically treated premolar with MOD preparation. *Dent Mater* 2011. May;27(5):431–8. 10.1016/j.dental.2010.10.026.
15. Biacchi GR, Basting RT. Comparison of fracture strength of endocrowns and glass fiber post-retained conventional crowns. *Oper Dent* 2012. Mar-Apr;37(2):130–6. 10.2341/11-105-L
16. Bindl A, Richter B, Mörmann WH. Survival of ceramic computer-aided design/manufacturing crowns bonded to preparations with reduced macroretention geometry. *Int J Prosthodont* 2005. May-Jun;18(3):219–24.
17. Bindl A, Mormann WH. Clinical evaluation of adhesively placed Cerec endo-crowns after 2 years—preliminary results. *J Adhes Dent* 1999;1(3):255–65.
18. Chang CY, Kuo JS, Lin YS, Chang YH. Fracture resistance and failure modes of CEREC endo-crowns and conventional post and core-supported CEREC crowns. *J Dent Sci* 2009;4(3):110–7.
19. Vinola SM, Balasubramanian S, Mahalaxmi S. —Endocrown—An Effective Viable Esthetic Option for Expurgated Endodontically treated Teeth: Two Case Reports. *Journal of Operative Dentistry and Endodontics*. 2017, 2, 97-102.
20. Dietschi D, Duc O, Krejci I, Sadan A. Biomechanical considerations for the restoration of endodontically treated teeth: a systematic review of the literature, Part II (Evaluation of fatigue behavior, interfaces, and in vivo studies). *Quintessence Int* 2008. February;39(2):117–29.
21. Fages M, Bennisar B.The Endocrown: A Different Type of All-Ceramic Reconstruction for Molars. *J Can Dent Assoc* 2013;79:
22. Chang CY, Kuo JS, Lin YS, Chang YH. Fracture resistance and failure modes of CEREC endo-crowns and conventional post and core-supported CEREC crowns. *J Dent Sci* 2009;4(3):110–7.
23. McCabe JF, Walls AW. Application of dental materials. 8th ed. Madlen:Blackwell Science; 1998, p. 189-201.
24. Gregor L, Bouillaguet S, Onisor I, Ardu S, Krejci I, Rocca GT. Microhardness of light- and dual-polymerizable luting resins polymerized through 7.5-mm-thick endocrowns. *J Prosthet Dent* 2014. October;112(4):942–948. 10.1016/j.prosdent.2014.02.008

25. Effect of Intracoronal Depth of Teeth Restored with Endocrowns on Fracture Resistance: In Vitro and 3-dimensional Finite Element Analysis JOE 44(7) • June 2018
26. Mormann WH, Bindl A, Lüthy H, Rathke A. Effects of preparation and luting system on all-ceramic computer-generated crowns. Int J Prosthodont 1998. Jul-Aug;11(4):333-9.
27. Tsai YL, Petsche PE, Anusavice KJ, Yang MC. Influence of glass-ceramic thickness on hertzian and bulk fracture mechanisms. Int. J Prosthodont. 1998; 11(1):27-32.
28. Donovan TE, Chee WW. Cervical margin design with contemporary esthetic restorations. Dent Clin North Am. 2004;48(2):vi, 417-31.
29. Zogheib LV, Saavedra Gde S, Cardoso PE, Valera MC, Araújo MA. Resistance to compression of weakened roots subjected to different root reconstruction protocols. J Appl Oral Sci. 2011;19(6):648-54.
30. Fernandes AS, Dessai GS. Factors affecting the fracture resistance of post-core reconstructed teeth: a review. Int J Prosthodont. 2001; 14(4):355-63.

How to cite this article: Arora D, Goel M, Kumar V, Verma S, Mandhotra P, Singh M. Endocrowns- An innovative Post Endodontic Restoration. Ann. Int. Med. Den. Res. 2020; 6(2):DE19-DE23.

Source of Support: Nil, **Conflict of Interest:** None declared