

Lasing: Lighten Your Teeth Tone

Sana Farooq¹, Nimra Iqbal²

¹MDS student, Department of Pedodontics and Preventive Dentistry, ITS Dental College, Hospital and Research Centre, Greater Noida.

²MDS student, Department of Conservative and Endodontics, ITS Dental College, Hospital and Research Centre, Greater Noida.

Received: December 2019

Accepted: December 2019

Copyright: © the author(s), publisher. It is an open-access article distributed under the terms of the Creative Commons Attribution Non-Commercial License, which permits unrestricted non-commercial use, distribution, and reproduction in any medium, provided the original work is properly cited.

ABSTRACT

Lightening tooth color is what a patient demands and can be successfully done by a wide variety of bleaching methods, including in-office (professionally administered), at-home (professionally dispensed) and over-the-counter (self-administered) techniques. This is a case report of treatment of 15 year old female patient with the chief complaint of discolored upper right front tooth region with laser bleaching with biolase.

Keywords: Vital bleaching, Biolase, Modified Deans fluorosis index.

INTRODUCTION

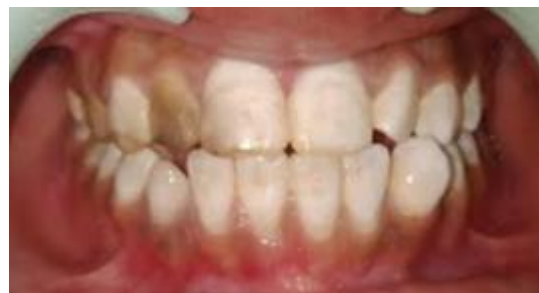Laser-assisted bleaching is the best modality available in which laser accelerates release of free radicals within the bleaching gel to decrease time of whitening procedure.^[1] In-office laser bleaching has an advantage of dentist control, avoidance of tissue exposure, minimal post bleaching hypersensitivity, reduced treatment time and enhanced patient satisfaction due to immediate results.^[2] Laser whitening gels incorporate chromophores or activator specific to a particular wavelength which absorbs the laser light and quicken the bleaching process.^[3]

CASE REPORT

A 15 year-old female patient reported to the Department of Pedodontics and Pediatric Dentistry with the chief complaint of discolored tooth with respect to her right upper front tooth region since childhood. On examination, generalized grade 2 dental fluorosis was seen and Grade 4 Dental fluorosis in 12 and 14. The patient was explained about the various treatment modalities available, the procedures to be undertaken and an informed consent was obtained.

A thorough oral prophylaxis was done 3 weeks prior and polishing of the teeth was done. On the day of treatment removal of surface plaque and stain with pumice prior to administration of

whitening agent. Modified Dean's Fluorosis Index (1942) was recorded at baseline and the end of the first and second visit, respectively. Preoperative photographs were taken at baseline [Figure 1]. The patient was asked to wear protective eyewear. The teeth were isolated using cotton rolls. A separating media was applied and a liquid dam was applied along the gingival margins [Figure 2 a]. The liquid dam was cured using standard curing light, holding the handpiece at least 2cm from tooth for 5 to 10 seconds.



Using a single tufted applicator tip apply 1 mm whitening gel 45% hydrogen peroxide [Figure 2 b] by mixing the two syringes containing activator and base till a uniform lavender colour (almost 20 times) is achieved according to manufacturer's recommendations [Figure 3]. After an even mix was obtained, a thin layer of about 1 mm thickness was applied on dried teeth with the brush tip applicator. Apply a disposable sleeve over the handpiece's arch to disperse laser light over a broad area of teeth [Figure 2 c].

The tooth was irradiated using diode laser (BIOLASE™) with a power setting 7W power, continuous wave mode and 200 J energy output in contact mode for a time of about 30 second for

Name & Address of Corresponding Author

Dr. Sana Farooq
MDS student, Department of Pedodontics and Preventive Dentistry,
ITS Dental College, Hospital and Research Centre,
Greater Noida.

each quadrant [Figure 4]. The gel was left on the teeth for an additional 5 minutes to allow the teeth to absorb the laser activated hydrogen peroxide which allows continued whitening after laser exposures. This procedure was repeated twice with a gap of 1 week. At the end clean rubber dam with explorer and rinse. Apply desensitizer potassium nitrate for 15 to 20 minutes [Figure 2 d]. In case of any discomfort the patient was asked to report back to the clinic. Indirect Composite veneering was done on followup visit. The postoperative photographs were taken [Figure 5c]. The color change evaluation using 3D Vita shade guide was noted. The patient was advised not to consume products that stain teeth for up to the next 48 hours such as coffee, tobacco, tea, tomato sauce, cold drink etc.

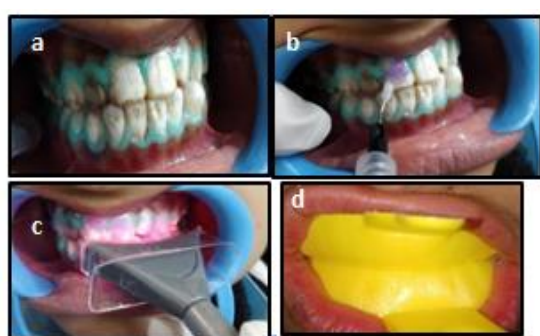


Figure 2: a) Placement of gingival barrier liquid dam b) Application of bleaching agent. c) Applying biolase laser system d) Apply desensitizer.

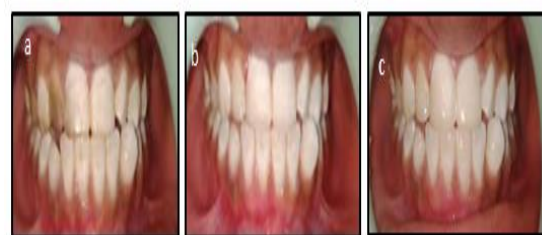
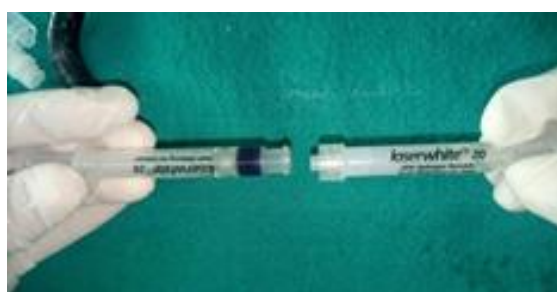


Figure 5: a) Preoperative photograph b) Post laser bleaching c) Composite veneering

DISCUSSION

Initially bleaching was primarily performed with 35%–37% carbamide peroxide or 30%–40% hydrogen peroxide and the use of hydrogen peroxide (H₂O₂) for conventional bleaching was introduced way back in 1884.^[4-6] Light sources were marketed with the idea that light plays a significant role in tooth bleaching as catalyst for the ionization of Hydrogen peroxide in the bleaching gel and increasing the bleaching effect.^[7]

Anaraki et al showed that the damage caused by bleaching with a 810 nm diode laser was less than the one caused by conventional bleaching without any laser activation.^[4,5] Chromophores in the laser-activated gels absorb the narrow wavelength of diode lasers thereby increasing the efficacy of bleaching.^[5]

Its seen that the rate of the chemical reaction increases double fold with a rise of 10°C. Also the thickness of the bleaching gel layer is an important factor to ensure that the laser light can pass through this layer. The distance between the handpiece or fibre end and the gel is important criteria while considering the energy and impact of bleaching.^[3] When Biolase Laserwhite20™ is used in combination with a bleaching gel containing a chromophore (sulphorhodamine) photodynamic reactions occur (photochemical activation of the gel with limited photothermal activation). This combination of wavelength and specifically dyed bleaching gel also allows for safe bleaching (no damage of the enamel, no heating of the pulp) when the manufacturers instructions are followed.^[3]

CONCLUSION

Vital bleaching is the cosmetic dental procedures asked by patients to seek a more pleasing smile. Laser bleaching causes profound quicker whitening with little or no surface alterations. The degree of whitening varies from patient to patient depends on type of stain, enamel thickness, tooth structure and age.

REFERENCES

1. Fekrazad R, Alimazandarani S, Kalhori KAM, Assadian H, Mirmohammadi SM. Comparison of laser and power bleaching techniques in tooth color change. *J Clin Exp Dent.* 2017;9(4):e511-5
2. Cassoni A, Rodrigues JA. Argon laser: a light source alternative for photopolymerization and in-office tooth bleaching. *General Dent.* 2007;55: 416
3. Dang M, Shetty O. Nine Shade Change by Laser-Assisted Teeth whitening. *Int J Laser Dent* 2013; 3(2): 73-76
4. Anaraki SN, Shahabi S, Chiniforush N, Nokhbatolfoghahaei H, Assadian H, Yousefi B, et al. Evaluation of the effects of conventional versus laser bleaching techniques on enamel microroughness. *Lasers Med Sci* 2015;30:1013-8.
5. Azarbayjani Z, Jafarzadeh Kashi TS, Erfan Y, Chiniforush N, Rakhshan V. Efficacy of diode laser irradiation during dental bleaching in preventing enamel damage caused by bleaching. *Dent Res J* 2018;15:320-6
6. DE Abreu DR, Sasaki RT, Amaral FL, Flório FM, Basting RT. Effect of home-use and in-office bleaching agents containing hydrogen peroxide associated with amorphous calcium phosphate on enamel microhardness and surface roughness. *J Esthet Restor Dent* 2011;23:158-68.
7. De Moor RJ, Verheyen J, Verheyen P, Diachuk A, Meire MA, De Coster PJ, De Bruyne M, Keulemans F. Laser teeth bleaching: evaluation of eventual side effects on enamel and the pulp and the efficiency in vitro and in vivo. *Scientific World Journal.* 2015;2015:835405.

How to cite this article: Farooq S, Iqbal N. Lasing: Lighten Your Teeth Tone. *Ann. Int. Med. Den. Res.* 2020; 6(1): DE01-DE03.

Source of Support: Nil, **Conflict of Interest:** None declared