

# Assessment of 100 Patients of Tooth Hemisection Upto 2 Years of Follow-Up: A Retrospective Study

Nutan Mala<sup>1</sup> Binoy Kumar Singh<sup>2</sup> C.K. Wang<sup>3</sup> Abhinav Kumar Singh<sup>2</sup> Somnath Pal<sup>2</sup>

<sup>1</sup>PG Final Year, <sup>2</sup>Professor, <sup>3</sup> Professor and Head, Department of Conservative Dentistry and Endodontics, Buddha Institute of Dental Sciences and Hospital, Patna Bihar

Received: August 2020

Accepted: August 2020

## ABSTRACT

**Background:** The removal of a root and the overlaying anatomic crown is referred to as a hemisection. Hemisection of either maxillary or mandibular molar is often a means of retaining teeth needed for restorative abutments or occlusal support. Hence; the present study was conducted for assessing the profile of 100 patients of tooth Hemisection and their outcome upto 2 years of follow-up. **Methods:** The present study was conducted to evaluate the face of 100 patients of tooth Hemisection and their effect upto 2 years of follow-up. Complete demographic details of all the patients were obtained from data record files. Preoperative and postoperative Radiographic information were obtained from record files. All the patients had periodontal pocket formation accompanied by bone loss. All the Hemisection procedures were performed under local anesthesia. Follow-up instructions were given to all the patients. After analysing the follow-up data, clinical and radiographic details were obtained and were recorded separately. **Results:** The prognosis on two years follow-up was found to be 95 percent. Non-significant results were obtained while assessing age, gender and history of bruxism as a risk factor for prognosis. However; while analysing other risk factors, it was observed that positive smoking history and presence of diabetes were significant risk factors for failure of Hemisection procedure. While comparing the tooth arch and root type among patients on the basis of prognosis of Hemisection, non-significant results were obtained. **Conclusion:** Hemisection as a treatment option to conserve the tooth structure and use it as an abutment is very appropriate.

**Keywords:** Hemisection, Prognosis.

## INTRODUCTION

The removal of a root and the overlaying anatomic crown is referred to as a hemisection. Hemisection of either maxillary or mandibular molar is often a means of retaining teeth needed for restorative abutments or occlusal support. This treatment can produce predictable results as long as proper case selection is followed by an interdisciplinary approach with endodontic, surgical and prosthetic procedures. Hemisection represents a form of conservative policy, which aims at retaining as much of the original tooth structure as possible. The results are durable, and success rates are high if specific primary considerations are taken into account.<sup>[1-3]</sup>

Hemisection is the surgical separation of a multirrooted tooth, especially a mandibular molar through the furcation in such a way that a root and the associated portion of the crown may be removed. The treatment goal is the preservation of the remaining tooth structure and restoration of the function. Once the tooth has been judged appropriate for this treatment, it must undergo endodontic therapy first and then must be prepared

for complete crown coverage because two roots are present in mandibular molars, half of the crown and the associated seed is removed.<sup>[4-6]</sup> Hence; the present study was conducted for assessing the profile of 100 patients of tooth Hemisection and their outcome upto 2 years of follow-up.

## MATERIALS AND METHODS

The present study was conducted for assessing the profile of 100 patients of tooth Hemisection and their outcome up to 2 years of follow-up. Complete demographic details of all the patients were obtained from data record files. Preoperative and postoperative Radiographic information were obtained from record files. All the patients had periodontal pocket formation accompanied by bone loss. All the Hemisection procedures were performed under local anesthesia. Follow-up instructions were given to all the patients. After analysing the follow-up data, clinical and radiographic details were obtained and were recorded separately. All the results were recorded in Microsoft excel sheet and were analysed by SPSS software. Chi-square test was used for evaluation of level of significance.

## RESULTS

In the present study, a total of 100 patients who underwent Hemisection of molars were analysed. On follow-up, it was observed that tooth was lost in 5 cases, while the tooth was present and was in

### Name & Address of Corresponding Author

Nutan Mala,  
Post Graduate Student,  
Department of Conservative Dentistry and  
Endodontics, Buddha Institute of Dental Sciences  
and Hospital,  
Patna Bihar

good condition in 95 patients. Hence; the prognosis on two years follow-up was found to be 95 percent. Non-significant results were obtained while assessing age, gender and history of bruxism as a risk factor for prognosis. However; while analysing other risk factors, it was observed that positive

smoking history and presence of diabetes were significant risk factors for failure of Hemisection procedure. While comparing the tooth arch and root type among patients on the basis of prognosis of Hemisection, non-significant results were obtained.

**Table 1: Prognosis of Hemisection on follow-up**

Parameter	Number of patients	Percentage
Hemisection Tooth absent	5	5
Hemisection Tooth present	95	95

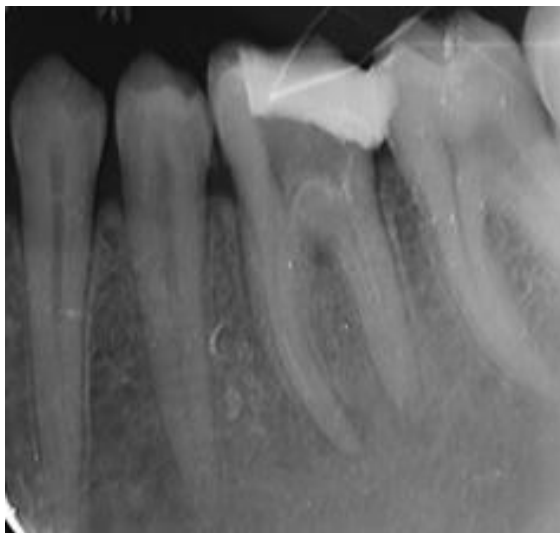
**Table 2: Demographic and clinical data**

Parameter		Teeth present (n= 95)	Teeth absent (n=5)	p- value
Age group (years)	Less than 45	32	2	0.12
	More than 45	63	3	
Gender	Males	44	3	0.71
	Females	51	2	
Smoking history	Present	32	5	0.00*
	Absent	63	0	
Diabetic status	Diabetic	41	4	0.01*
	Non-diabetic	54	1	
Bruxism habit	Present	56	3	0.39
	Absent	39	2	

**Table 3: Comparison between both groups in relation to tooth arch and root type**

Parameter		Teeth present (n= 95)	Teeth absent (n=5)	p- value
Site	Maxilla	38	2	0.74
	Mandible	57	3	
Root	Mesial	23	1	0.69
	Distal	38	2	
	Palatal	34	2	

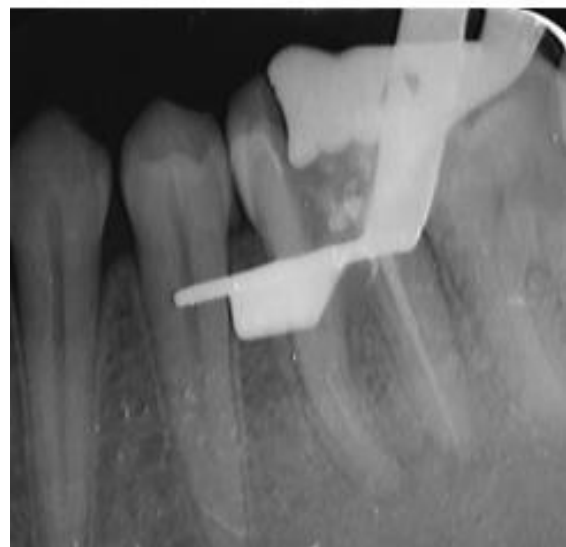**DISCUSSION**



**Figure 1: Pre-Operative**

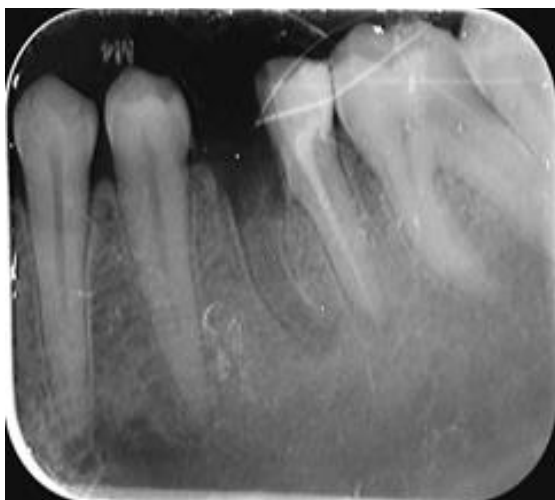As a practitioner of art and science of dentistry, a clinician is expected to provide a functional dentition for a lifetime. Loss of the posterior teeth may result in several undesirable sequelae which require prevention and maintenance measures. The treatment options for an extensively decayed and unrestorable molar are limited. The most common treatment for such tooth may include extraction followed by a removable partial denture, fixed

partial denture, or a dental implant to replace the missing tooth. However, with appropriate case selection, hemisection can be a relatively simple, conservative, inexpensive treatment with good chances of success. Hemisection and root resection have now been established as successful treatment modalities.<sup>[7-9]</sup> Hence; the present study was conducted for assessing the profile of 100 patients of tooth Hemisection and their outcome upto 2 years of follow-up.

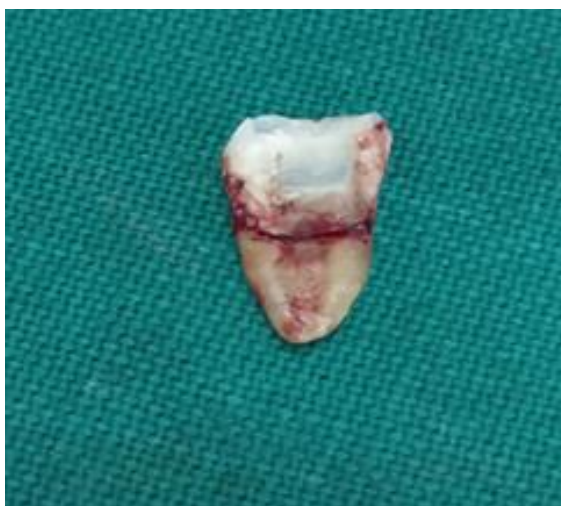

**Figure 2: Obturation done**

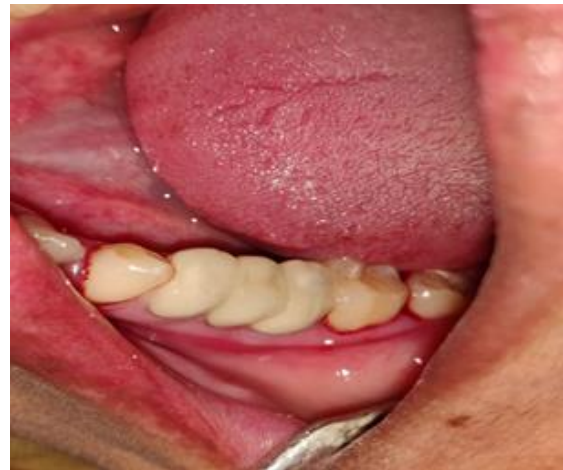In the present study, a total of 100 patients who underwent Hemisection of molars were analysed. On follow-up, it was observed that tooth was lost in 5 cases, while the tooth was present and was in good condition in 95 patients. Hence; the prognosis on two years follow-up was found to be 95 percent. Non-significant results were obtained while assessing age, gender and history of bruxism as a risk factor for prognosis. Jean-Marie Megarbane et al evaluated the long-term effects of root resection and hemisection of 195 patients with up to 40 years of follow-up. Records of 195 patients who had undergone root resection or hemisection were reviewed. A minimum follow-up of 5 years was needed. A molar was recorded as survival if it was still present and functional without any signs of discomfort, pain, or pathology from restorative, endodontic, and periodontal points of view. Ninety-eight patients were excluded for not accomplishing the minimum 5-year observation period. Of the 97 remaining patients, 5 teeth were lost during the first 5 years of treatment and 92 teeth survived the follow-up period, ranging from 5 to 40 years. The overall survival rate was 94.8%.<sup>[10]</sup>



**Figure 3: Hemisection done**



**Figure 4: Extracted root**



**Figure 5: PFM crown placed**

In the present study, while analysing other risk factors, it was observed that positive smoking history and presence of diabetes were significant risk factors for failure of Hemisection procedure. While comparing the tooth arch and root type among patients on the basis of prognosis of Hemisection, non-significant results were obtained. Shin-Young Park et al examined the factors influencing the survival rate of resected molars. Root-resection therapy was performed on 691 molars in 579 patients. The associated factors were examined from 342 of 402 molars that had been followed up for >1 year. Over the past ten years, 102 of 342 cases (29.8%) failed. The factors were classified into four groups and analyzed to determine their influence on the survival rate of the resected molars. Regarding the resection-related factors, the molars resected because of periodontal problems had a higher survival rate than those resected because of non-periodontal problems. Patient- and tooth-related factors had no effect on survival rates. Among the site-related factors, only the amount of bone support of the remaining roots at the time of surgery had a significant effect on the survival rate in the group of molars with periodontal problems. Root resection to treat periodontal problems had a better prognosis than for non-periodontal problems.<sup>[11]</sup> Newell et al examined 70 root resected molars in 62 patients for the quality of the resections. Twenty-one (30%) of the resections were considered faulty when subgingival, residual roots, furcal lips, and/or ledges were present. Failures were more frequent in maxillary molars (33.3%) than mandibular molars (22.7%). Often a favourable result may be negated by secondary decay after treatment. Failure of endodontic therapy due to any reason can lead to failure of the procedure. In addition, when the tooth has lost part of its root support, it will require restoration to permit it to function independently or to serve as an abutment for a splint or bridge. Buhler reported a 32% failure rate at ten years on 34 resected molars. Again, the main causes of

failure were endodontic pathology and root fracture, while only one tooth was extracted due to periodontal breakdown.<sup>[12,13]</sup>

## CONCLUSION

From the above results, the authors concluded that Hemisection as a treatment option to conserve the tooth structure and use it as an abutment is very appropriate. However; further studies are recommended.

## REFERENCES

1. Langer B, Stein SD, Wagenburg B. An evaluation of root resections: A ten years study. *J Periodontol* 1981; 52:719
2. Newman, Takei, Fermin A Carranza. Furcation: Involvement and treatment; William F IN: Clinical Periodontology, X edition, WB Saunder's Co. 200:996.
3. Buhler H. Survival rates of hemisected teeth: an attempt to compare them with survival rates of alloplastic implants. *Int J Periodontics Restorative Dent*. 1994; 14(6):536-43.
4. Dannewitz B, Krieger JK, Hüsing J, Eickholz P. Loss of molars in periodontally treated patients: A retrospective analysis five years or more after active periodontal treatment. *J Clin Periodontol* 2006;33:53-61.
5. Langer B, Stein SD, Wagenberg B. An evaluation of root resections. A ten-year study. *J Periodontol* 1981;52:719-22.
6. Basten CH, Ammons WF Jr., Persson R. Long-term evaluation of root-resected molars: A retrospective study. *Int J Periodontics Restorative Dent* 1996;16:206-19.
7. Hamp SE, Nyman S, Lindhe J. Periodontal treatment of multirooted teeth. Results after 5 years. *J Clin Periodontol* 1975;2:126-35.
8. Zafiropoulos GG, Hoffmann O, Kasaj A, Willershausen B, Deli G, Tatakis DN. Mandibular molar root resection versus implant therapy: A retrospective nonrandomized study. *J Oral Implantol* 2009;35:52-62
9. Erpenstein H. A 3-year study of hemisectioned molars. *J Clin Periodontol* 1983;10:1-10.
10. Jean-Marie Megarbane, Abdel Rahman Kassir, Nadim Mokbel, Nada Naaman. Root Resection and Hemisection Revisited. Part II: A Retrospective Analysis of 195 Treated Patients with Up to 40 Years of Follow-up. *Int J Periodontics Restorative Dent*. Nov/Dec 2018;38(6):783-789.
11. Shin-Young Park 1, Seung-Yun Shin, Seung-Min Yang, Seung-Beom Kye. Factors influencing the outcome of root-resection therapy in molars: a 10-year retrospective study. *J Periodontol*. 2009 Jan;80(1):32-40.
12. Newell DH. The role of the prosthodontist in restoring root resected molars: A study of 70 molar root resections. *J Prosthet Dent* 1991;65:7-15.
13. Buhler H. Evaluation of root resected teeth. Results after ten years. *J Periodontol* 1988;59:805-10.

**Copyright:** © the author(s), 2020. It is an open-access article distributed under the terms of the Creative Commons Attribution License (CC BY 4.0), which permits authors to retain ownership of the copyright for their content, and allow anyone to download, reuse, reprint, modify, distribute and/or copy the content as long as the original authors and source are cited.

**How to cite this article:** Nutan Mala Binoy Kumar Singh C.K. Wang Abhinav Kumar Singh Somnath Pal. Assessment of 100 Patients of Tooth Hemisection Upto 2 Years of Follow-Up: A Retrospective Study. *Ann. Int. Med. Den. Res.* 2020; 6(6):DE49-DE52.

**Source of Support:** Nil, **Conflict of Interest:** None declared