

# Treatment of Mixed Dentition Space Loss with Double Banded Space Regainer and Quad Helix - A Case Report.

Anika Uppal<sup>1</sup>, Rajender Singh<sup>2</sup>

<sup>1</sup>MDS (Pedodontics), <sup>2</sup>MDS (Prosthodontics) Medical Officer (Dental), Department of Health and Family Welfare, Himachal Pradesh, India.

Received: June 2020

Accepted: June 2020

## ABSTRACT

The premature loss of primary teeth results in loss of arch length and space closure for the eruption of permanent teeth. Space regainers are recommended in these patients for moving the teeth leading to normal eruption of the permanent tooth and restored arch integrity. The following case report describes a double banded space regainer for unilateral space gaining with minimum side effects along with nance holding arch for stability of maxillary arch followed by quad helix for maxillary arch expansion. Mandibular arch space was maintained by lower lingual holding arch.

**Keywords:** Banded space regainer, mixed dentition, space loss, expansion.

## INTRODUCTION

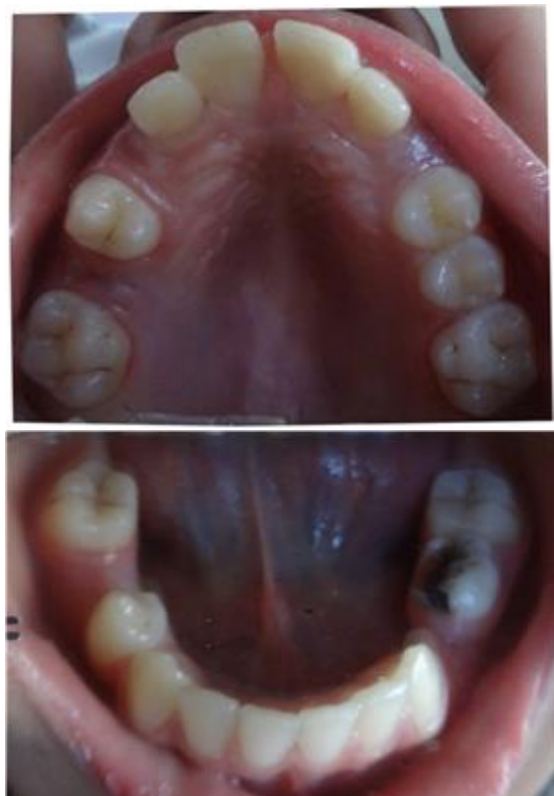The main motive of space regaining is to recover the lost arch width and perimeter.<sup>[1]</sup> The transition from the mixed to the permanent dentition should be closely monitored by the clinician.<sup>[2]</sup> When the normal sequence of exfoliation of primary teeth and eruption of permanent teeth does not happen, space maintainers must be used. If space maintenance is not carried out on the premature loss of deciduous molars, then an interceptive orthodontic procedure would have to be carried out with space regainers.<sup>[3]</sup> According to William Proffit, maxillary space can be regained easily than the mandibular space.<sup>[4]</sup> Therefore, a fixed type of space regainer was planned in this particular case. Space regained should be maintained until adjacent permanent teeth have erupted completely and/or until a subsequent comprehensive orthodontic treatment plan is initiated.<sup>[5]</sup> Early diagnosis and successful treatment of developing malocclusions can have both short-term and long-term benefits while achieving the goal of occlusal harmony, function, and dental facial aesthetics.<sup>[6]</sup>

The following article describes a case of judicious use of double banded space regainer in regaining the space lost due to the untimely loss of primary first molar, and hence distalization of posterior tooth to regain the lost space, i.e. permanent first molar.

## CASE REPORT

A 10-year old female patient reported to the department with a chief complaint of a decayed

and a mobile tooth. Past medical history was insignificant. Past dental history had shown that the patient got her decayed deciduous teeth extracted in private set up due to caries few years back. There was End on molar relationship bilaterally. Non erupted teeth were upper canines, upper right second premolar, lower right second premolar, left lower first premolar. [Figure 1a & 1b] The patient's chief complaint was attended and at the same time, her parents were informed about the space loss and its sequelae and the importance of timely intervention for the preservation of loss of arch length.



**Figure 1a & 1b: Pre-operative photographs of upper and lower arch.**

### Name & Address of Corresponding Author

Dr. Rajender Singh,  
MDS (Prosthodontics),  
Medical Officer (Dental),  
Department of Health and Family Welfare,  
Himachal Pradesh, India.

Dentition present [Figure 1a,1b]: 16 14 12 11  
21 22 24 25 26  
46 44 43 42 41  
31 32 33 75 36

Later, Models were made to check the space discrepancy. [Figure 2a & 2b]

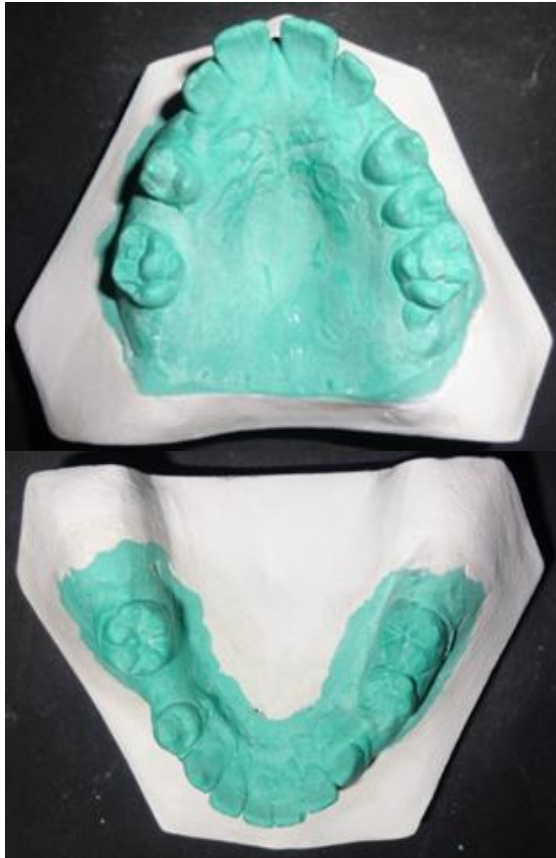

Figure 2a & 2b: Pre-operative models of upper and lower arch

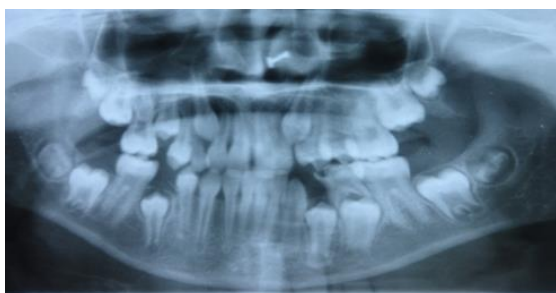

Figure 3: Pre-operative OPG showed loss of space wrt 15 and adequate space for lower molars.

The following measurements were made from the models [Figure 2a,b]

Midline diastema [2.5mm] was present.

There was only 3.5mm space between 16 and 14 for eruption of 15. There was 6mm space present between 12 and 14 as seen in models.

Model analysis showed extra 3mm space was required for 15 to erupt. 15 mm space was present for lower premolars to erupt and this was adequate space.

Ponts analysis showed Measured Molar Value less than Calculated Molar Value so there was need for expansion.

#### **Fabrication of Appliance and Treatment**

75 was restored and pit and fissure sealant was placed wrt 16 26 36 46.

In the next appointment-16 14 26 36 46 were banded.

Space regainer with open coil spring in upper arch wrt 16 and 14 and nance holding arch for anchorage was placed from 14 to 26

The permanent first molar and the first premolar of the first quadrant were banded (0.005 × 0.180 in) with molar tubes (0.7 mm diameter, 10 mm length) welded to them buccally. A stainless steel wire (0.7 mm width) inserted into the molar tubes. NiTi open coil springs were cut 2-3mm longer than the distance between anterior stop (solder joints) and molar tubes posteriorly, and incorporated into the wires. The assembly was cemented on to the teeth with the springs held in compression to half their lengths [Figure 4]. After 4 months, the space gained was 3 mm, hence the total space available for 15 was 6.5 mm [Figure 5]. The premolar 14 was supported with nance holding arch [Figure 5].

Lower permanent molars were also banded and LLHA placed for space maintenance. [Figure 6]

Space regaining took 4-5 months. The Ni-Ti coil was changed twice. When 15 erupted, maxillary expansion was done with the help of Quad helix. Single activation a month of the coils of quad helix was done. [Figure 7]

Observation of midline diastema[2mm] without any management till permanent canines erupted was done.

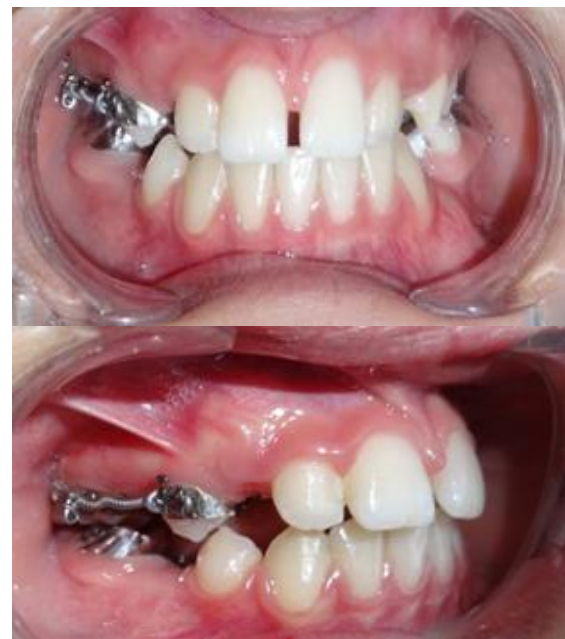

Figure 4: Banding and coil springs placed on 14 and 16



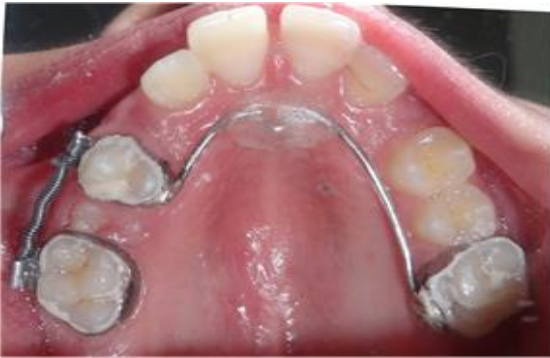

Figure 5: 14 supported with nance holding arch

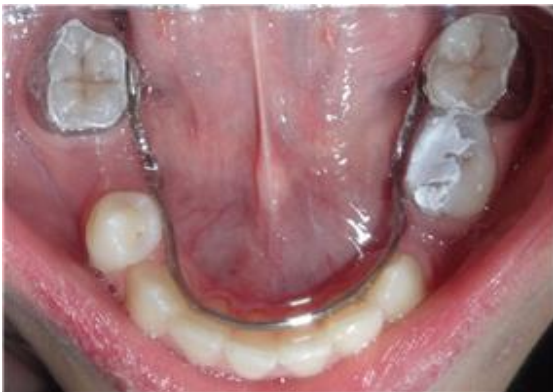

Figure 6: LLHA in lower teeth

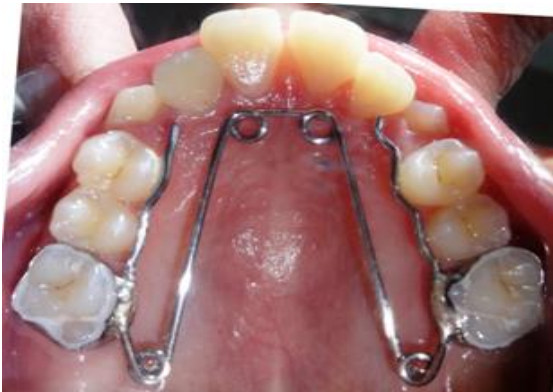

Figure 7: Quad helix placed after eruption of 15

#### Final Outcome of the Treatment

The permanent teeth erupted in their normal position with proper arch integrity and perimeter. [Figure 8] shows Post-operative OPG of patient showing normally erupted upper and lower teeth. [Figure 9] shows Post-operative photographs showing fully erupted dentition

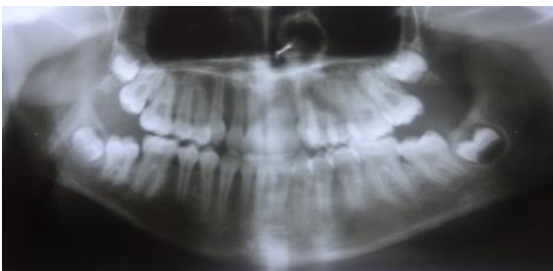


Figure 8: Post-operative OPG showing erupted permanent dentition

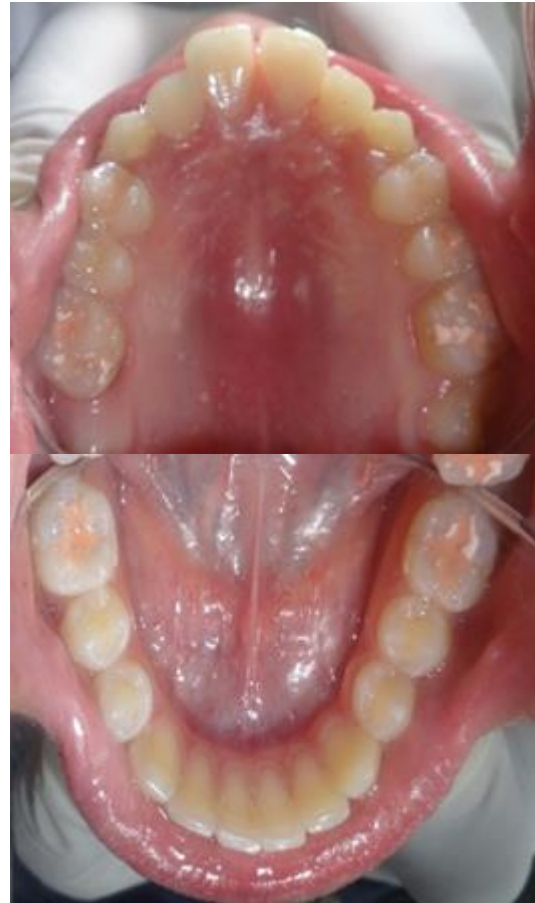

Figure 9: Upper and lower arches after full treatment

## DISCUSSION

The removable type space regainers use springs or screws incorporated in a Hawley's appliance. Distalisation of one teeth is achieved, with a longer span of treatment time and also they have the disadvantage of requiring patient compliance. Hence, it was decided to go for a fixed space regainer.

NiTi coils exhibit a long range of superelasticity with minimum load fluctuation despite large deflection due to excellent spring back and superelasticity.<sup>[6]</sup> Due to this property, it is possible to achieve large tooth movements without having to replace the springs.<sup>[7]</sup>

Approximately 1 mm per month distal movement has been reported for permanent first molars.<sup>8</sup> In the present case a space of 3 mm had been regained within the total treatment time of four months, and there was a need to change the springs twice within this treatment duration, which could be due to the fact that roots of permanent first molar were almost formed. For most children 7-10 years proves to be best for regaining lost arch space. This earlier distalisation has the advantage that the roots of the permanent first molar are incomplete, and orthodontic tipping or bodily movement is easier.<sup>[3]</sup> It is feasible to recover the lost space by distal movement of the permanent first molar by space

regainers which are broadly divided into fixed and removable type.

The removable type space regainers use springs or screws incorporated in a Hawley's appliance. Distalisation of one teeth is achieved, with a longer span of treatment time and also they have the disadvantage of requiring patient compliance. So a fixed space regainer was thought as an option for this patient. Also the maxillary arch from 14 to 26 was stabilised with the help of nance palatal arch. Advantages include simple and easy to fabricate, costeffective, fixed so minimal requirement of patient cooperation, serves the dual purpose of space regainer as well as space maintainer.

## CONCLUSION

The best space maintainer is the Gods gifted primary tooth. But when these natural space maintainers are lost, it becomes necessary to implement an appropriate space management strategy that can maintain the child's functional and esthetic well-being. If the patient doesn't report to the clinic on time then space loss occurs .These space regainers play an essential role in regaining the child's oral health back in these cases.

## REFERENCES

1. Damle SG. Space management. In: Textbook of pediatric dentistry. 4th edition. Aryamedi publishing house. Pg 341
2. Graber. Treatment of patients in the mixed dentition. In: Grabers Orthodontics current principles and techniques. 4th ed. Elsevier mosby publishers.2005 Pg 545.
3. Singh G. Interceptive orthodontic procedures. In: Textbook of orthodontics. 2nd ed. Jaypeebrothers medical publishers Pg 557-559.
4. Proffit W. Contemporary Orthodontics. 2nd Edition, Mosby Year Book: 380-383.
5. American Academy of Pediatric Dentistry. Guidelines on Management of the Developing Dentition and Occlusion in Pediatric Dentistry. AAPD ( Adopted 1990; Revised 1991, 1998, 2001, 2005, 2009, 2014).
6. Dean JA, McDonald RE, Avery DR. Managing the developing occlusion. Mcdonald and Avery's Dentistry for the Child and Adolescent, 9th edition, Elsevier MOSBY, Missouri 63043
7. Chalakka P, Thomas AM, Akkara F, Pavaskar R. New design space regainers: 'Lingual arch crossbow' and 'Double banded space regainer'. J Indian SocPedodPrev Dent 2012; 30 (2): 161-
8. Bondemark L, Karlsson I. Extraoralvs intraoral appliancefor distal movement of maxillary first molars: A randomized controlled trial. Angle Orthod 2005;75:699-706.

**Copyright:** © Annals of International Medical and Dental Research. It is an open-access article distributed under the terms of the Creative Commons Attribution Non-Commercial License, which permits unrestricted non-commercial use, distribution, and reproduction in any medium, provided the original work is properly cited.

**How to cite this article:** Uppal A, Singh R. Treatment of Mixed Dentition Space Loss with Double Banded Space Regainer and Quad Helix - A Case Report. Ann. Int. Med. Den. Res. 2020; 6(3):DE43-DE46.

**Source of Support:** Nil, **Conflict of Interest:** None declared