

# Evaluation of Removal of Gutta Percha Using Two Retreatment File System

Anuj Kumar Sharma<sup>1</sup>, Priya Pundir<sup>2</sup>, Prabhat Mandhotra<sup>3</sup>, Karma Sonam Bhutia<sup>4</sup>, Aman Abrol<sup>5</sup>, Shivani Parmar<sup>4</sup>

<sup>1</sup>Endodontist, Dr. YSPGMC Medical College and Hospital, Nahan, Distt Sirmour, Himachal Pradesh, India

<sup>2</sup>Senior Lecturer, Department of Conservative Dentistry and Endodontics, Seema Dental College And Hospital, Rishikesh, Uttarakhand, India

<sup>3</sup>Reader, Department of Conservative Dentistry and Endodontics, Himachal Dental College and Hospital, Sundernagar, Himachal Pradesh, India

<sup>4</sup>PG Student, Department Of Conservative Dentistry And Endodontics, Himachal Institute Of Dental Sciences, Paonta Sahib, Himachal Pradesh, India

<sup>5</sup>Endodontist, RPGMC Medical College And Hospital, Tanda, Distt Kangra, Himachal Pradesh, India

Received: June 2020

Accepted: June 2020

## ABSTRACT

**Background:** Enterococcus faecalis have been identified predominantly from the failed root canals. Retreatment requires complete removal of the root canal filling material, followed by further shaping, cleaning, disinfection and re-obturation to reestablish healthy periapical tissues. Removal of gutta-percha and sealer is an important factor in root canal retreatment since this enables thorough chemo-mechanical instrumentation and disinfection of the root canal system. Aim of the study: To evaluate the removal of gutta-percha using two retreatment file systems. **Methods:** The present study was conducted in the Department of Conservative Dentistry of the Dental institution. In the present study, we included 40 extracted mandibular premolars without any structural anomaly and carious lesions. The teeth were decoronated upto a length of 15 mm from the apex. Root canal therapy was performed followed by obturation with gutta-percha and sealer using cold lateral compaction technique. The retreatment in Group 1 was done with D-RaCe files and with Hedstrom files in Group 2. The evaluation of the remaining root canal filling material was done based on criteria described by Schirrmeister et al. **Results:** For teeth in Group 1, D-RaCe files were used and for Group 2, Hedstrom files were used. We observed that the area remaining root canal filling was comparatively higher in Group 2 teeth as compared to Group 1. **Conclusion:** Within the limitations of the present study, it can be concluded that D-RaCe files are more efficacious than Hedstrom files for the removal of root canal fillings.

**Keywords:** D-RaCe files, Hedstrom files, Retreatment, Gutta Percha Removal.

## INTRODUCTION

Enterococcus faecalis have been identified predominantly from the failed root canals. Retreatment requires complete removal of the root canal filling material, followed by further shaping, cleaning, disinfection and re-obturation to reestablish healthy periapical tissues.<sup>[1,2]</sup> Removal of gutta-percha and sealer is an important factor in root canal retreatment since this enables thorough chemo-mechanical instrumentation and disinfection of the root canal system.<sup>[3]</sup> Different techniques have been proposed to remove gutta-percha and sealer from root canals, including the use of hand files, nickel-titanium (NiTi) rotary instruments, and NiTi systems with reciprocating or adaptive motion.<sup>[4,5]</sup> It has been shown that automated NiTi instruments allow for safer and faster removal of filling material compared to manual techniques. Some NiTi systems specifically designed for retreatment purposes have physical characteristics such as cross-sectional

design, cutting angle, and presence/absence of an active tip that may affect gutta-percha and dentin removal from the root canal.<sup>[6]</sup> Hence, the present study was conducted to evaluate the removal of gutta-percha using two retreatment file system.

## MATERIALS AND METHODS

The present study was conducted in the Department of Conservative Dentistry of the Dental institution. The ethical clearance for the study was approved by the ethical committee of the hospital. In the present study, we included 40 extracted mandibular premolars without any structural anomaly and carious lesions. The teeth were decoronated upto a length of 15 mm from the apex. Root canal therapy was performed followed by obturation with gutta-percha and sealer using cold lateral compaction technique. All the specimens were divided broadly into two study groups, Group 1 and Group 2, with 20 specimens in each group as follows. The retreatment in Group 1 was done with D-RaCe files and with Hedstrom files in Group 2. The evaluation of the remaining root canal filling material was

### Name & Address of Corresponding Author

Dr. Priya Pundir  
Senior Lecturer,  
Department of Conservative Dentistry and Endodontics, Seema  
Dental College And Hospital, Rishikesh, Uttarakhand, India

done based on criteria described by Schirmer et al.<sup>[6]</sup>

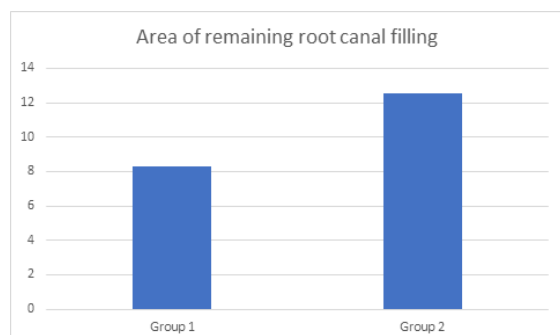
The statistical analysis of the data was done using SPSS version 11.0 for windows. Chi-square and Student's t-test were used for checking the significance of the data. A p-value of 0.05 and lesser was defined to be statistically significant.

## RESULTS

[Table 1] shows a comparison of the area of the remaining root canal filling after removal in Group 1 and 2. In both, the groups, removal of gutta-percha filling in root canals were done in 20 teeth. For teeth in Group 1, D-RaCe files were used and for Group 2, Hedstrom files were used. We observed that the area remaining root canal filling was comparatively higher in Group 2 teeth as compared to Group 1. The results were found to be statistically significant. ( $p < 0.05$ )

**Table 1: Comparison of an area of remaining root canal filling after removal in Group 1 and 2**

Groups	Area of remaining root canal filling	p-value
Group 1	8.33	0.14
Group 2	12.54	



**Figure 1: Comparative analysis of the remaining root canal filling after removal using instruments in Group 1 and Group 2**

## DISCUSSION

In the present study, we observed that D-RaCe files were more efficacious in the retreatment of endodontically treated teeth as compared to Hedstrom files. We observed that the area of root canal filling remained in the canal after attempting its removal was considerably more seen in Hedstrom files. Thus, D-RaCe files are more efficacious for the removal of gutta-percha filling from the root canals. The results were statistically significant and were found to be consistent with previous studies. Dadresanfar B et al compared the efficacy of two retreatment rotary systems in the removal of gutta-percha (GP) and sealer from the root canal walls with and without the use of solvent. Sixty single-canal distal roots of mandibular molars were prepared and root filled

with gutta-percha and AH26. Each canal was randomly allocated to receive one of the retreatment techniques, Mtwo R or ProTaper. The groups were further divided into two subgroups: with or without the use of solvent. The cleanliness of canal walls was determined by stereomicroscope and scanning electron microscopy. The results showed that Mtwo R without the use of solvent was more efficient in material removal compared to ProTaper D. Most remnants were found in the apical third of the canals. They concluded that Mtwo R seems to be an efficient rotary system for endodontic retreatment of the root canal with GP. Preetam CS et al evaluated the efficacy of the cleaning ability of two different rotary Ni-Ti systems; ProTaper Retreatment files and RaCe System compared to hand instrumentation with Hedstrom files for the removal of gutta-percha during retreatment. Thirty mandibular premolars with one single straight canal were decoronated and instrumented with ProTaper files and filled with thermoplastic gutta-percha. After 30 days, the samples were divided into three groups and gutta-percha was removed with the test instruments. The postoperative radiographs were evaluated with known criteria by dividing the root into cervical third, middle third, and apical third. The results were tabulated and the Statistical Package for Social Sciences Software (IBM Corporation) was used for analysis. The mean deviation of the results was first calculated and then the t-test and analysis of variance test (two-tailed P value) were evaluated for establishing significant differences. The rotary instruments were effective in removing the gutta-percha from the canals. Therefore, a significant difference was observed between the efficacies of the two rotary systems used. The rotary instruments showed effective gutta-percha removal in the cervical and middle one third. However, apical debridement was effective with Hedstrom files. The study concluded the use of both rotary and hand instrumentation for effective removal of gutta-percha for retreatment.<sup>[7,8]</sup>

Yadav P et al evaluated the efficacy of NiTi mechanical rotary instrumentation and Hedstrom file for gutta-percha/sealer removal computed tomography (CT) was utilized in vitro. Thirty extracted human single-rooted teeth, each with a single canal were selected. The samples were decoronated with a double-faced diamond disk to have 17-mm root; teeth roots were instrumented with K-files up to master apical file #30 using step-back technique. Samples were obturated using cold lateral condensation of gutta-percha and AH Plus root canal sealer. The teeth were then randomly divided into three groups of 10 specimens each. After 2 weeks 3-dimensional images of the roots were obtained by CT and the volume of root filling mass was measured. All the canals were then retreated by either the ProTaper retreatment files,

Mtwo retreatment files, or Hedstrom files. The canals were irrigated with 2 mL of 2.5% sodium hypochlorite irrigating solution during each change of instrument. The volume of remaining filling materials after the retreatment procedures were assessed by CT. Neither of the studied systems completely removed the root filling material. No significant difference was observed between the rotary systems. The volume of remaining filling materials was significantly less in rotary instrumentation than hand files. There was no significant difference for debris extruded from the apical foramen between the groups. They concluded that Mtwo and ProTaper retreatment files left less gutta-percha and sealer than H files; however, complete removal of filling materials was not achieved by the three systems investigated. Jayasenthil A et al evaluated the efficacy of two retreatments NiTi systems (protaper universal retreatment files, R-Endo), when compared to a manual technique in removing Gutta-percha obturated with two sealers. Study Design. Sixty extracted single-rooted premolars were instrumented with Protaper rotary files till F3. The specimens were divided into six groups. Groups 1, 2, 3 were obturated with Gutta-percha and zinc oxide eugenol and Groups 4, 5, 6 were obturated with Gutta-percha and AH-plus. The retreatment was carried out in groups 1 and 4 with H-files and GGdrills, groups 2 and 5 with R-endo retreatment files and groups 3 and 6 with Protaper retreatment files. The roots were sectioned and evaluated under an optical stereomicroscope. Statistical analysis was performed with one-way ANOVA and Newman-Keul's test at  $P < 0.05$ . Results. The manual technique resulted in cleaner canal walls when compared with both rotary retreatment systems. They concluded that NiTi rotary retreatment files can be used to remove the filling material quickly, but it should be followed by hand instruments to obtain better canal wall cleanliness.<sup>[9,10]</sup>

## CONCLUSION

Within the limitations of the present study, it can be concluded that D-RaCe files are more efficacious than Hedstrom files for the removal of root canal fillings.

## REFERENCES

1. Parekh B, Irani RS, Sathe S, Hegde V. Intraorifice sealing ability of different materials in endodontically treated teeth: an in vitro study. *J Conserv Dent*. 2014;17(3):234–37.
2. Slutzky-Goldberg I, Slutzky H, Gorfil C, Smidt A. Restoration of endodontically treated teeth review and treatment recommendations. *Int J Dent*. 2009;2009:150251.
3. Bueno CE, Delboni MG, deAraújo RA, Carrara HJ, Cunha RS. Effectiveness of rotary and hand files in gutta-percha and sealer removal using chloroform or chlorhexidine gel. *Braz Dent J*. 2006;17(2):139–43.

4. Keleş A, Arslan H, Kamalak A, Akçay M, Sousa-Neto MD, Versiani MA. Removal of filling materials from oval-shaped canals using laser irradiation: a micro-computed tomographic study. *J Endod*. 2015;41(2):219–24.
5. Yadav P, Bharath MJ, Sahadev CK, MakonahalliRamachandra PK, Rao Y, Ali A, Mohamed S. An in vitro CT Comparison of Gutta-Percha Removal with Two Rotary Systems and Hedstrom Files. *Iran Endod J*. 2013;8(2):59–64.
6. Schirrmeister JF1, Hermanns P, Meyer KM, Goetz F, Hellwig E. Detectability of residual Epiphany and guttapercha after root canal retreatment using a dental operating microscope and radiographs--an ex vivo study. *IntEndod J*. 2006 Jul;39(7):558-65.
7. Dadresanfar B, Mehrvarzfar P, Saghiri MA, Ghafari S, Khalilak Z, Vatanpour M. Efficacy of two rotary systems in removing gutta-percha and sealer from the root canal walls. *Iran Endod J*. 2011;6(2):69- 73.
8. Preetam CS, Chandrashekhar M, Gunaranjan T, Kumar SK, Miskeen Sahib SA, Kumar MS. A comparative evaluation of two rotary Ni-Ti instruments in the removal of gutta-percha during retreatment. *J IntSocPrev Community Dent*. 2016;6(Suppl 2):131- 136.
9. Yadav P, Bharath MJ, Sahadev CK, et al. An in vitro CT Comparison of Gutta-Percha Removal with Two Rotary Systems and Hedstrom Files. *Iran Endod J*. 2013;8(2):59- 64.
10. Jayasenthil A, Sathish ES, Prakash P. Evaluation of manual and two-rotary niti retreatment systems in removing gutta-percha obturated with two root canal sealers. *ISRN Dent*. 2012;2012:208241-208244.

**Copyright:** © Annals of International Medical and Dental Research. It is an open-access article distributed under the terms of the Creative Commons Attribution Non-Commercial License, which permits unrestricted non-commercial use, distribution, and reproduction in any medium provided the original work is properly cited.

**How to cite this article:** Sharma AK, PundirP, Mandhotra P, Bhutia KS, Abrol A, Parmar S. Evaluation of Removal of Gutta Percha Using Two Retreatment File System. *Ann. Int. Med. Den. Res*. 2020; 6(3):DE36-DE38.

**Source of Support:** Nil, **Conflict of Interest:** None declared