

Radiological Measurement of the Femoral Head Diameter: Male-Female Variations and Relationships with the Stature in Adult Bengali Bangladeshis

Md. Riadul Zannat Riad¹, Khalada Akter², Nahid Farhana Amin³

¹Resident, Department of Anatomy, Bangabandhu Sheikh Mujib Medical University, Dhaka, Bangladesh.

²Resident, Department of Physiology, Bangabandhu Sheikh Mujib Medical University, Dhaka, Bangladesh.

³Associate Professor, Department of Anatomy, Bangabandhu Sheikh Mujib Medical University, Dhaka, Bangladesh.

Received: October 2020

Accepted: December 2020

ABSTRACT

Background: Stature is an important parameter for the medical and nutritional assessment in living individuals, also in physical anthropometry and Forensic Medicine for personal identification along with age and race. The knowledge of the diameter of the femur head in both sexes not only helps the anatomists and forensic experts but also helps orthopaedic surgeons in hip replacement surgery. Most of the available orthopaedic implants have been designed and manufactured based on the data from western population, whose skeletal dimensions are different from those of Bengali Bangladeshi population. This research can be useful for designing orthopaedic implants considering constitutional and biomechanical factors of Bengali Bangladeshis. This study was aimed to measure the femoral head diameter (FHD) radiologically and to find out male-female variation and relationship with the stature. **Methods:** This was a cross-sectional study which involved measuring the FHD from the X-ray pelvis anterior-posterior views of adult patients reported "normal study" by the registered radiologist. A total of 200 femoral head were analyzed from 100 patients' radiographs comprising of 50 males and 50 females. **Results:** The average FHD for an adult Bengali Bangladeshi is 4.90 ± 0.40 cm. The mean value of the FHD for an adult male is 5.21 ± 0.26 cm whereas the mean value for an adult female is 4.58 ± 0.21 cm. Significant positive correlation was found between FHD and stature. **Conclusion:** Findings of the present study will provide baseline information regarding FHD and its correlation with stature in adult Bengali Bangladeshis.

Keywords: Bangladeshi, Bengali, Femoral head diameter, Radiological, Stature.

INTRODUCTION

The longest and strongest bone of the human body is femur.^[1] Femoral head diameter is one of the important values in sex differentiation.^[2] Femoral head mainly consists of cancellous bone, so is vulnerable to osteoporosis. An elderly person with severe osteoporosis is susceptible to proximal femur fracture.^[3] Forensic anthropologist use bone to determine the height of an individual.^[4] Stature or body height is one of the most important and useful anthropometric parameter that determine the physical identity of an individual and also essential for the medical and dietary evaluation in the living individual.^[5] Stature is one of the most essential indicators of body size and it depends on the length of a number of segments of the body such as skull, spine, pelvis, and lower limbs.^[6] There is a definite biological relationship of stature with all the body parts also with individual long and short bone.

Forensic scientist can calculate stature from mutilated or highly decomposed body parts by correlating stature with femoral head diameter.^[5]

MATERIALS AND METHODS

The study was carried out in the Department of Anatomy, Bangabandhu Sheikh Mujib Medical University (BSMMU), Dhaka, Bangladesh from March 2019 to February 2020. Data collection was done from the Department of Radiology and Imaging, BSMMU, after taking Institutional ethical clearance. The study was carried out on one hundred adult Bengali Bangladeshi individuals, fifty males and fifty females age ranging from 25 to 45 years who did X-ray pelvis in the Department of Radiology and Imaging, BSMMU.

The anteroposterior pelvic radiographs were made with the supine position on the X-ray table. These pelvic radiographs obtained using the standardize protocol. Both lower extremities oriented in 15° of internal rotation in order to maximize the length of the femoral neck.^[7] The X-ray tube-to-film distance was 120 cm, with the tube oriented perpendicular to the table.^[7-9] For this research, 100% digital X-ray of pelvis (anteroposterior view) was taken.

Name & Address of Corresponding Author

Md. Riadul Zannat Riad
Resident, Department of Anatomy,
Bangabandhu Sheikh Mujib Medical University,
Dhaka, Bangladesh.
Email: riadjmc11@gmail.com

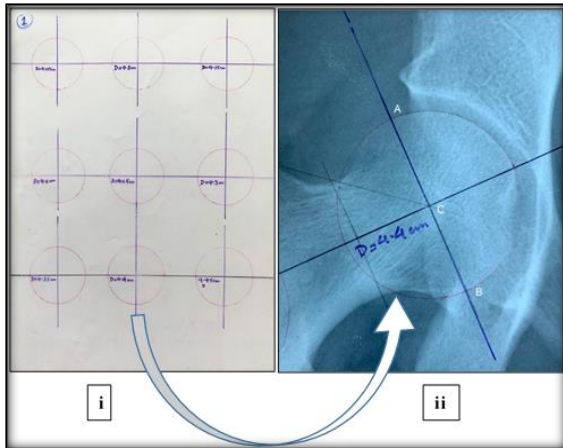


Figure 1: Identification of the femoral head centre i) Multiple circular template on a transparency sheet ii) Best matched template placed where 'C' represent the femoral head centre.

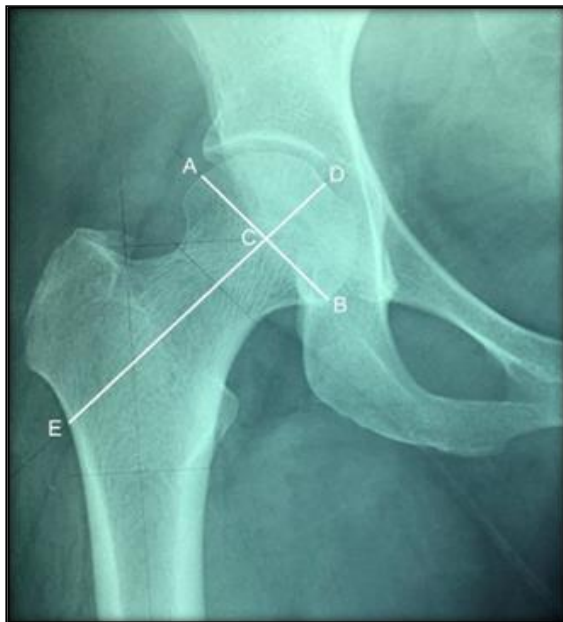

Figure 2: Femoral head diameter from point A to B, femoral neck axis from point D to E, centre of the femoral head C.

Procedure of measuring the stature: The participants were asked to stand with their heel together, toes apart and back as straight as possible. So that, their heels, buttocks, shoulders and the head touched the wall. The participants were requested to be barefooted and to remove any hair ornaments, jewellery, buns or braids. The participants' head was positioned in the Frankfort horizontal plane and the arms were hung freely by the sides with the palm facing towards the thighs. After taking a deep breath and holding it, a steel plate was placed against the head and this was marked by soluble marker. The stature was then measured from the floor to the marked point on the wall with a measuring steel tape.

Procedure of measuring the femoral head diameter: Measurements were taken after placing the X-ray

film on the view box. The femoral head is approximated as a sphere.^[10] The acetabulum and femoral head have a circular shape and have concentric articulation. Hence, the centres of the acetabulum and femoral head are the same point.^[11] The centre of the femoral head was identified by using circle templates. Firstly, the centre of the circle template was placed and slightly adjusted medially and laterally, simultaneously moved up and down referring to curves of femoral head to achieve the most appropriate circle template. Then, the centre of the femoral head was identified and marked as C [Figure 1].^[11-13] The femoral neck axis length DE [Figure 2] was drawn. A line AB was drawn perpendicular to DE through the centre of the femoral head C [Figure 2]. Femoral head diameter AB [Figure 2] and femoral neck axis length (DE) were measured by the digital slide callipers.

The range, mean and standard deviation of the FHD were calculated. Significance of the difference between the male and female values were tested by unpaired t- test. Distribution was tested by Shapiro-Wilk test. Correlations were tested between the stature and FHD by Pearson's correlation coefficient test, as the data were normally distributed. The data was entered into the software statistical package for social sciences (SPSS) version 25. In the interpretation of results ≤ 0.05 level of probability (p) was accepted as significant.

Ethical Clearance

This study was approved by Institutional Review Board of Bangabandhu Sheikh Mujib Medical University (BSMMU), Dhaka, Bangladesh.

RESULTS

A total of two hundred femoral head diameters were analysed from one hundred participants radiographs comprising of 50 males and 50 females. The age range was from 25 to 45 years (mean 33.47 ± 5.61 years). The mean FHD of males were found significantly higher than the females ($p < 0.05$) [Table 1, 2]. No significant difference was found between right and left FHD ($p = 0.841$) [Table 3]. The frequency distribution of the right and left femoral head diameter in males shows rightward tendency compared to that in the females [Figure 3]. Pearson's correlation coefficient test was done to see the correlations, as data was normally distributed. Correlations of the stature with FHD were assessed and displayed using scatter diagrams. FHD in both sexes showed significant positive correlations ($r = +0.333$, $r = 0.291$, $r = 0.690$, $p = 0.001$) with the stature [Table 4 and Figure 5-7].

Table 1: Femoral head diameter (cm) in males and females

	N	Minimum	Maximum	Mean	SD	P value
Male	100	4.61	5.86	5.21	0.26	0.001
Female	100	4.21	5.27	4.58	0.21	
Total	200	4.21	5.86	4.90	0.40	

p ≤ 0.05 was considered as significant

Table 2: Bilateral variations of the femoral head diameter (cm) in males and females

		N	Minimum	Maximum	Mean	SD	P value
Right	Male	50	4.67	5.86	5.22	0.26	0.001
	Female	50	4.23	5.27	4.59	0.21	
Left	Male	50	4.61	5.81	5.21	0.56	0.001
	Female	50	4.21	5.23	4.57	0.22	

P ≤ 0.05 was considered as significant

Table 3: Bilateral variations of the femoral head diameter (cm)

	N	Minimum	Maximum	Mean	SD	P value
Right	100	4.23	5.86	4.90	0.39	0.841
Left	100	4.21	5.81	4.89	0.40	

P ≤ 0.05 was considered as significant

Table 4: Correlation coefficient of the stature with the femoral head diameter in adult Bengali Bangladeshis

	N	Correlation coefficient (r)	Coefficient of determination (r ²)	P value
Male	100	+0.577	0.333	0.001
Female	100	+0.539	0.291	0.001
Total	200	+0.831	0.690	0.001

P ≤ 0.05, was considered as significant

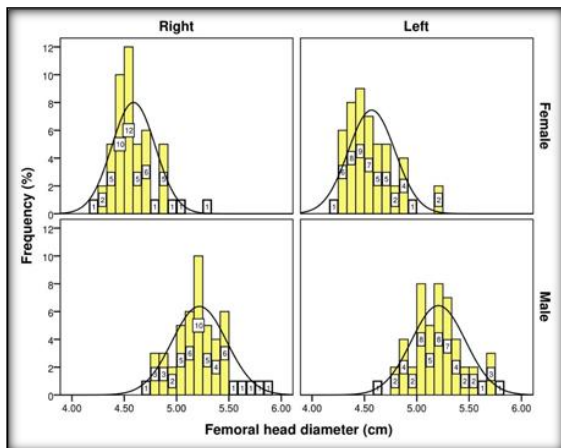


Figure 3: Frequency distribution of the FHD

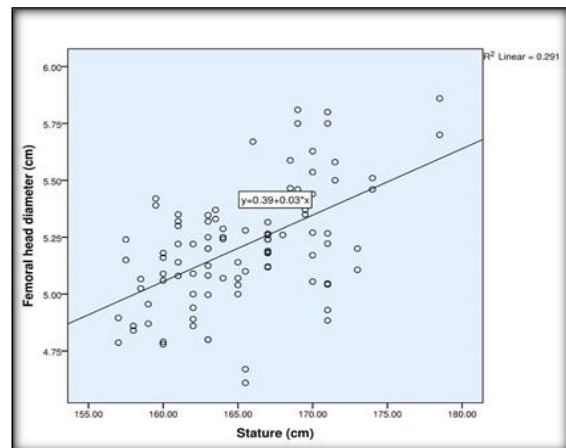


Figure 5: Correlation between the FHD and stature in males in regression analysis.

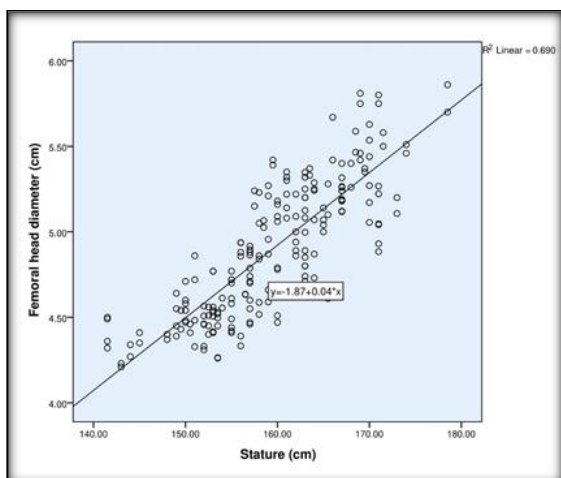


Figure 4: Correlation between the FHD and stature in adult Bengali Bangladeshis in regression analysis.

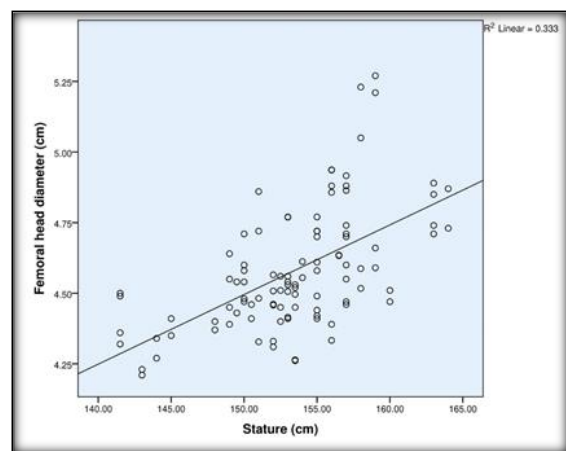


Figure 6: Correlation between the FHD and stature in females in regression analysis.

DISCUSSION

In the present study, the average femoral head diameter was 5.21 cm and 4.58 cm in male and female respectively. A statistically significant difference was detected in FHD between males and females ($P < 0.05$). Acar et al,^[14] in Turkish population, Caiaffo et al,^[15] in Brazilian population, Harris et al,^[16] in American population also found statistically significant difference between male & female FHD.

In the present study, overall femoral head diameter in Bengali Bangladeshi population was found 4.90 cm. Siwach,^[17] in an anthropometric study on X-ray of dry femora demonstrated that the average femoral head diameter in Indian population was 4.353 cm, whereas Nobel PC et al,^[18] on radiological osteometric measurements on dry femora in Caucasians demonstrated the average femoral head diameter was 4.61 cm. The difference with the present study may be due to the more magnification error in living body.

However, in this study general aspect of both genders right and left femoral head diameters were 4.90 cm and 4.89 cm respectively, no significant difference was observed between right and left femoral head diameter ($P = 0.841$), which is consistent with the observation was reported in Brazilian and Indian population.^[19,20] Kamdi, Karoe & Saritha,^[21] observed there is a small difference in between the femoral head diameter of two sides in the same individuals but that is statistically insignificant.

From the present study it was revealed that the femoral head diameter of males Bengali Bangladeshis is significantly greater ($P < 0.05$) than the corresponding diameters of the female. This suggests that femoral head diameters are of value in sex differentiation. The values of FHD of the present study were smaller than the Nigerians and nearer to that of the Indians.^[2,21] Nigerians are taller than average Indians; That might be the reason of having bigger FHD than that of Indians and Bangladeshi people. Femoral head diameter and male-female variation of the present study was found almost similar with the study of Afroz & Huda,^[22] on the population of the northern zone of Bangladesh.

Many studies had focused on the femoral head diameter for different ethnic populations. There are several possible reasons for the differences between the results of this study with others. These include inter observer error and differences in sample size, the mean age of the sample, ancestry, selection criteria, and methods used to obtain the femoral head diameter.

In the present study, the femoral head diameter which was measured from X-ray pelvis was significantly positively correlated with the stature which is consistent with the observation that was

reported by Giroux et al and Nissen et al in American and Dutch population respectively.^[23,24]

CONCLUSION

There was a significant difference found in FHD between males and females. Significant positive correlations were found between the stature and femoral head diameter, in both sexes.

REFERENCES

- Adekoya-Cole TO, Akinmokun OI, Soyebi KO, Oguche OE. Femoral neck shaft angles: A radiological anthropometry study. Niger Postgrad Med J. 2016;23(1):17-20.
- Asala S, Mbajiorgu F, Papandro B. A comparative study of femoral head diameters and sex differentiation in Nigerians. Cells Tissues Organs. 1998;162(4):232-237.
- Lv L, Meng G, Gong H, Zhu D, Zhu W. A new method for the measurement and analysis of three-dimensional morphological parameters of proximal male femur. Biomed Res. 2012; 23(2):219-226.
- Karaman A, Teke H, Günay I, Dogan B, Bilge Y. Height estimation using anthropometric measurements on X-rays of wrist and metacarpal bones. Internet J Biol Anthropol. 2008;2(1):1-22.
- Bakar SA, Alias A, Ibrahim A, Abdullah N, Judi MS, et al. Stature Estimation from Lower Limb Anthropometry using Linear Regression Analysis: A Study on the Malaysian Population. Clin Ter. 2017;168(2):84-87.
- AlQahtani F. Prediction of stature from radiographic study of foot and hand in modern Saudi at Baha Province. Int J Med Sci Public Health. 2015;4(8):1035.
- Clohisey JC, Carlisle JC, Beaulé PE, Kim YJ, Trousdale RT, Sierra RJ, et al. A systematic approach to the plain radiographic evaluation of the young adult hip. J Bone Joint Surg Am. 2008;90 Suppl 4:47-66.
- Tannast M, Murphy SB, Langlotz F, Anderson SE, Siebenrock KA. Estimation of pelvic tilt on anteroposterior X-rays—a comparison of six parameters. Skeletal Radiol. 2006;35(3):149-155.
- Polesello GC, Nakao TS, de Queiroz MC, Daniachi D, Riccioli W. Proposal for standardization of radiographic studies on the hip and pelvis. Rev Bras Ortop. 2011;46(6):634.
- Subburaj K, Ravi B, Agarwal M. Computer-aided methods for assessing lower limb deformities in orthopaedic surgery planning. Comput Med Imaging Graph. 2010;34(4):277-288.
- Harnroongroj T, Suangyanon P, Tharmviboonsri T, Harnroongroj T. Posterior acetabular arc angle of the femoral head assesses instability of posterior fracture-dislocation of the hip. Int Orthop. 2013;37(6):1141-1145.
- Sugano N, Noble PC, Kamaric E. Predicting the position of the femoral head center. The Journal of Arthroplasty. 1999;14(1):102-107.
- Meermans G, Malik A, Witt J, Haddad F. Preoperative radiographic assessment of limb-length discrepancy in total hip arthroplasty. Clin. Orthop. Relat. Res. 2011;469(6):1677-1682.
- Acar N, Unal M. Radiological Evaluation of the Proximal Femoral Geometric Features in the Turkish Population. SDÜ Týp Fakültesi Dergisi. 2017;24(4):127-134.
- Caiaffo V, de Albuquerque PPF, de Albuquerque PV, de Oliveira BDR. Sexual Diagnosis Through Morphometric Evaluation of the Proximal Femur. J Morphol. 2019;37(2).
- Harris JD, Gerrie BJ, Varner KE, Lintner DM, McCulloch PC. Radiographic Prevalence of Dysplasia, Cam, and Pincer

- Deformities in Elite Ballet. Am J Sports Med. 2016;44(1):20- 27.
17. Siwach R. Anthropometric study of proximal femur geometry and its clinical application. Ann Natl Acad Med Sci. 2018;54(04):203-215.
 18. Noble PC, Alexander JW, Lindahl LJ, Yew DT, Granberry WM, Tullos HS. The anatomic basis of femoral component design. Clin. Orthop. Relat. Res. 1988;235:148-165.
 19. De Sousa E, Fernandes RMP, Mathias MB, Rodrigues MR, Ambram AJ, Babinski MA. Morphometric study of the proximal femur extremity in Brazilians. Int J Morphol. 2010;28(3):835-840.
 20. Otađ Ý, Otađ A, Akkoyun S, Çimen M. Estimation of the femur length from its proximal measurements in Anatolian Caucasians by artificial neural networks. Australian Journal of Forensic Sciences. 2015;48(3):279-286.
 21. Kamdi A, Kaore A, Saritha S. Study of Vertical Diameter of Head of Femur in South Indian Cadavers. International Journal of Anatomy and Research. 2016;4(3.2):2730-2733.
 22. Afroze A, Huda MD. Femoral head diameters and sex differentiation in the northern zone (Rajshahi) of Bangladesh. TAJ: Journal of Teachers Association. 2005;18(2):84-88.
 23. Giroux CL, Wescott DJ. Stature estimation based on dimensions of the bony pelvis and proximal femur. J Forensic Sci. 2008;53(1):65-68.
 24. Nissen N, Hauge EM, Abrahamsen B, Jensen JE, Mosekilde L, Brixen K. Geometry of the proximal femur in relation to age and sex: a cross-sectional study in healthy adult Danes. Acta Radiol. 2005;46(5):514-518.

Copyright: © the author(s), 2020. It is an open-access article distributed under the terms of the Creative Commons Attribution License (CC BY 4.0), which permits authors to retain ownership of the copyright for their content, and allow anyone to download, reuse, reprint, modify, distribute and/or copy the content as long as the original authors and source are cited.

How to cite this article: Riad RZ, Akter K, Amin NF. Radiological Measurement of the Femoral Head Diameter: Male-Female Variations and Relationships with the Stature in Adult Bengali Bangladeshis. Ann. Int. Med. Den. Res. 2021; 7(2):AT01-AT05.