

Morphometry of Foramen Magnum and its Association with other Cranial Parameters in Adult Human Dried Skulls with Their Clinical Significance in Indian Population

Ankit Khandelwal¹, Vasundhara Kulshreshtha², Pooja Rani³

¹Assistant Professor, Department of Anatomy, GS Medical College and Hospital, NH 24, Pilkhuwa, Hapur (Up), India.

²Professor and Head of Department, Department of Anatomy, S. N. Medical College, Agra, (UP), India

³Associate Professor, Department of anatomy, Pt. B.D.Sharma, Post Graduate Institute of Medical Sciences, Rohtak, Haryana, India

Received: July 2020

Accepted: July 2020

ABSTRACT

Background: The foramen magnum acts as a transition zone between spine and skull and plays an important role as a landmark because of its close relationship to important structures such as the brain and spinal cord. Due to the presence of vital structures in the vicinity and various surgical approaches being practiced during neuro-vascular surgeries, morphometry of foramen magnum becomes important. **Objective:** The present study was thus undertaken to estimate morphometry of Foramen magnum and its association with other cranial parameters in dried human skulls in Indian population. **Methods:** A total of 100 dried human skulls (50 male and 50 female) were included in the study. Various cephalometric parameters including foramen magnum length, foramen magnum surface area, cranial length, cranial breadth and cranial height in male and female skulls were recorded using sliding caliper and blunt end spreading caliper, clay and graph paper and statistically evaluated. **Results:** Mean and SD of foramen magnum length in male skulls was found to be 3.48 ± 0.273 cm and in female skulls was 3.39 ± 0.224 cm; Mean and SD of foramen magnum area in male skulls was noted 694.94 ± 96.275 mm² and in female skulls was 652.20 ± 74.415 mm². **Conclusion:** The results of this study highlight the racial and gender differences in morphometry of Foramen magnum in Indian population. These dimensions will provide a baseline standard value for parameters in Indian population and will be of utmost importance to neurosurgeons, forensic experts in medico-legal cases and to the anthropologists.

Keywords: Morphometry, Foramen Magnum length, Foramen magnum surface area, Indian Population.

INTRODUCTION

Foramen magnum (FM) is the largest foramen in the skull. It lies in anteromedian plain and communicates the posterior cranial fossa with the vertebral canal. It is oval in shape present in the occipital bone, wider behind than in front, as its anterolateral margins are encroached by occipital condyles. It contains the lower end of the medulla oblongata, meninges, vertebral arteries, and the spinal accessory nerve.^[1]

The foramen magnum has three parts: a squamosal part located behind the foramen magnum; a basal (clival) portion located anterior to the foramen magnum; and a condylar part that connects the squamosal and clival parts.^[2]

The dimensions of Foramen magnum are specific for a particular population. and morphometry of foramen magnum and occipital bone, when used

together serve as a good indicators for the determination of sex.^[3]

Base of the skull is covered by large mass of soft tissue which helps to protect the foramen magnum. So, in cases of severe trauma or explosions, an intact foramen magnum is mostly obtained. Morphometry helps in determining the gender and consequent identification of a person. Thus, morphometry of foramen magnum becomes important as measurements of various bones are often used during forensic and anthropological investigations of unknown individuals for estimation of age, gender, stature, and ethnicity.^[4] The present study was thus designed to deliver a data of morphometry of foramen magnum that can be used as a diagnostic tool in various cranial diseases as well as serving as a useful tool in medico-legal and anthropological cases in Indian population.

MATERIALS AND METHODS

Experimental design:

The present study was conducted on 100 dried human skulls (50 male and 50 female). of Indian origin, in the Department of Anatomy, S.N. Medical college, Agra.

Name & Address of Corresponding Author

Dr. Pooja Rani,
Associate Professor,
Department of Anatomy,
Pt. B.D.Sharma, Post Graduate Institute of
Medical Sciences,
Rohtak, Haryana, India
Email: drpooja0912@yahoo.com

Materials used

100 human dried skulls (50 male and 50 female), Blunt end spreading caliper, Sliding Vernier caliper, Flexible clay material and Graph paper sheets

Exclusion criterion:

Dry human skulls showing gross deformity, asymmetry or partially broken skulls were excluded from the present study.

Ethical approval:

All procedures performed in the study involving dry human skull were in accordance with the ethical standards of the institutional research committee. The study was approved by Bioethics committee of S.N. Medical College, Agra, India.

Methodology:

All the measurements were taken with the help of sliding caliper and blunt end spreading caliper and the readings were recorded three times and the mean taken for further computation. For collecting measurements, the two arms of the instrument were held by two ends in such a manner that the curved portions remain in between middle finger and the thumb.

Measurements:

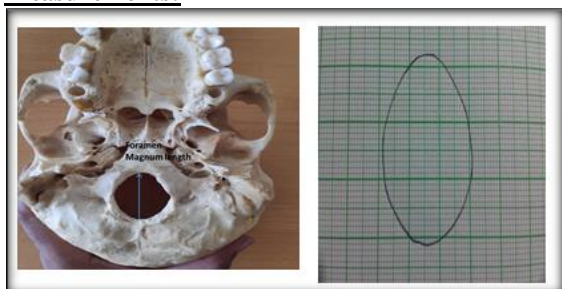


Figure 1: Depicting the method of obtaining foramen length and surface area

Various measurements taken were:

- 1) Maximum cranial length: measured from glabella(space between two superciliary ridges) to inion(most projecting point of the occipital bone on the base of skull).
- 2) Maximum cranial breadth: measured between two most lateral points on parietal bones.
- 3) Maximum cranial height: measured between basion (mid point of the anterior margin of the rim of foramen magnum) and bregma (junction of coronal and sagittal sutures).

- 4) Foramen magnum length (Antero-Posterior Diameter= APD): measured between two farthest points anteroposteriorly on foramen magnum.
- 5) Surface area of foramen magnum: Surface area of foramen magnum was calculated on graph paper sheets with the help of clay material. The impressions of the margins of foramen magnum were taken on clay material by pressing it on the foramen from outside which was then drawn on graph paper sheets with the help of which the surface area of foramen magnum was computed by counting the number of small squares on the graph paper sheets.

Statistical analysis:

Results were expressed as mean ± SD and analyzed using the Statistical Package for Social Sciences (SPSS), 15th version. A comparison of the mean values and proportions between sexes was performed using the t-test and Z-test respectively.

RESULTS

The results of the present study are summarized in the tables below.

Correlation of Parameters with Each Other

The cranial parameters were statistically correlated with each other and the following observations were elucidated.

[Table 2] shows that Correlation between cranial length and foramen magnum length in male, female and combined skulls was found to be statistically insignificant (p>0.05). Correlation between cranial length and surface area of foramen magnum in male, female and combined skulls showed that the two parameters did not correlated well with each other and there correlation is statistically shown to be insignificant (p>0.05).

Correlation between cranial breadth and area covered by foramen magnum in male and combined skulls was found to be insignificant (p>0.05) though in female skulls was found to be significant. This information can be used in living beings as we can easily take the readings of cranial length and breadth in them which can be used to predict surface area of foramen magnum.

Table 1: Statistical evaluation of cranial parameters (cm)

Cranial Length (CL)		S.S.*	Min.	Max.	Sum	Mean	S.D.**
Cranial Length (CL)	Males	50	15.1	19.4	884.9	17.698	0.788
	Females	50	15	18	849.4	16.988	0.726
	Total	100	15	19.4	1734.3	17.343	0.8367
Cranial Breadth (CB)	Males	50	11.8	14	637.3	12.746	0.563
	Females	50	11.8	13.9	631.3	12.626	0.537
	Total	100	11.8	13.9	1268.6	12.686	0.5537
Cranial Height (CH)	Males	50	11.4	14	660.8	13.216	0.57
	Females	50	11.4	13.7	633.7	12.674	0.489
	Total	100	11.4	14	1294.6	12.95	0.5945

Table 2: showing correlation of parameters with each other

Males	S.S.*	Min.	Max.	Sum	Mean	S.D.**	r***	'p' value	Significance
Cranial Length	50	15.1	19.4	884.9	17.698	0.7875	0.1349	>0.05	Insignificant
Foramen Magnum Length	50	2.74	4.05	173.99	3.4798	0.2739			
Females	S.S.*	Min.	Max.	Sum	Mean	S.D.**	r***	'p' value	Significance
Cranial Length	50	15	18	849.4	16.988	0.726	0.0533	>0.05	Insignificant
Foramen Magnum Length	50	2.87	4.15	169.6	3.392	0.227			
Males	S.S.*	Min.	Max.	Sum	Mean	S.D.**	r***	'p' value	Significance
Cranial Length	50	15.1	19.4	884.9	17.698	0.788	0.1474	>0.05	Insignificant
Foramen Magnum Area	50	442	987	34747	694.94	96.28			
Female	S.S.*	Min.	Max.	Sum	Mean	S.D.**	r***	'p' value	Significance
Cranial Length	50	15	18	849.4	16.988	0.726	0.00038	>0.05	Insignificant
Foramen Magnum Area	50	411	823	32610	652.2	74.42			
Male	S.S.*	Min.	Max.	Sum	Mean	S.D.**	r***	'p' value	Significance
Cranial Breadth	50	11.8	14	637.3	12.746	0.5633	0.1526	>0.05	Insignificant
Foramen Magnum Area	50	442	987	34747	694.94	96.27			
Females	S.S.*	Min.	Max.	Sum	Mean	S.D.**	r***	'p' value	Significance
Cranial Breadth	50	11.8	13.9	631.3	12.626	0.537	0.705	<0.001	Significant
Foramen Magnum Area	50	411	823	32610	652.2	74.42			

*S.S.=Sample size ; **S.D.=Standard deviation ;*** r = correlation coefficient

Table 3: Showing the Statistical Evaluation of Foramen Magnum Length (Cm) and surface area

Foramen magnum length	S.S.*	Min.	Max.	Sum	Mean	S.D.**
Males	50	2.74	4.05	174.1	3.48	0.273
Females	50	2.87	4.15	169.73	3.39	0.224
Total	100	2.74	4.15	343.8	3.438	0.2536
Foramen Magnum Surface Area						
Males	50	442	987	34747	694.94	96.275
Females	50	411	823	32610	652.20	74.415
Total	100	411	987	67357	673.57	88.656

*S.S.=Sample size ; **S.D.=Standard deviation

Foramen Magnum Length And Surface Area [Table 3].

In the present study, the length and surface area of foramen magnum in all 50 male and 50 female skulls were calculated. The readings came out to [Table 3].

In the present study, the mean foramen magnum length in males is found to be larger than in female skulls and the mean surface area of foramen magnum in males is also larger than in female skulls. This could be attributed to the larger skull dimensions in males as compared to females. Foramen magnum length or APD of the male skulls in the present study of the Indian population was 3.48 ± 0.273 lower than the Brazilian male skulls (3.57 ± 0.29),^[5] Turkish (3.72 ± 3.43),^[6] Spanish (3.62 ± 0.3),^[7] English populations (3.591 ± 2.41).^[8] Foramen magnum length or APD of the female skulls in the present study of the Indian population was 3.39 ± 0.224 lower than Brazilian population (3.51 ± 0.33),^[5] than those of the Turkish (3.46 ± 3.16),^[6] Spanish (3.430 ± 0) and English populations (3.471 ± 1.91).^[7,8]

The values of Mean and SD of foramen magnum area in male skulls were 694.94 ± 96.275 mm² (Range: 442 – 987mm²) and in female skulls were 652.20 ± 74.415 mm² (Range: 411 – 823mm²) respectively. Mean and SD of foramen magnum area in total (combined male and female) skulls was found to be 673.57 ± 88.656 mm² (Range: 411 – 987 mm²). Tubbs et al in a study on Seventy-two dry skulls found that the mean surface area of the foramen magnum was 558 mm² compared to

673.57 mm² found in present study, the mean anteroposterior diameter was 3.1 cm compared to 3.438 ± 0.2536 cm in present study.^[9]

DISCUSSION

Development of a particular shape of the FM is explained on the basis of the embryologic data. It may be caused due to ossification of primordial cranial residues, which join the endochondral ossification points in different locations, resulting in various shapes.^[10] Irregular shape of FM is accentuated by the developmental anomalies of the bone and soft tissues at the craniovertebral junction.^[11]

The foramen magnum as a transition zone between spine and skull plays an important role as a landmark because of its close relationship to important structures such as the brain and spinal cord.^[12] The Foramen magnum carries a great importance in the lateral approaches due to its localization in skull base region. The anterolateral aspect of the FM is one of the deepest and most complex areas of the skull base. A significant surgical challenge for neurosurgeons is there in exposure of intra or extradural lesions involving the FM and brainstem poses since the foramen is covered by thick bony prominences where many nerves and vascular structures pass through.^[13] Shape and size of the foramen magnum are important parameters for the manifestation of clinical signs and symptoms in craniocervical pathology including motor myelopathy, sensory

abnormalities, brainstem and lower cranial nerve dysfunctions, and signs and symptoms referable to vascular compromise. Irregular geometry of the foramen magnum and related structures is associated with anomalies and malformations of the occipital sclerotomes. Diseases associated with anomalies of the foramen magnum include occipital vertebra, basilar invagination, condylar hypoplasia, and atlas assimilation.^[9]

Herniation of cerebellar tissue into the foramen magnum, commonly referred to as tonsillar herniations, may cause neural compression and may compress the medulla and be so severe that the herniated tissue undergoes necrosis. Chronic herniation is seen with the Arnold Chiari malformation.^[14,15]

CONCLUSION

The findings of the present study demonstrated the existence of sexual dimorphism in the foramen magnum. Metric analysis of the foramen magnum may provide a statistically useful indication as to sex of the unknown skull in incomplete skeletons. The cephalometry could also be applied on living subjects and, thereby, our findings could provide data to evaluate the etiology of certain clinical conditions like Arnold Chiari malformation for living subjects. Thus the present study proves to be useful to forensic experts, neurosurgeons and anthropologists dealing with Indian population.

REFERENCES

1. Standring S, Borely NR, Collins P, Crossman AR, Gatzoulis MA, Healy JC. *Grays Anatomy, Anatomical Basis of Clinical Practice*, Churchill Livingstone, UK, 40th edition, 2008.
2. Albert L. Rhoton Jr., Foramen Magnum, *Neurosurgery*. 2000; 47(3):155-193.
3. Galdames ICS, Russo PP, Matamala DAZ, Smith RL. Sexual dimorphism in the foramen magnum dimensions. *International Journal of Morphology*. 2009;27(1):21–23, 2009.
4. Manoel CC, Prado FB, Caria PHF, Groppo FC. Morphometric analysis of the foramen magnum in human skulls of Brazilian individuals: Its relation to gender. *Brazilian Journal of Morphological Sciences*. 2009;26(2):104–108.
5. Manoel C, Prado FB, Caria PHF, Groppo FC. Morphometric analysis of the foramen magnum in human skulls of Brazilian individuals: its relation to gender. *Braz. J. Morphol. Sci* 2009; 26(2): 104-108
6. Murshed KA, Çiçekçibasi AE, Tuncer I. Morphometric Evaluation of the Foramen Magnum and Variations in its Shape: A Study on Computerized Tomographic Images of Normal Adults. *Turkish Journal of Medical Sciences*. 2003; 33(1): 301-306.
7. Herrera CJC. Study of the anatomic metric values of the foramen magnum and its relation to sex. *Acta Anatomica*. 1987; 130: 344-347.
8. Gapert R, Black S, Last J. Sex determination from the foramen magnum: discriminant function analysis in an eighteenth and nineteenth century British sample.

- International Journal of Legal Medicine. 2008; 123(1): 25-33.
9. R. S. Tubbs, C. J. Griessenauer, M. Loukas, M. M. Shoja, and A. A. Cohen-Gadol, "Morphometric analysis of the foramen magnum: Anatomic study. *Neurosurgery*. 2010; 66(2):385–388.
10. Govsa F, Ozer MA, Celik S, Ozmutaf NM. Threedimensional anatomic landmarks of the foramen magnum for the craniovertebral junction. *J Craniofacial Surg*. 2011;22(3): 1073–1076.
11. Chethan P, Prakash KG, Murlimanju BV. Morphological analysis and morphometry of the foramen Magnum: An anatomical investigation. *Turkish Neurosurgery*. 2012;22(4): 416–419.
12. Gruber P, Henneberg M, Bo'ni T, R'uhli FJ. Variability of human foramen magnum size. *Anatomical Record*. 2009; 292(11):1713–1719.
13. Avci E, Dagtekin A, Ozturketal AH. Anatomical variations of the foramen magnum, occipital condyle and jugular tubercle. *Turkish Neurosurgery*. 2011; 21(2):181–190.
14. Friede RL, Roessmann U: Chronic tonsillar herniation: An attempt at classifying chronic herniations at the foramen magnum. *Acta Neuropathol (Berl)*. 1076;34:219–235.
15. Russell DS, Rubinstein LJ: *Pathology of Tumors of the Nervous System*. Baltimore, Williams & Wilkins, 1977, ed 4, p 368.

Copyright: © Annals of International Medical and Dental Research (AIMDR). It is an open-access article distributed under the terms of the Creative Commons Attribution Non-Commercial License, which permits unrestricted non-commercial use, distribution, and reproduction in any medium, provided the original work is properly cited.

How to cite this article: Khandelwal A, Kulshreshtha V, Rani P. Morphometry of Foramen Magnum and its Association with other Cranial Parameters in Adult Human Dried Skulls with Their Clinical Significance in Indian Population. *Ann. Int. Med. Den. Res*. 2020; 6(5):AT01-AT04.