

## A Comparative Study of Circumferential Subannular Technique versus Conventional Underlay Technique in Chronic Otitis Media

Saloni Sinha<sup>1\*</sup>

<sup>1</sup>Assistant Professor, Department of ENT, World College of Medical Sciences, Gurwar, Jhajjar, Haryana, India.

\*Corresponding author

Received: December 2020

Accepted: January 2021

### Abstract

**Background:** Chronic otitis media with perforation of the tympanic membrane is a common cause of hearing loss and ear discharge. The present study was conducted to compare circumferential subannular technique versus conventional underlay technique in Chronic Otitis Media. **Methods:** 50 cases of chronic suppurative otitis media were divided into 2 groups of 25 each. Group I were treated with circumferential subannular technique and group II were treated with conventional underlay technique. **Results:** The mean pre- op PTA was 36.2 db and post op PTA was 25.4 db in group I and 37.4 and 30.1 in group II. The difference was significant ( $P < 0.05$ ). **Conclusion:** Circumferential grafting technique is superior in postoperative hearing improvement.

**Keywords:** Circumferential Grafting Technique, Hearing, Overlay.

### INTRODUCTION

Chronic otitis media (COM) has been an important cause of middle ear disease. The prevalence of COM in India and different countries of Africa were in between 2 and 17% among children. Chronic otitis media is still alarming in our country and day to day practical experience. Poor living condition, overcrowding, poor hygiene, malnutrition and inadequate health care all have been suggested as a basis for the widespread prevalence of chronic otitis media in our country it is the single most cause of hearing impairment in our rural population.<sup>[1]</sup> The main purposes of chronic otitis media surgery are to achieve intact

tympanic membrane, a middle ear cavity lined with normal mucosa and to improve the hearing.<sup>[2]</sup> There are two established techniques of myringoplasty, overlay technique and underlay technique. In overlay technique we place the graft lateral to the fibrous layer of the tympanic membrane. In underlay technique we place the graft medial to the tympanic membrane remnant. Underlay technique is the most common and time tested technique, is typically used for posterior perforations, whereas the overlay technique is more technically challenging and particularly suited for anterior large or subtotal perforations.<sup>[3]</sup>

Chronic otitis media with perforation of the tympanic membrane is a common cause of hearing loss and ear discharge. There are two popular surgical techniques, the underlay and overlay methods for tympanoplasty.<sup>[4]</sup> The underlay technique is quicker and easier to perform, and the creation of a tympano-meatal flap with elevation of the annulus allows inspection of the ossicular chain. However, there is a risk of medial displacement of the graft, especially in large and/or anterior perforations. The overlay technique avoids this pitfall, but there is a risk of keratin pearl formation within the tympanic membrane, and also a risk of blunting of the angle between the drum and the anterior meatal wall.<sup>[5]</sup> The present study was conducted to compare circumferential subannular technique versus conventional underlay technique in Chronic Otitis Media.

### MATERIALS AND METHODS

The present study was conducted among 50 cases of chronic suppurative otitis media (CSOM) of both genders. All were informed regarding the study and their consent was obtained.

Data such as name, age, gender etc. was recorded. Patients were divided into 2 groups of 25 each. Group I were treated with circumferential subannular technique and group II were treated with conventional underlay technique. Results thus obtained were subjected to statistical analysis. P value < 0.05 was considered significant.

### RESULTS

[Table 1] shows that group I had 15 males and 10 females and group II had 12 males and 13 females.

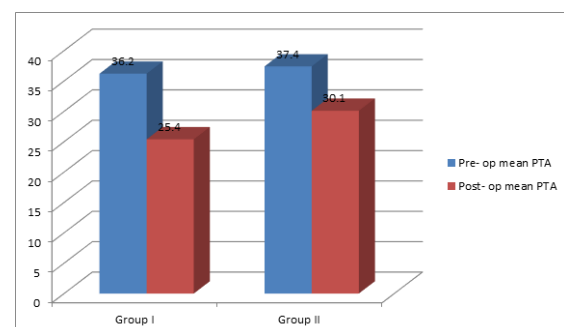
**Table 1: Distribution of patients**

Groups	Group I	Group II
Technique	Circumferential subannular technique	Conventional underlay technique
M:F	15:10	12:13

**Table 2: Improvement in hearing in both groups**

Groups	Pre-op mean PTA	Post-op mean PTA	P value
Group I	36.2	25.4	0.01
Group II	37.4	30.1	0.05

[Table 2, Figure 1] shows that mean pre-op PTA was 36.2 db and post op PTA was 25.4 db in group I and 37.4 and 30.1 in group II. The difference was significant (P< 0.05).



**Figure 1: Improvement in hearing in both groups**

## DISCUSSION

Perforation of the tympanic membrane primarily results from middle ear infections, trauma or iatrogenic causes. Up to 80% of these perforations heal spontaneously for the remaining, surgical repair, known as myringoplasty, is usually proposed. Myringoplasty was further developed by Wullstein and Zollner.<sup>[6]</sup> The principal indications are recurrent otorrhea, the desire to swim without having to waterproof the ear and to improve conductive hearing loss. Several factors may affect surgical outcome such as the surgical approach (endaural, postaural) and technique (underlay vs. overlay), site of perforation and type of graft utilized.<sup>[7]</sup> The present study was conducted to compare circumferential subannular technique versus conventional underlay technique in Chronic Otitis Media.

In present study, group I had 15 males and 10 females and group II had 12 males and 13 females. Murugendrappa et al,<sup>[8]</sup> compared the two different techniques of myringoplasty-circumferential subannular grafting technique and conventional underlay technique in cases of chronic otitis media with inactive mucosal disease. A total of 50 cases are included in this study, out of which 21 were males and 29 were females with male to female ratio of 0.72:1. The success rate of graft take up by circumferential subannular grafting technique is 96% and by conventional underlay technique is

76% respectively. In circumferential subannular grafting technique, the pre-op mean PTA was 36.92db, and the post-op mean PTA after 3 months was 25.87 db with a mean difference in PTA (dB) was 11.05 with t value of 7.74. In case of conventional underlay technique, the pre-op mean PTA was 38.24 db, and the post-op mean PTA after 3 months was 30.28 db with a mean difference in PTA (dB) was 7.96 with t-value of 14.39.

We observed that mean pre- op PTA was 36.2 db and post op PTA was 25.4 db in group I and 37.4 and 30.1 in group II. Myringoplasty is the operative procedure performed to repair the tympanic membrane perforation and to improve hearing level. The graft success rate depends on various factors such as the size of the perforation, functioning of eustachian tube, graft placement techniques, the experience of the operating surgeon etc. There is marked diversity noted in achieving an intact tympanic membrane following myringoplasty.<sup>[9]</sup> Ralli et al,<sup>[10]</sup> used underlay anchored myringoplasty which utilizes anterior and posterior tunnels to achieve proper tension of the tympanic membrane as well as lateral traction of the malleus handle. It resulted in drum healing (91.7%) and pure tone average (PTA) post operatively was 27dB as compared with 55 dB preoperatively. Primrose and Kerr were able to improve graft tension by using an anterior tunnel created under the annulus. Sauvage et al,<sup>[12]</sup> presented a surgical technique that included the creation of a large anterior flap for stabilizing the fascia

## CONCLUSION

Authors found that circumferential grafting technique is superior in postoperative hearing improvement.

## REFERENCES

1. Millwski C. Composite graft tympanoplasty in the treatment of ears with advanced middle ear pathology. *Laryngoscope*. 1993;103:1352-6.
2. Sergi B, Galli J, De Corso E, Parilla C, Paludetti G. Overlay versus underlay myringoplasty: report of outcomes considering closure of perforation and hearing function. *Acta Otorhinolaryngol Ital*. 2011;31:366-71.
3. Sharp JF, Terzis TF, Robinson J. Myringoplasty for the anterior perforation: experience with the Kerr flap. *J Laryngol Otol*. 1992;106:14-6.
4. Jay B. Farrior sandwich graft tympanoplasty: a technique for managing difficult tympanic membrane perforation. *Oper Tech Otolaryngol Head Neck Surg*. 1995;6:27-32.
5. Farrior JB. The anterior tympanomeatal angle in tympanoplasty: surgical techniques for the prevention of blunting. *Laryngoscope*. 1983;93:992-7.
6. Raghavan U, Malik DSI, Mahmoud NA. Myringoplasty: update on onlay pedicle skin flap and temporalis fascia sandwich graft. *J Laryngol Otol*. 2000;114:174-7.
7. Wehrs R. Grafting techniques. *Otolaryngol Clin N Am*. 1999;32:443-55.
8. Murugendrappa MA, Siddappa PN, Shambulingegowda A, Basavaraj GP. Comparative study of two different myringoplasty techniques in mucosal type of chronic otitis media. *Journal of clinical and diagnostic research: JCDR*. 2016 Feb;10(2):MC01.
9. Kartush J. TM Patcher: a new device to close tympanic membrane. Perforations in an office setting. *Am J Otol*. 2000;21:615-20.
10. Ralli, et al. Anchored Myringoplasty. *The laryngoscope*. 2000;110:674-79.
11. Primose WJ, Kerr AG. The anterior perforation. *Clin Otolaryngol*. 1986;11:175- 76.
12. Sauvage JP, Heutebise F, Hammock PS. Myringoplasty (technique, results). *Rev Laryngol otol Rhinol*. 1998; 117(3):247-51.

Source of Support: Nil, Conflict of Interest: None declared