

Congenital Renal Aneurysmal Arterio-Venous Malformation, mimicking Hydronephrosis; Doppler USG and MDCT Features

Krishna Kumar M¹

¹Associate professor, Department of Radiology, DM Wayanad Institute of Medical Sciences, Wayanad, Kerala.

ABSTRACT

Renal Arteriovenous malformations are very rare and accurate diagnosis ensures proper treatment of the patients. We report a 24 year young female patient of large AVM, presenting with pain in right lumbar region, detected on ultrasound and Multidetector computed tomography.

Key Words: Colour Doppler Imaging, MDCT, Renal Arteriovenous malformation, Ultrasound

INTRODUCTION

Renal arteriovenous malformations (AVM) are rare and can be congenital, acquired or idiopathic.^[1] Congenital and idiopathic varieties are less common and are usually located in the medullary region.^[2] Acquired AVMs may result from trauma, surgery, biopsy, malignancy and inflammation. Frequent symptoms of AVM are hematuria and hypertension. Large-flow arteriovenous fistulae may lead to an increasing cardiac load.^[2] Grey scale sonography is not only inadequate but also misleading in the diagnosis of AVMs. Any inadvertent interventional procedures or surgery performed on these patients with USG diagnosis may be detrimental and catastrophic. Color Doppler Imaging (CDI) and Multidetector computed tomography (MDCT) remains the noninvasive diagnostic modalities of choice for AVMs. Options for therapy range from observation to embolization to nephrectomy.

CASE REPORT

A 24-years old female presented with pain in right lumbar region. Haemogram showed hypochromic microcytic anemia with low haemoglobin (9 gm%). Routine urine examination showed microhematuria. Grey scale Ultrasonography (USG) examination [Figure 1] showed a multilocular cyst/gross hydronephrosis of right kidney, which appeared to replace the renal sinus.

Colour Doppler Imaging [Figure 2] showed flow signals in the cystic lesion with mixing of lighter colors and the presence of coarse, mosaic like vibrational artifacts suggestive of an AVM. Spectral doppler [Figure 3] showed high velocity erratic excursions with complete loss of the cyclic systolic and diastolic pattern and presence of mixture of both arterial and venous tracings.

MDCT scan arterial phase [Figure 4] showed cobra head shaped intrarenal aneurysmal dilatation fed by renal artery. MDCT scan venous phase [Figure 5] showed an oval intrarenal venous pouch draining into renal vein. MDCT scan urogram phase [Figure 6] showed mild dilated, laterally displaced and splayed collecting system. 3D Volume rendered images [Figure 7] show cobra head shaped intrarenal aneurysmal dilatation fed by renal artery communicating by a jet of contrast into an oval intrarenal venous pouch which drains into renal vein.

Name & Address of Corresponding Author

Dr. Krishna Kumar M
Associate Professor & HOD
Dept of Radiology
DM Wayanad Institute of Medical Sciences,
Naseera Nagar, Meppadi P.O., Wayanad, Kerala -
673577.
E mail: drmkrishnakumar@gmail.com

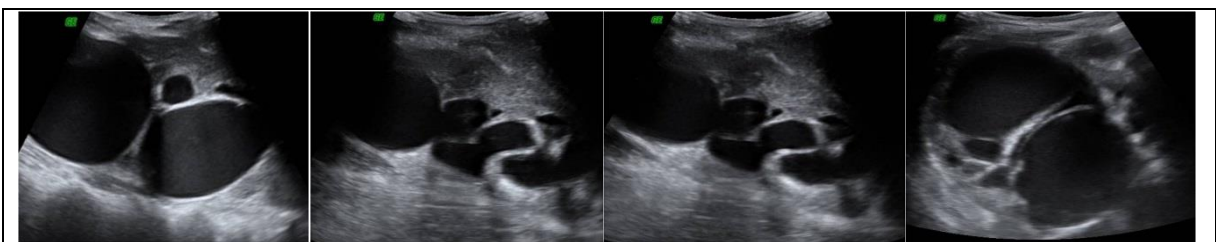


Figure 1: Ultrasonography (USG) examination

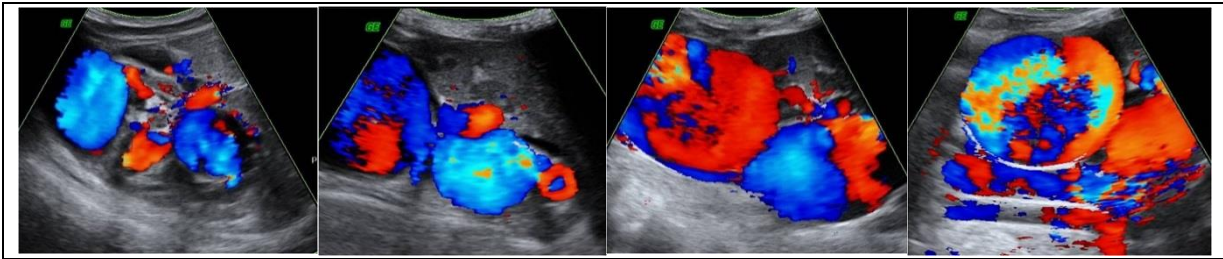


Figure 2: Colour Doppler Imaging of AVM

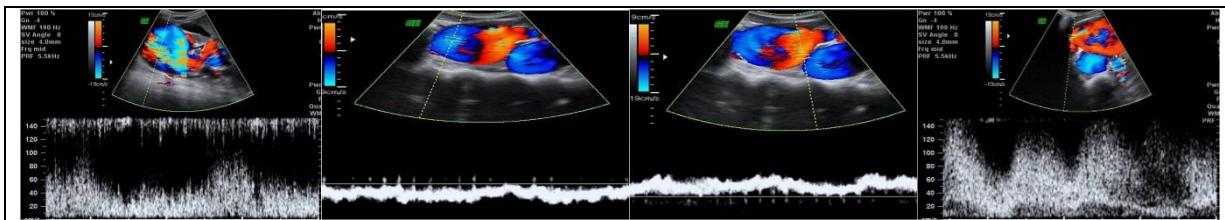


Figure 3: Spectral Doppler of AVM

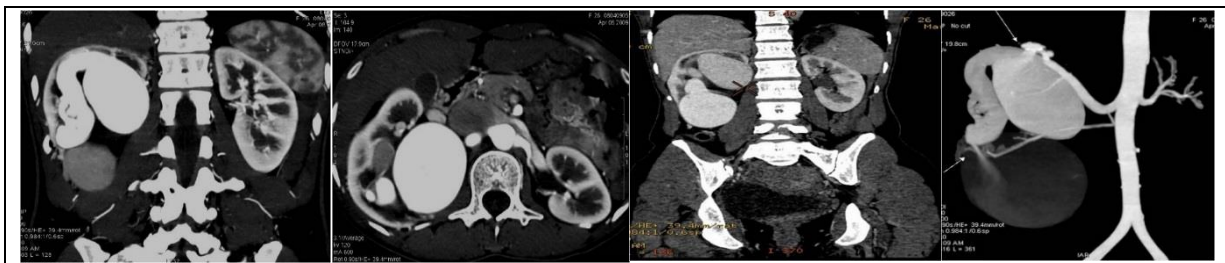

Figure 4: MDCT scan arterial phase

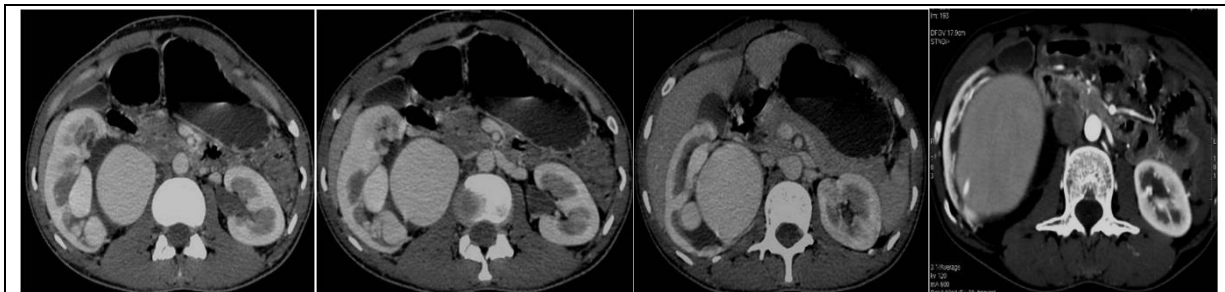


Figure 5: MDCT scan venous phase

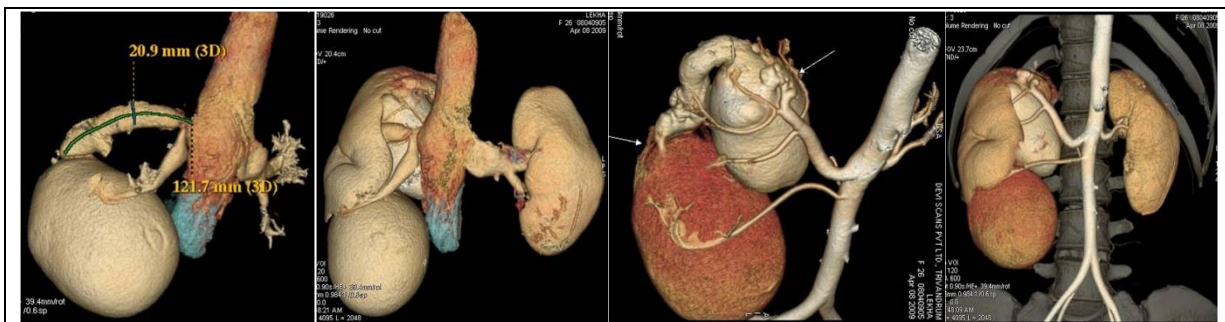


Figure 6: 3D volume rendered images

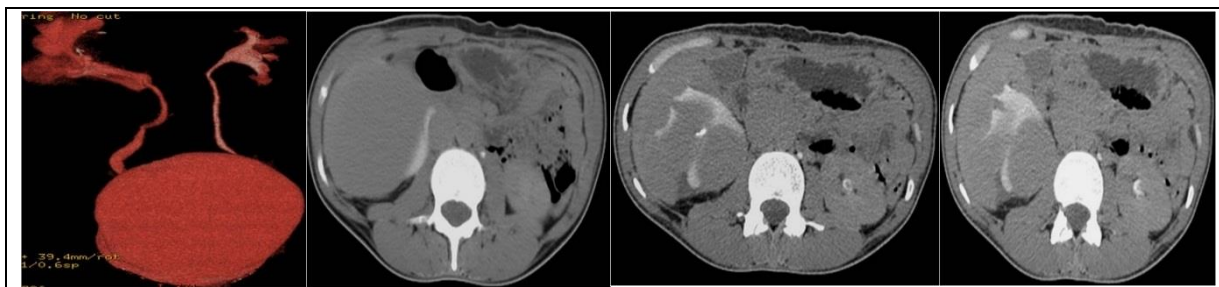


Figure 7: MDCT scan urogram phase

DISCUSSION

Congenital renal arteriovenous malformations are considered to represent focal spontaneous failures of vascular development occurring between the 4th and 10th weeks of life.^[3] However they usually remain asymptomatic until the 3rd or 4th decade of life. Women are affected three times as often as men, and the right kidney is involved slightly more often than the left. Renal AVMs are rare causes of hematuria. Renal AVMs are rare and are of three types: congenital, acquired and idiopathic.^[1]

Acquired renal AVMs are commonest and account for 70% of cases^[4] and may develop following trauma, surgery, biopsy, malignancy and inflammation. AVMs developing after percutaneous biopsy are usually asymptomatic and close spontaneously whereas post-traumatic AVMs are more likely to be symptomatic.

Congenital renal AVMs account for 27% of cases.^[4] Congenital renal AVMs are of two general types: cirroid, with multiple varix-like vascular communications which represents a truly congenital form of arteriovenous malformation^[5]; and aneurysmal, which is considered to be idiopathic, presents at a later age, and usually develops when a pre-existing arterial aneurysm erodes into an adjacent vein.^[6] Hematuria that can be so severe as to be life-threatening is more characteristic of the congenital form of AVMs, presenting as the primary symptom in 3 out of 4 patients.^[6] Congenital renal AVMs more commonly present with an abdominal bruit, hypertension or high output cardiac failure. Idiopathic renal AVMs are rare and account for about 3% of cases. Radiologically, they can be described as acquired fistulae with an artery communicating directly with one or more veins with no obvious cause.^[2]

Renal AVMs on grey scale US simulate hydronephrosis and cysts. In these patients, CDI is an important noninvasive modality that can help differentiate a cystic neoplasm from an AVM. On CDI, AVMs show coarse, mosaic like vibrational artifacts or modulation of the Doppler signal from the artery and vein.^[2] They may also be seen as focal areas of flow, portrayed as a mixing of lighter colors. These were reflected by a rapid flow rate and marked

tortuosity of the vessels Spectral Doppler study shows large peak systolic and end diastolic frequency shifts with a smaller resistive index (RI) than those of a normal intrarenal artery.^[7]

CONCLUSION

Awareness of the fact that AVMs may mimic conditions such as hydronephrosis, parapelvic or other cystic lesions on grey scale USG, Colour Doppler Imaging is very important particularly if percutaneous interventions or surgery are to be contemplated.

REFERENCES

1. Kember PG, Peck RJ. Renal Arteriovenous Malformations Mimicking Hydronephrosis. *J Clin Ultrasound* 1998;26:95-7.
2. Shah SR, Momin AM, Talati AR, Shah RV, Gosami KG, Panchal SY. Large arteriovenous malformation in kidney mimicking cyst. *Indian J Radiol Imaging* 2000;10:35-6.
3. Rosen RJ, Ryles TS: Arterial venous malformations. In *Vascular disease. Surgical and Interventional Therapy* Volume 2. Edited by: Strandness DE, Van Breda A. New York, Churchill Livingstone; 1994:1121-37.
4. Megally HI, Seliem AM, Abdalla AK. Role of the MDCT urography in diagnosis of renovascular diseases. *The Egyptian Journal of Radiology and Nuclear Medicine* 2011;42:87-92..
5. Sountoulides P, Zachos I, Paschalidis K, Asouhidou I, Fotiadou A, Bantis A et al. Massive hematuria due to a congenital renal arteriovenous malformation mimicking a renal pelvis tumor: a case report. *J Med Case Reports*. 2008; 2: 144.
6. Tarkington MA, Matsumoto AH, Dejter SW, Regan JB. Spectrum of renal vascular malformation. *Urology* 1991;38(4):297-300.
7. Takebayashi S, Aida N, Matsui K. Arteriovenous malformations of the kidneys: diagnosis and follow-up with color Doppler sonography in six patients. *AJR* 1991;157:991-5.

How to cite this article: Kumar KM. Congenital Renal Aneurysmal Arterio-Venous Malformation, mimicking Hydronephrosis; Doppler USG and MDCT Features. *Ann. of Int. Med. & Den. Res.* 2015;1(2):92-4.

Source of Support: Nil, **Conflict of Interest:** None declared