

# A Prospective Study Evaluating the Prognostic Factors in Management of Cervical Spondylotic Myelopathy

I. D. Chaurasia<sup>1</sup>, Mahim Koshariya<sup>2</sup>, M.C. Songara<sup>3</sup>

<sup>1</sup>Assistant Professor, Department of Neurosurgery, Gandhi Medical College, Bhopal.

<sup>2</sup>Associate Professor, Department of Surgery, Gandhi Medical College, Bhopal.

<sup>3</sup>Professor & Head, Department of Surgery, Gandhi Medical College, Bhopal.

Received: December 2014

Accepted: December 2014

## ABSTRACT

**Background:** Cervical Spondylotic Myelopathy is a common degenerative disorder of the cervical spine that can potentially cause devastating and irreversible impairment of neurological function. Its a major source of disability in adult population leading to acquire Spinal Cord Dysfunction. The anterior cervical disectomy and fusion (ACDF) is established gold standard for degenerative Cervical Spine diseases. A clear overview of other surgical techniques is lacking. Cervical disc Prosthesis is not inferior to disectomy and fusion probably some superior in terms of neck pain. **Methods:** This Prospective study was done in Gandhi Medical College and Associated Hamidia Hospital Bhopal from Jul 2012 to Dec 2013. **Results:** The cervical disectomy with inter body fusion for cervical Spine disease reduces pain and improve quality of the life of the patients In light of the tremendous suffering associated with cervical spine disease , the development of new non-pharmacologic strategies to alleviate chronic pain and improve the quality of life for cervical spine disease patients deserves immediate attention and encouragement. **Conclusion:** CSM is a very practical scale which can be applied easily with the available clinical and radiological data, with good accuracy of outcome prediction.

**Keywords:** Cervical Spine Surgery, cervical spondylotic myelopathy, clinical outcome, Prognostic indicators.

## INTRODUCTION

Cervical spondylotic myelopathy (CSM) and cervical spondylotic radiculopathy (CSR) caused by compressive lesions from degenerative spondylotic changes have been surgically treated by various means: subtotal corpectomies with strut grafting, multiple discectomies with or without interbody fusions, anterior foraminotomy, laminectomy, and laminoplasty.<sup>[1,2]</sup>

In the past decade, our understanding of the biomechanics of the spine has improved along with advances in spinal instrumentation. This has led to significant changes in the surgical management of CSM. Hence, a review of the current status of the various surgical options available for this disease entity is necessary.<sup>[3]</sup> This review will discuss the indications, advantages and limitations of the various commonly available surgical techniques for CSM. For brevity's sake, details of surgical techniques will not be discussed.<sup>[4]</sup>

Cervical Spondylosis is an insidious degenerative disease that starts in the intervertebral disk and continues to the surrounding bone and soft tissue.<sup>[5]</sup> The height of the intervertebral disk decreases when the natural aging process begins. With decreasing disk height, diffuse intumescence forms in the disk, which causes the outburst of the disk from the annulus. Calcified disk herniations, osteophyte formations, arthritic changes, and

hypertrophy in facets accompany this condition. Treatment for Cervical Spondylotic Myelopathy (CSM) includes physical treatment and surgical decompression operations. Surgery is preferred in patients with refractory pain, progressive neurologic deficits, and detectable compression in the spine and nerve roots.

Although CSM is a frequently seen pathology in routine neurosurgery practice, anticipating patients' postoperative condition is difficult. In this study, we tested the effects of sex, age, symptom duration, number of compressed disk levels, spinal cord diameter, sagittal alignment, hypertension (HT), diabetes mellitus (DM), and intensity differences in magnetic resonance imaging (MRI) on the prognosis for CSM.<sup>[6]</sup>

## MATERIALS AND METHODS

This Study was carried out at Govt. Medical College, Bhopal from Jul 2012 to Dec 2013, which includes 32 patients. Primary outcome measures of interest were: neck and/or arm pain, neck-pain-specific functional status, and self-perceived recovery. Secondary outcomes were sick leave and complications of surgery. Studies were combined into 2 clusters:

1. Surgical fusion methods compared with other surgical fusion methods.
2. Surgical fusion methods compared with artificial (prosthetic) cervical disc surgery.

We used a standardized form to extract data from the included papers: study characteristics, patient characteristics, description of the experimental and control interventions, cointerventions (if used),

### Name & Address of Corresponding Author

Dr. I. D. Chaurasia  
Assistant Professor,  
Department of Neurosurgery,  
Gandhi Medical College, Bhopal

duration of follow-up, types of outcomes assessed, and possible conflict of interest. Two review authors (SMR and MvM) independently extracted data and disagreements were discussed. A third review author (APV) was consulted if necessary.

**Inclusion Criteria**

1. Only randomized controlled trials (RCT) including adult subjects with Cervical Disorders were considered.
2. We included studies evaluating Anterior Cervical Surgical interventions, including Discectomy with different inter body fusion methods & Prosthetic Disc Surgery.

**Exclusion Criteria**

1. We excluded patients with Distinct Cervical Myelopathy who needed specific surgery, as this is a very serious condition.

**RESULTS**

**Table 1: Gender Distribution**

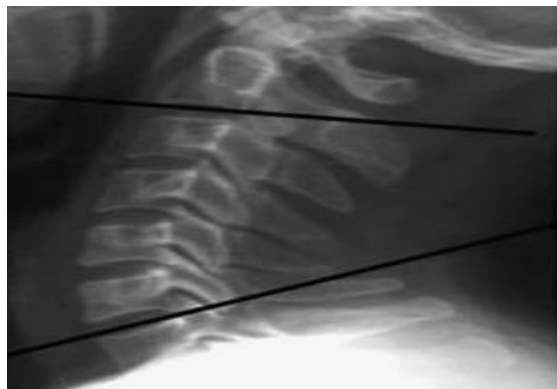
S. No.	Gender	No.	Percentage
1	Male	21	65.6
2	Female	11	34.4

**Table 2: Age Distribution**

S. No.	Gender	No.	Percentage
1	<50	19	59.3
2	>50	13	40.7

**Table 3: Predictors for Surgical Outcome in Cervical Spondylotic Myelopathy**

Factor	Excellent	Good	Fair	Poor
Age (years)				
≤50	7	0	0	0
>50	1	2	3	0
Duration of symptoms (years)				
≤1	8	2	1	0
>1	0	0	2	0
No. of levels decompressed				
1–2 levels	7	1	3	0
3–4 levels	1	1	0	0
High-intensity areas on T2-weighted	4	1	2	0



**Figure 1: Sagittal Alignments**

A score of 07 and above, 03 and 04 and less, are indicative of improvement, static outcome and deterioration, respectively.

**DISCUSSION**

A recent AOSpine study found that 75% of patients who undergo surgery for CSM have a more than 2-point increase in their mJOA score.

Outcome of surgery in CSM is variable. A number of prognostic factors in CSM has been studied and evaluated.<sup>[7]</sup> Patient’s age, duration of symptoms, preoperative neurological status, radiological findings including number of levels of compression, effective canal diameter, and intrinsic signal changes in the cord, have been found to be the most important of them.<sup>[8]</sup>

**CONCLUSION**

Significant advances have taken place in the surgical management of CSM. CSM is a very practical scale which can be applied easily with the available clinical and radiological data, with good accuracy of outcome prediction.

**REFERENCES**

1. Fager CA (1973) Results of adequate posterior decompression in the relief of spondylotic cervical myelopathy. *J Neurosurg* 38:684–692.
2. Jho HD, Kim MH, Kim WK (2002) Anterior cervical microforaminotomy for spondylotic cervical myelopathy: part 2. *Neurosurgery* 51(Suppl 2):54–59
3. Wada E, Suzuki S, Kanazawa A, Matsuoka T, Miyamoto S, Yonenobu K (2001) Subtotal corpectomy versus laminoplasty for multilevel cervical spondylotic myelopathy: a long-term follow-up study over 10 years. *Spine* 26:1443–1447.
4. Zareth IN, Hilibrand A, Gustavel M, McLain R, Shaffer W, Myers M, et al. Variations in surgical decision making for degenerative spinal disorders: Part II: Cervical spine. *Spine* 2005;30:2214-9.
5. Emery SE, Bohlman HH, Bolesta MJ. Anterior cervical decompression and arthrodesis for the treatment of cervical spondylotic myelopathy. *J Bone Joint Surg Am* 1998;80:941-51.
6. Komotar RJ, Mocco J, Kaiser MG. Surgical management of cervical myelopathy: Indications and techniques for laminectomy and fusion. *Spine J* 2006;6(6 Suppl):252S-67S.
7. Cooper PC. Anterior cervical corpectomy for cervical spondylotic myelopathy. *Neurosurgery* 1998;43:266-7.
8. Liu JK, Das K. Posterior fusion of the subaxial cervical spine: Indications and techniques. *Neurosurg Focus* 2001;10:E7.

**How to cite this article:** Chaurasia ID, Koshariya M, Songara MC. A Prospective Study Evaluating the Prognostic Factors in Management of Cervical Spondylotic Myelopathy. *Ann. Int. Med. Den. Res.* 2015;1(1):72-73.

**Source of Support:** Nil, **Conflict of Interest:** None declared