

## Complication of Regeneration of Bone in the Extracted Third Molar Sockets Augmented without using Beta Tricalcium Phosphate

Muhammad Mubashirul Haque<sup>1\*</sup>, Mostafa Md. Anisuzzaman<sup>2</sup>, Sajid Hasan<sup>3</sup>, Nubad Adnan<sup>4</sup>

<sup>1</sup>Assistant Professor, Department of Periodontology and Oral Pathology, Birdem General Hospital, Dhaka, Bangladesh.

\*Corresponding author

<sup>2</sup>Lecturer, Department of Oral and Maxillofacial Surgery, Ibrahim Medical College (Dental unit), Dhaka, Bangladesh.

<sup>3</sup>Assistant Professor, Department of Oral and Maxillofacial Surgery, Ibrahim Medical College (Dental unit), Dhaka, Bangladesh.

<sup>4</sup>Medical Officer, Department of Dental Surgery, Birdem General Hospital, Dhaka, Bangladesh.

Received: March 2021

Accepted: April 2021

### Abstract

**Background:** Mandibular third molar surgical extraction may not be benefited without using Beta Tricalcium Phosphate complications on the distal aspect of the root of the adjacent mandibular second molar. Patients older than 18 years with using Beta Tricalcium Phosphate pathology on the distal surface of the mandibular second molar and a horizontal/mesioangular impacted mandibular third molar may benefit from bone regenerative therapy at the time of surgery. **Methods:** This was an experimental study. 20 patients (Group-A) whose were prepared on Alloplastic bone substitute and another 20 patients (Group-B) whose were without alloplastic bone substitute. 40 patients were selected under group where surgical extraction of mandibular horizontal impacted 3rd molar by using standard conventional method was followed by alloplastic bone substitute, Beta tricalcium phosphate another 20 patients was selected under this group where surgical extraction of mandibular horizontal impacted 3rd molar by using standard conventional method was followed by without alloplastic bone substitute, Beta tricalcium phosphate. Post-operative clinical examination and radiological examination were performed at one day then at 1, 3, 6 months postoperatively. Statistical analysis of the results was obtained by using window-based computer software devised with Statistical Packages for Social Sciences (SPSS-22). **Results:** Majority of the patients 22(55.0%) were of 18-25 years age group and another 15(37.5%) were at their 26-35 age group. Mean±SD age of the patients were 25.97±4.99 years. Rate of infection are found to be lower among the patients managed with alloplastic bone substitute reinforcement. Statistical test endorses the association between type of management and occurrence of infection. **Conclusion:** The results suggest that if we use  $\beta$ -TCP/CS at mandibular third molar post-extraction sites, it will be good where bone regeneration methods are indicated. On the other hand, if we don't use  $\beta$ -TCP/CS on extraction sites, good result will not come.

**Keywords:** Mandibular third molars; Bone regeneration;  $\beta$ -tricalcium phosphate; Calcium sulfate; Bone gain.

### INTRODUCTION

The presence of third molars is common in humans, and mandibular third molars are frequently found to be fully or semi- impacted in the bone.<sup>[1]</sup>

The presence of a mandibular third

molar that failed to erupt or is partially erupted may cause a plethora of problems, and indications for mandibular third molars removal include acute or chronic infection, pain, caries, prevention or repair of using Beta Tricalcium Phosphate



defects, pathology associated with cystic degeneration and/or neoplastic transformation of the dental follicle, and facilitation of orthodontic treatment.<sup>[2,3]</sup> The literature also suggests that even for asymptomatic and disease-free impacted or semi-impacted mandibular third molars in young adults, there is an accumulative high risk for extraction in the future.<sup>[4]</sup> Although after the extraction of a mandibular third molar the socket is generally healed spontaneously by formation of new bone, several clinical parameters may affect the level of bony healing, and surgical removal of third molars has been associated with the risk of having persistent or developing new using Beta Tricalcium Phosphate defects on the distal aspect of the adjacent mandibular second molar.<sup>[5]</sup> One of the most important factors seems to be the age of the patient at the time of mandibular third molar removal and younger patients (age < 25) have a higher probability of uneventful healing.<sup>[2,3]</sup> Moreover, the positioning of a partially or fully impacted mandibular third molar, as well as the using Beta Tricalcium Phosphate status distally to the root of the mandibular second molar and the presence of bone between the mandibular second molar and the mandibular third molar are important parameters. According to the literature the majority of mandibular third molars indicated for surgical removal are mesially or horizontally inclined being in close proximity or in contact with the mandibular second molar, and using Beta Tricalcium Phosphate problems are found in 48% of

mandibular second molars after extraction of the adjacent mandibular third molar, with post-operative residual probing depth > 7 mm in 43.3%.<sup>[1,6-9]</sup> In order to prevent using Beta Tricalcium Phosphate complications and assist the bone reconstruction of the sites after the surgical removal of mandibular third molars in such cases, and especially for patients older than 26 years, clinicians might need to implement additional measures, and guided bone regeneration techniques with the use of bone grafts are commonly considered for the reconstruction of the mandibular third molar extraction socket.<sup>[1,3,10-17]</sup> According to the available scientific evidence, different flap designs,<sup>[13,14]</sup> or different suturing techniques do not influence the using Beta Tricalcium Phosphate healing of the mandibular second molar,<sup>[5]</sup> when removing mandibular third molars. On the contrary, systematic reviews have shown that bone grafting as a surgical intervention during removal of mandibular third molars may affect the outcome. For this reason, it is of great clinical importance to further document and evaluate the effect of the use of bone grafting materials and techniques when surgically extracting mandibular third molars with using Beta Tricalcium Phosphate pathology on the distal aspect of the mandibular second molars. The biomaterials that are used for bone grafting have different properties regarding new bone formation and graft resorption, mainly depended on their origin and chemical composition, thus leading to different amounts and quality of



regenerated bone at the extraction site where they are implanted.<sup>[18-24]</sup> Randomized controlled trials analyzing and comparing data from human bone biopsies have revealed that sockets treated with alloplastic biomaterials had the highest amount of regenerated bone (45.53%) compared to sites subjected to spontaneous healing with no graft material (41.07%) or xenografts (35.72%).<sup>[25]</sup> The same studies have shown that the amount of residual biomaterial was highest in healed extraction sites grafted with xenografts (19.3%) compared to alloplastic materials (13.67%). Although the body of literature pertaining the bone regeneration techniques aimed at preserving the using Beta Tricalcium Phosphate health of the mandibular second molar after surgical removal of the adjacent mandibular third molar is not scarce, there are no studies investigating the use of calcium phosphates or calcium sulfate in such clinical scenarios. Bioactive ceramics, such as  $\beta$ -TCP, are biocompatible grafts frequently utilized in bone regenerative procedures. As they are not from human or animal origin, they do not carry any immunological or infection risk. Their composition is similar to that of natural bone and can integrate with the defect site. Calcium phosphates and  $\beta$ -TCP are osteoconductive because osteoblasts adhere to them and deposit new bone on their surface.<sup>[24-30]</sup> A growing body of literature in the medical and dental research fields reveals and demonstrates the osteoinductive potential of novel calcium phosphate

materials and the up-regulation of host regeneration as a result. These biomaterials can induce bone regeneration in extra skeletal areas by stimulating stem cells to differentiate to bone forming cells.<sup>[31-35]</sup> It is a safe, fully-resorbable, moldable material that has good handling properties and has been shown to support bone regeneration.<sup>[37,38]</sup> Adding CS to  $\beta$ -TCP produces a compound alloplastic scaffold that hardens in situ, binds directly to the host bone and helps maintaining the space and shape of the grafted site. Both CS and  $\beta$ -TCP are soluble bone substitutes, being degradable and fully replaced by new bone. The CS element is completely dissolved within 3-6 weeks after implantation, thus increasing the porosity in the  $\beta$ -TCP scaffold for improved vascular ingrowth and angiogenesis, while the  $\beta$ -TCP element will degrade by hydrolysis and phagocytosis, so that it will be completely substituted by new bone within 9-18 months.<sup>[29,38,49-51]</sup> The aim of this case series was to present and evaluate the clinical and radiological outcomes in patients older than 26 years with mesioangular or horizontally impacted mandibular third molars and using Beta Tricalcium Phosphate pathology on the distal surface of the MANDIBULAR SECOND MOLAR, treated with surgical removal of the mandibular third molar and simultaneous grafting of the osseous defect using a resorbable alloplastic  $\beta$ -TCP/CS biomaterial.



### **Objective**

This study was to find out the complication of mandibular bone regeneration after giving beta tricalcium phosphate and to determine whether there are differences in the post-operative period (pain, swelling, trismus, infection) depending on the material use.

### **MATERIALS AND METHODS**

This experimental study was conducted in Bangabandhu Sheikh Mujib Medical University Hospital (BSMMU), during January 2010 to December 2011. The study population were Population human being. All the patients were under going for extraction of impacted Horizontal mandibular third molar, who fulfilled the basic requirements of inclusion and exclusion criteria in the series of the study. This was an experimental study. 20 patients (Group-A) whose were prepared on Alloplastic bone substitute and another 20 patients (Group-B) whose were without alloplastic bone substitute. 20 patients were selected under this group where surgical extraction of mandibular horizontal impacted 3rd molar standard conventional method was followed by alloplastic bone substitute, Beta tricalcium phosphate. 20 patients were selected under this group where surgical extraction of mandibular horizontal impacted 3rd molar standard conventional method was followed by alloplastic bone substitute, Beta tricalcium phosphate. Inclusion criteria were Horizontal mandibular 3rd molar, Noninfected 3rd molar

region and Patient given consent for the study. Exclusion criteria were patients with any systemic bone diseases, medically compromised patient, alcoholics and other drug addicted people and patients who are not willing to be a part of the study. Statistical analyses of the results were obtained by using window based computer software devised with Statistical Packages for Social Sciences (SPSS-26). The results were presented in tables, figures, diagrams. Comparison of means made by using Student t-test and categorical data was analyze by Chi-square Test, Odds Ratio (OR) with 95% confidence interval and p value < 0.05 was considered significant.

### **RESULTS**

[Table 1] shows the distribution of the age of the patients. Majority of the patients 22(55.0%) were of 18-25 years age group and another 15(37.5%) were at their 26-35 age group. Mean age of the patients was 25.97±4.99 years. [Table 2] shows the sex distribution of the patients. Among the patients 57.5% were female and rest were male. Male: female ratio was 1:1.35. [Figure 1] shows the distribution of the patients by type of management provided and history of complication. Rate of infection are found to be lower among the patients managed with alloplastic bone substitute reinforcement. Statistical test endorses the association between type of management and occurrence of infection.

**Table 1: Age distribution of the patients in two study groups (n=40)**

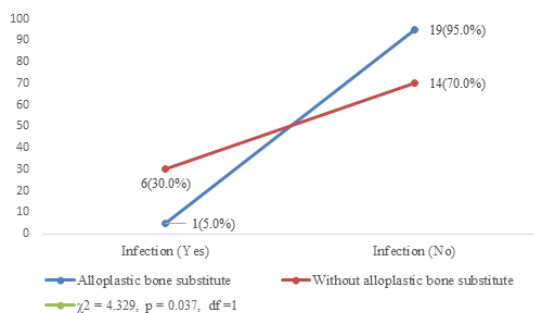
Age group (in years)	Alloplastic bone substitute		Without alloplastic bone substitute		p value
	n=20	%	n=20	%	
18 years to 25 years	11	55.0	11	55.0	0.27ns
26 years to 35 years	7	35.0	8	40.0	
36 years to 42 years	2	10.0	1	5.0	
Total	20	100.0	20	100.0	
Mean±SD	25.10±4.37		26.85±5.52		

P value performed by Independent student t-test, ns = Not significant

**Table 2: Sex distribution of the patients in two study group (n=40)**

Sex	Alloplastic bone substitute		Without alloplastic bone substitute		p value
	n=20	%	n=20	%	
Male	9	45.0	8	40.0	0.749
Female	11	55.0	12	60.0	
Total	20	100.0	20	100.0	

p value performed by Chi-square test, ns = Not significant



**Figure 1: Distribution of the patients by management type and history of complication**

p value performed by Chi-square test, s = Significant

## DISCUSSION

There are several reasons to consider preservation of the alveolar socket immediately following tooth extraction. One reason for placing a graft of a synthetic biomaterial is to stabilize the coagulum within the socket and avoid possible reduction of

the hard tissue volume required for bone regeneration.<sup>[19]</sup> Another reason for placing a graft into an extraction socket is to provide a scaffold for the in-growth of cellular and vascular components to form new bone of acceptable quality and quantity. The presented research studied 40 cases of mandibular horizontal impacted teeth to evaluate the status of bone regeneration after surgical extraction and filling the bony cavity with or without beta tricalcium phosphate. There was significant relationship in distribution of sex in impaction. The distribution of impacted third molars by sex is shown in Table-2, there was significantly more females (56%) than males (44%) with at least one impacted third molar, observed that.<sup>[20]</sup> In our study 57.5% of respondent were female and 42.5% were male which was similar to that.



In our study total 40 patients with Horizontal impaction were investigated. All the patients were categorized into three age groups, Group 1 (18-25 years), Group II (26-35 years) and Group III (36-42 years). Older age was found to increase the risk of an extended operation time. Mean age was  $25.97 \pm 4.99$  years [Table1]. Among the male population 18-25 years comprises the highest (55.1%) subject. Surgical removal of third molars causes significant pain, swelling, and trismus even when that is removed using a gentle surgical technique. Site and size of the bony defects has a strong relation with the outcome (bone regeneration) of treatment. Relative bigger bony cavity takes time for complete bony healing after surgical extraction but small sized bony cavity takes less time and showed uniformed bone formation. In this study the categorized our 40 cases into (less than 2 cm) and (more than 2 cm) sized bony cavity. Most 65.0% of our cases were less than 2 cm and the rest 35.0 were more 2 cm sized. Whereas some study showed that allograft in defects more than 3 cm in diameter had approximately the same rate of success as those in small defects.<sup>[21]</sup>

Bone regeneration after surgical extraction of horizontal impaction Third Molar has several influencing factors. Oral hygiene status the prime of them. Of the presented cases oral hygiene index was calculated to evaluate the oral hygiene status. These showed 42.5% of the total cases had poor oral hygiene status and 20.0%

had average oral hygiene status. Outcome of the treatment of this study was evaluated on the basis of post-operative radiological diameter of the defect, radiological evidence of trabeculae formation. In this study out of 40 cases, 20 cases (study) were used beta tricalcium phosphate as bone substitute and remaining 20 cases (control) no bone substitute. Follow up was given immediate after operation, 1 month, 3 month and 6-month interval. Study cases showed mean immediate after operation diameter of bony defect was 17.85 after six months mean diameter was "3.95" with standard deviation "1.23" but the control cases showed immediate after operation mean diameter of 19.05 and after six month 7.35 with standard deviation 0.88.

In this study radiological outcome was assessed through independent sample 't' test following Levene's test for equality of variance. No significant difference in radiological response was evident between the groups before one month ( $P = 0.08$ ) at follow up of one month to six months the difference of radiological change appeared statistically significant ( $P = 0.00$ ). It was found that reducing the diameter of lesion with allow plastic bone grafting both clinically and radiologically was better than conventional enucleation supported. This observation was concluded by them that the patients with alloplastic bone substitute showed better radiological outcome than their non-alloplastic bone substitute counterparts. They also revealed the outcomes between



two groups were poorly defined in the initial few weeks but in the later period like one month it was significant, which results is very close to some study.

In this study trabecular pattern was assessed through independent sample 't' test following Levene's test for equality of variance. Significant difference in radiological response was evident between the groups. From immediate after operation to six months the difference of trabecular pattern appeared to be statistically significant. ( $P=0.25$ ) & ( $P=0.00$ ). Patients with alloplastic bone substitute showed superior trabecular pattern that the non-alloplastic bone substitute counterparts. The difference of trabecular pattern between the two groups started to amplify in the post-operative period. The difference was persistent throughout the period 6 months with gradual increasing tendency.

Presence or absence of post-operative infection indicates failure or success of bone substitute. In this study 82.5% study cases showed no infection but control group showed 17.5% infection. That is rate of infection found to be lower in the study group (Table-7)  $\chi^2=4.329$   $p = 0.037$   $df = 1$  Correlation of oral hygiene status and post-operative complication was done. This showed 82.5% had no post-operative infection but 17.5% had post-operative infection. All of them were of poor oral hygiene status which is supported by the findings of some study. Infection occurred usually within the one week after operation and presented by the

features of localized swelling and exudation which leads to exposure of grafted bone substitute. This condition was then treated by removal of the graft material and curettage of necrosed tissue and use of proper antibiotics.

## CONCLUSION

The results suggest that if we use  $\beta$ -TCP/CS at mandibular third molar post-extraction sites, it will be good where bone regeneration methods are indicated. On the other hand, if we don't use  $\beta$ -TCP/CS on extraction sites, good result will not come.

### Limitation of the Study

This was a single center study with limited sample size. So, the result might not be reflecting the scenarios of the whole country.

### Recommendation

If we could take a larger sample size as well as get enough time for the study, our study will be more qualitative.

## REFERENCES

1. Kim, J.W.; Jo, Y.Y.; Kim, J.Y.; Oh, J.H.; Yang, B.E.; Kim, S.G. Retrospective comparative clinical study for silk mat application into extraction socket. *Maxillofac. Plast. Reconstr. Surg.* 2019, 41, 16.
2. Camps-Font, O.; Caro-Bonfill, C.; Sánchez-Garcés, M.À.; Gay-Escoda, C. Using Beta Tricalcium Phosphate Regenerative Therapy for Preventing Bone Defects Distal to Mandibular Second Molars After Surgical Removal of Impacted Third Molars: A Systematic Review and Meta-Analysis of Randomized Clinical Trials. *J. Oral Maxillofac. Surg.* 2018, 76, 2482-2514.



3. Lee, C.T.; Hum, L.; Chen, Y.W. The effect of regenerative using Beta Tricalcium Phosphate therapy in preventing using Beta Tricalcium Phosphate defects after the extraction of third molars: A systematic review and meta-analysis. *J. Am. Dent. Assoc.* 2016, 147, 709-719.
4. Bouloux, G.F.; Busaidy, K.F.; Beirne, O.R.; Chuang, S.K.; Dodson, T.B. What is the risk of future extraction of asymptomatic third molars? A systematic review. *J. Oral Maxillofac. Surg.* 2015, 73, 806-811.
5. Barbato, L.; Kalemaj, Z.; Buti, J.; Baccini, M.; La Marca, M.; Duvina, M.; Tonelli, P. Effect of Surgical Intervention for Removal of Mandibular Third Molar on Using Beta Tricalcium Phosphate Healing of Adjacent Mandibular Second Molar: A Systematic Review and Bayesian Network Meta-Analysis. *J. Periodontol.* 2016, 87, 291-302.
6. Karapataki, S.; Hugoson, A.; Kugelberg, C.F. Healing following GTR treatment of bone defects distal to mandibular 2nd molars after surgical removal of impacted 3rd molars. *J. Clin. Periodontol.* 2000, 7, 325-332.
7. Aloy-Prósper, A.; García-Mira, B.; Larrazabal-Morón, C.; Peñarrocha-Diago, M. Distal probing depth and attachment level of lower second molars following surgical extraction of lower third molars: A literature review. *Med. Oral Patol. Oral Cir. Bucal* 2010, 15, e755-e759.
8. Tallgren A (2003) The continuing reduction of the residual alveolar ridge in complete denture wearers: a mixed-longitudinal study covering 25 years. *J Prosthet Dent* 89:427-435.
9. Lekovic V, Kenney EB, Weinlaender M, Han T, Klokkevold P, Nedic M, Orsini M (1997) A bone regenerative approach to alveolar ridge maintenance following tooth extraction. Report of 10 cases. *J Periodontol* 68:563-570.
10. Schropp L, Wenzel A, Kostopoulos L, Karring T (2003) Bone healing and soft tissue contour changes following single-tooth extraction: a clinical and radiographic 12-month prospective study. *Int J Periodontics Restorative Dent* 23:313-323.
11. Carmagnola D, Adriaens P, Berglundh T (2003) Healing of human extraction socket filled with Bio-Oss®. *Clin Oral Implants Res* 14:137-143.
12. Kainulainen VT, Sándor GKB, Carmichael RP, Oikarinen KS (2005) Safety of zygomatic bone harvesting: a prospective study of 32 consecutive patients with simultaneous zygomatic bone grafting and 1-stage implant placement. *Int J Oral Maxillofac Implants* 20:245-252.
13. Bauer TW. (2007), 'An overview of the histology of skeletal substitute materials' *Arch. Pathol.Lab.Med* vol. 131, pp.217-224.
14. Clavero J, Lundgren S (2003) Ramus or chin grafts for maxillary sinusinlay and local onlay augmentation: comparison of donor site morbidity and complications. *Clin Implant Dent Relat Res* 5:154-160.
15. Giannoudis PV, Dinopoulos H, Tsiridis E (2005) Bone substitute: an update. *Injury* 36:S20-S27.
16. Hoexter DL (2002), 'Osseous regeneration in compromised extraction sites: a ten - year case study', *j.OralImplantol*, vol. 28, pp. 19 - 24.
17. Legeros R. (2002), ' Properties of osteoconductive biomaterials: calcium phosphates. *ClinOrtop. Relat, Res* vol. 39, pp. 81 - 98.
18. Zhang Y, Xu HH, Takagi S, Chow L. (2006), ' In-situ hardening hydroxyapatite-based scaffold for bone repair' , *J Mater Sei mater Med*, vol. 17, pp. 4374-4445.
19. Chen ST, Wilson TG, Jr. Hammerie CH. Immediate or early placement of implants following tooth extraction: review of biologic basis, clinical procedure, and outcomes. *Int J Oral Maxillofac Implants* 2004; 19 Suppl: 12-24.
20. Quek, SL, Tay, CK, Toh, SL, Lim, KC 2003 "Pattern of third molar impaction in Singapore Chinese population: a retrospective radiographic survey" *Int. J. Oral Maxillofac. Surg.* Vol. 32, pp. 548-552.
21. Marble HB, Captain DC. (1968), 'Homografts of freeze-dried bone in cystic defects of the jaws', *Federal dental services*, vol. 26. no. 1, pp.118.

Source of Support: Nil, Conflict of Interest: None declared