

## A Study on the Retrospective Analysis of Gastrointestinal Stromal Tumors

Shabbir Ahmed<sup>1\*</sup>, Asim Shafi<sup>2</sup>, Umair Tahir<sup>3</sup>, Rab Nawaz Malik<sup>4</sup>, Abdul Quddus<sup>5</sup>

<sup>1</sup>Assistant Professor, Department of General Surgery, Bakhtawar Amin Medical and Dental College, Multan, Pakistan. Email: shabbirahmad2011@hotmail.com.

\* Corresponding author

<sup>2</sup>Associate Professor, Department of General Surgery, Bakhtawar Amin Medical and Dental College, Multan, Pakistan.

<sup>3</sup>Senior Registrar, Department of General Surgery, Bakhtawar Amin Medical and Dental College, Multan, Pakistan.

<sup>4</sup>Assistant Professor, Department of General Surgery, Bakhtawar Amin Medical and Dental College, Multan, Pakistan.

<sup>5</sup>Assistant Professor, Department of General Surgery, Bakhtawar Amin Medical and Dental College, Multan, Pakistan.

Received: March 2021

Accepted: April 2021

### Abstract

**Background:** Gastrointestinal stromal tumors (GIST) are rare tumors of the digestive system with different distribution and clinical features. Purpose: The aim of our study is to observe the demographic and clinical characteristics of GIST in our clinical environment. **Methods:** It was a retrospective analysis of the records of patients hospitalized and treated at Bakhtawar Amin Medical and Dental college Multan for five years duration from January 2016 to January 2021. **Results:** During the study period, a total of 27 patients diagnosed with GIST based on histopathology were enrolled in the study, there were 15 women and 12 were male with a male to female ratio of 1: 1.3. The mean age was 51 years (range 35-65 years). The most common symptom was abdominal pain at a rate of 60%, followed by a tumor in the abdomen, anemia due to vomiting, and decreasing weight loss. Two patients presented to the emergency department, one with intestinal obstruction and the other with upper gastrointestinal bleeding. However, the symptoms overlapped the patients. **Conclusion:** GISTs are rare entities with a variety of clinical features, but with a favorable prognosis if diagnosed early. The doctor requires a high degree of suspicion for prompt diagnosis and early treatment.

**Keywords:** GIST, Mesenchymal Tumors, Abdominal Mass.

### INTRODUCTION

GIST is one of the most common mesenchymal tumors of the gastrointestinal tract, accounting for approximately 1-3% of all gastrointestinal malignancies.<sup>[1]</sup> GISTs can also come from the mesentery and

the omentum.<sup>[2]</sup> Many GIST tumors have an activating mutation in KIT or PDGFR $\alpha$  (platelet growth factor alpha receptor). The prevalence of GIST is estimated at approximately 10-20 per million people per year. GISTs have a wide range of clinical behaviors, from benign to highly malignant (20-30% probability of malignancy), and

published evidence suggests that nearly all GISTs with clinical signs and symptoms leading to treatment have behavioral potential in a malignant way.<sup>[3-6]</sup> The most common areas of occurrence are up to 60% of the stomach, 25% to 40% of the small intestine and less than 10% of the colon and rectum.<sup>[7]</sup> In recent years, the histopathological diagnosis of GIST has become more accurate with the introduction of routine immunohistochemistry to identify the expression of the KIT tyrosine kinase receptor (CD 117). It is considered the most reliable phenotypic marker for GIST. Surgical excision is the preferred treatment. In the past, GISTs were notoriously insensitive to chemotherapy and radiotherapy, and there was no effective treatment available for highly malignant, distant metastatic tumors, recurrent or inoperable tumors.<sup>[8,9]</sup> Imatinibmesylate is currently used in practice in this type of lesion, as 90% of malignant lesions contain a mutation in c-kit that is specifically inhibited by this drug.<sup>[10]</sup> The clinical picture of GIST varies, but the most common symptoms are the presence of a tumor or bleeding. Most patients have unclear symptoms such as nausea, vomiting, abdominal discomfort, weight loss or early satiety. Rupture of a GIST in the peritoneal cavity is rare and causes life-threatening intraperitoneal bleeding.<sup>[11]</sup> We conducted this study to observe the demographic and clinical characteristics, morbidity and mortality of these rare tumors in our clinical environment.

## MATERIALS AND METHODS

It was a retrospective analysis of the records of patients hospitalized and treated at Bakhtawar Amin Medical and Dental college Multan for five years duration from January 2016 to January 2021. All patients with histologically and immunologically confirmed gastrointestinal stromal tumors were included in the study. The variables analyzed were patient demographics, clinical picture, treatment, and patient development in terms of mortality and morbidity.

## RESULTS

During the study period, a total of 27 patients diagnosed with GIST based on histopathology were enrolled in the study, there were 15 women and 12 were male with a male to female ratio of 1: 1.3. The mean age was 51 years (range 35-65 years).

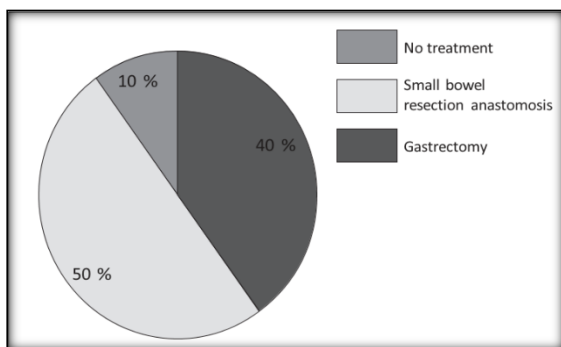
The most common symptom was abdominal pain at a rate of 60%, followed by a tumor in the abdomen, anemia due to vomiting, and decreasing weight loss. Two patients presented to the emergency department, one with intestinal obstruction and the other with upper gastrointestinal bleeding. However, the symptoms overlapped the patients [Table 1].

**Table 1: Clinical presentation of GIST**

Clinical Presentation	Number of Patient
Abdominal Pain	8
Abdominal mass	7

Vomiting	5
Anemia	4
Weight loss	4
Hematemesis	2

According to the research and surgical results, 14 patients had gastric lesions, 3 patient had duodenal lesions, 7 patients. [Figure 1]



**Figure 1: Treatment done**

The patient with duodenal lesions had multiple liver and peritoneal metastases and received chemotherapy, but after 2 cycles he developed massive upper gastrointestinal bleeding and died.

The diagnosis was confirmed by histopathological and immunohistochemical tests. All patients underwent chemotherapy after surgery. The median follow-up was 2 years. Only one patient with primary gastric cancer relapsed with a tumor in the left lobe of the liver and multiple tumors in the peritoneum one and a half years after surgery, and was referred to an oncologist for further treatment.

## DISCUSSION

GISTs are relatively rare GIT tumors, their etiology is unknown. The term stromal tumors were first introduced by Mazur and Clark in 1983 to describe mesenchymal tumors of the stomach that cannot be clearly distinguished by immunohistochemistry and fine structure.<sup>[12]</sup> Following the publication of Kindblom et al and Hirota et al., GISTs have been suggested to originate from interstitial cells of Cajal (ICCs) or stem cells differentiating to the ICC phenotype.<sup>[13]</sup>

Although many international studies on the diagnostic criteria, pathogenesis and epidemiology of GIST have been published, local studies are lacking, so we conducted this study to determine the clinico-pathological features of these tumors in our patients.<sup>[14,15]</sup> There is a clear difference in the clinical picture as GISTs may have different origins depending on the region. In our study, the small intestine in 50%, numerous lesions in 10%, and a stomach tumor in 40% of cases involving the jejunum and duodenum as isolated lesions. In the study by Claudia Muccinarin et al. 63% of tumors were found in the stomach and then in the small intestine, but this difference is not significant and may be due to the size of the sample.<sup>[16,17]</sup> Multiple GISTs in the small intestine at the same time are very rare. In addition, in our series, we had three patient with more than one lesion.

According to a study published in 2015, GIST has a mild male dominance (55%)

with an average age of 63 years. Only 2.7% of tumors occurred before the age of 21 and 9.1% before the age of 40. Similarly, Frinata et al. in their publications, they stated that the greatest incidence of GIST occurs in adulthood (fifth and sixth decades), and that young people under the age of 40 very rarely participate. This fact was not noticed in our study as 56% of our patients were women but belonged to a relatively younger age group. The median age in our population is 51 years, and 20% of patients are around 40 years old. The clinical picture of GIST is variable, but the most common symptoms are the presence of a tumor or bleeding. However, most patients have vague symptoms such as nausea, vomiting, abdominal discomfort, weight loss, or early satiety.<sup>[19,20]</sup>

In our study, the most common symptom was abdominal pain at a rate of 65%, followed by abdominal tumor, vomiting, anemia and weight loss, while upper gastrointestinal bleeding was seen in only one patient.

In our country, GISTs have slightly different clinical and demographic characteristics; however, our sample size is too small to draw definitive conclusions on this, so larger-scale multicenter studies are needed to accurately quantify the differences.

## CONCLUSION

GISTs are rare entities with a variable clinical picture, but with a favorable prognosis if recognized early. The

doctor requires a high degree of suspicion for prompt diagnosis and early treatment.

## REFERENCES

1. Von Mehren M, Heinrich MC, Shi H, Iannazzo S, Mankoski R, Dimitrijević S, Hoehn G, Chiroli S, George S. Clinical efficacy comparison of avapritinib with other tyrosine kinase inhibitors in gastrointestinal stromal tumors with PDGFRA D842V mutation: a retrospective analysis of clinical trial and real-world data. *BMC cancer*. 2021 Dec;21(1):1-9.
2. Lin Y, Wang M, Jia J, Wan W, Wang T, Yang W, Li C, Chen X, Cao H, Zhang P, Tao K. Development and validation of a prognostic nomogram to predict recurrence in high-risk gastrointestinal stromal tumour: A retrospective analysis of two independent cohorts. *EBioMedicine*. 2020 Oct 1;60:103016.
3. Benjamin G, Pratap T, Sreenivasan M, Jacob D, Thomas A, Sankar B, Itty A. Role of Multidetector CT Imaging in the Risk Stratification of Gastrointestinal Stromal Tumors (GISTs)–A Retrospective Analysis. *Journal of Gastrointestinal and Abdominal Radiology*. 2021 Jan 10.
4. Varshney VK, Gupta RK, Saluja SS, Tyagi I, Mishra PK, Batra VV. Analysis of clinicopathological and immunohistochemical parameters and correlation of outcomes in gastrointestinal stromal tumors. *Indian journal of cancer*. 2019 Apr 1;56(2):135.
5. Do IG, Jung KU, Koo DH, Lee YG, Oh S, Kim K, Kim DH, Sohn JH, Son BH, Lee SR, Shin JH. Clinicopathological characteristics and outcomes of gastrointestinal stromal tumors with high progranulin expression. *Plos one*. 2021 Jan 7;16(1):e0245153.
6. Parab TM, DeRogatis MJ, Boaz AM, Grasso SA, Issack PS, Duarte DA, Urayeneza O, Vahdat S, Qiao JH, Hinika GS. Gastrointestinal stromal tumors: a comprehensive review. *Journal of gastrointestinal oncology*. 2019 Feb;10(1):144.
7. Macdonnell CA, Telford JJ, Galorport C, Lam E, Donnellan F, Byrne M, Weiss A, Enns RA. A278 small gastrointestinal stromal tumors (gist): a retrospective analysis of eus surveillance.



- Journal of the Canadian Association of Gastroenterology. 2019 Mar 15;2(Supplement\_2):550-1.
8. Macdonnell CA, Telford JJ, Galorport C, Lam E, Donnellan F, Byrne MF, Weiss A, Enns RA. Su1218 Small Gastrointestinal Stromal Tumors (Gist): A Retrospective Analysis OfEus Surveillance. *Gastrointestinal Endoscopy*. 2019 Jun 1;89(6):AB320-1.
  9. Feng F, Fang Y, Zhang J, Zheng G, Qiao Q, Cao N, Wang H, Li B, Lei C, Wang C, Zhang C. Benefit of imatinib adjuvant therapy for patients with intermediate risk gastrointestinal stromal tumor: a multi-center retrospective analysis in China.
  10. Nishida T, Hølmekbakk T, Raut CP, Rutkowski P. Defining tumor rupture in gastrointestinal stromal tumor. *Annals of surgical oncology*. 2019 Jun;26(6):1669-75.
  11. Calderillo G, Muñoz-Medel M, Carbajal E, Córdova-Delgado M, Durán D, Retamal IN, Fernández P, Espinoza A, Salas R, De La Paz Mastretta M, Galindo H. Retrospective Analysis of Chilean and Mexican GI Stromal Tumor Registries: A Tale of Two Latin American Realities. *JCO global oncology*. 2020 Apr;6:647-57.
  12. Farag AL, Ezzeldin MM, Mosalam NA, Mohammed MM. Retrospective Analysis of Clinical Epidemiology in Gastrointestinal Stromal Tumour. *QJM: An International Journal of Medicine*. 2020 Mar 1;113(Supplement\_1):hcaa057-007.
  13. Chen T, Xu L, Dong X, Li Y, Yu J, Xiong W, Li G. The roles of CT and EUS in the preoperative evaluation of gastric gastrointestinal stromal tumors larger than 2 cm. *European radiology*. 2019 May;29(5):2481-9.
  14. Li J, Shen L. The current status of and prospects in research regarding gastrointestinal stromal tumors in China. *Cancer*. 2020 May 1;126:2048-53.
  15. Theiss L, Contreras CM. Gastrointestinal stromal tumors of the stomach and esophagus. *Surgical Clinics*. 2019 Jun 1;99(3):543-53.
  16. Chen T, Liu S, Li Y, Feng X, Xiong W, Zhao X, Yang Y, Zhang C, Hu Y, Chen H, Lin T. Developed and validated a prognostic nomogram for recurrence-free survival after complete surgical resection of local primary gastrointestinal stromal tumors based on deep learning. *EBioMedicine*. 2019 Jan 1;39:272-9.
  17. Shen Z, Chen P, Du N, Khadaroo PA, Mao D, Gu L. Pancreaticoduodenectomy versus limited resection for duodenal gastrointestinal stromal tumors: a systematic review and meta-analysis. *BMC surgery*. 2019 Dec;19(1):1-9.
  18. Atak T, Eren TT, Burcu B, Sağiroğlu J, Özemir İA, Alimoğlu O. Gastrointestinal Stromal Tumors: Retrospective Analysis of 21 Cases.
  19. Cananzi FC, Minerva EM, Samà L, Ruspi L, Sicoli F, Conti L, FumagalliRomario U, Quagliuolo VL. Preoperative monocyte- to- lymphocyte ratio predicts recurrence in gastrointestinal stromal tumors. *Journal of surgical oncology*. 2019 Jan;119(1):12-20.
  20. Wang J, Yin Y, Shen C, Yin X, Cai Z, Pu L, Fu W, Wang Y, Zhang B. Preoperative imatinib treatment in patients with locally advanced and metastatic/recurrent gastrointestinal stromal tumors: A single-center analysis. *Medicine*. 2020 Feb;99(9).

Source of Support: Nil, Conflict of Interest: None declared