

Outcome of Limbal - Conjunctival autograft in Primary Pterygium Surgery Compared with Amniotic Membrane with Fibrin Glue

Bibhuti P Sinha¹, Nilesh Mohan², Sandeep Kumar³

¹Associate Professor, RIO, IGIMS, Sheikhpura, Patna.

²Assistant Professor, RIO, IGIMS, Sheikhpura, Patna.

³Junior Resident, RIO, IGIMS, Sheikhpura, Patna.

ABSTRACT

Background: Objective: To compare the outcome of limbal-conjunctival autograft with amniotic membrane graft with fibrin glue in pterygium surgery. Study: An observational study. Place and duration: Regional Institute of Ophthalmology, IGIMS, PATNA from July 2013 to June 2014. **Methods:** A prospective study was conducted on 40 patients with pterygium. Patients were randomized on odd & even number basis. Pts. with odd numbers were subjected to limbal - conjunctival autograft & pts. with even numbers were subjected to amniotic membrane graft with fibrin glue. Patients were followed up on 1, 7, 30, 90 & 180 days post-operatively and recurrence of pterygium was seen in each group & compared with Chi-square test with significance of $p < 0.05\%$. **Results:** Recurrence of pterygium was seen in 2 pts. (10%) out of 20 pts. In limbal-conjunctival autograft group whereas it was seen in 4 pts. (20%) out of 20 patients in amniotic membrane graft with fibrin glue group. **Conclusion:** True recurrence (Grade 4) was seen in 2 (10%) out of 20 patients in LCAG group whereas it was seen in 4 (20%) out of 20 patients in AMG with fibrin glue group.

Keywords: Limbal-conjunctival autograft.(LCAG), Amniotic membrane graft (AMG) with fibrin glue., Recurrence.

INTRODUCTION

Pterygium is a triangular wing shaped fibrovascular sub-epithelial ingrowth of degenerative bulbar conjunctival tissue over the limbus on to the cornea.^[1] It remains a significant cosmetic and disabling ocular problem that may affect young, middle or old aged males or females. Key features of pterygium are its bilaterality and it does not affect vision typically. Increased prevalence with age, association with chronic light exposure, chronic irritation, dryness or previous history of trauma & no inheritance are its associated features. Currently, it is believed that the pterygium is a growth disorder characterized by conjunctivalization of the cornea due to localized ultraviolet induced damage to the limbal stem cells. The indications for surgery include reduced vision due to encroachment of the visual axis and irregular astigmatism, chronic irritation and recurrent inflammation, restriction of ocular motility and cosmesis. Several surgical modalities have been devised for pterygium. Techniques include simple excision, bare sclera technique, free conjunctival membrane technique, transplantation of pterygium in lower fornix (McReynold's technique), limbal-conjunctival autograft & amniotic membrane graft

with fibrin glue. The treatment of pterygium by the commonly employed surgical excision with bare sclera technique results in a significant recurrence leading to a cosmetic blemish with an unhappy patient. Several adjunctive therapies like conjunctival autograft, application of mitomycin-C, use of cyclosporine drug, subconjunctival injection of triamcinolone acetonide and bevacizumab along with excision of pterygium has been tried to prevent recurrence rate.^[6-9] The recurrence rates after older techniques have been very high: 50% recur within 4 months of excision and nearly all within 1 year. Currently, the most widely used techniques are limbal-conjunctival autografting. Fibrin based glues for conjunctival autografting have been used to minimize operating time and discomfort associated with suture. The structure of the amniotic membrane consists of a single layer of cuboidal nucleated epithelial cells with an underlying basement membrane and stroma. It consists of type 1 & 4 collagen. When used in eye, it offers a variety of advantageous functions which are fairly well described although exact mechanism of action is still unclear. When used on cornea, it promotes the differentiation of non-goblet cells; but when used in conjunctival reconstruction, it reduces inflammation on the ocular surface by excluding inflammatory cells with anti-protease activities and is also thought to cause apoptosis. Similarly, it has anti-angiogenic properties and also thought to maintain stem populations of the corneal epithelium and the goblet cell precursors in conjunctival epithelium. Fibrin glue

Name & Address of Corresponding Author

Dr. Nilesh Mohan,
Assistant Professor, RIO, IGIMS,
Sheikhpura, Patna, India.

Sinha et al; Outcome of Limbal - Conjunctival autograft in Primary Pterygium Surgery

is used as a sealant for corneal perforations and in eye muscle surgery. One component consists of a protein solution fibrinogen sealant: the other is a thrombin solution. Equal amount of the two components are mixed together, producing a fibrin clot. It has been shown in several studies to decrease post-operative pain and foreign body sensation as well as reduce operative time and blood loss during surgery. In addition, fibrin glue replaces Vicryl sutures or reduces the number required.

MATERIALS AND METHODS

This study was done at Regional Institute of Ophthalmology, IGIMS, Patna. A total number of 40 patients coming to this hospital with pterygium were included in this study. Patients were randomized on odd & even number basis. Patients with odd numbers were subjected to LCAG and pts. With even numbers were subjected to amniotic membrane graft with fibrin glue. According to TAN Classification, only Grade 2 & above (Encroachment on cornea >2mm) were taken into consideration. Inclusion criteria were: Highly motivated patients willing for regular follow up and pts. with no other pre-existing ocular pathology apart from pterygium. Exclusion criteria were: Pts. On multiple medications, ocular surface disorders, double pterygium, pterygium with <2mm encroachment on cornea, known case of glaucoma who could require further filtration surgery and pts. not willing to join the study or not willing to be under long follow up. Post-operative grade 4 i.e. true recurrence with fibrovascular tissue invading the cornea was taken as recurrence of pterygium. Patients were followed up for at 1, 7, 45, 90 & 180 days. The study was observational.

In limbal-conjunctival autograft, first of all conjunctival tissue was scraped from the cornea and sclera. Then, autografting was done from the supertemporal quadrant of bulbar conjunctiva. After that, the conjunctival-limbal graft was slid onto the cornea. Without lifting the tissue off cornea, it was rotated and moved into the sclera bed and a limbus-limbus orientation was maintained. Then, graft was sutured to the limbus using 10-0 nylon. In amniotic membrane graft, fibrin glue was used to appose the graft with the sclera bed without sutures. Post-operatively pts. were prescribed antibiotic-steroid eye drops.

End Point

1. Recurrence of pterygium
2. Follow up completion at 6 months

Statistical Analysis

We did statistical analysis using SPSS Software with Linear regression technique. The recurrence rate in

each group was measured and then p value of each group was calculated. p-value <0.05% was considered significant. Odds ratio in each group was also calculated. Statistical analysis showed that p value for LCAG and AMG with fibrin glue group was 0.385 & 0.411 respectively which was not significant statistically. Odds ratio was 0.176 & 0.444 for LCAG group and AMG with fibrin glue group respectively which was again not significant statistically.

RESULTS

Patients were followed up on day 1, 7, 45, 90 & 180 days and results were analysed according to post-operative grading as given below.

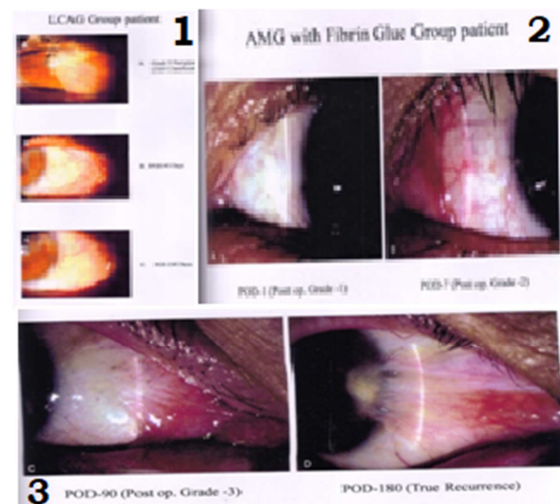


Figure 1: Grade 1: Appearance site is not different from the normal appearance. Grade 2: Presence of some fine episcleral vessels in the excised area extending upto, but not beyond the limbus and without any fibrous tissue. Grade 3: Presence of additional fibrous tissue in excised area that does not invade cornea. Grade 4: True recurrence with fibrovascular tissue invading the cornea.

On day 1, no post-operative results were noted in either group. On day 7, in LCAG group grade 1, grade 2, grade 3 & grade 4 were seen in 4(20%), 16(80%) 0(0%) & 0(0%) eyes respectively whereas it was seen in 6(30%), 14(70%) 0(0%) and 0(0%) eyes respectively in AMG group. On day 45, in LCAG group grade 1, grade 2, grade 3 & grade 4 were seen in 8(40%), 2(10%), 10(50%) and 0(0%) eyes respectively whereas it was seen in 10(50%), 1(5%), 9(45%) & 0(0%) eyes in AMG with fibrin glue group.

In LCAG, misapposition/lost graft was seen in 2 pts. and in AMG group it was seen in 1 pt. Pyogenic granuloma was not seen in any group pts. Increased IOP was seen in 1 pt. in each group which returned to normal in subsequent follow ups.

Sinha et al; Outcome of Limbal - Conjunctival autograft in Primary Pterygium Surgery

Sex distribution in two groups

	LCAG	AMG with Fibrin glue	Total
Male	15(75%)	15(75%)	30
Female	5(25%)	5(25%)	10
Total(40)	20(100%)	20(100%)	40

Recurrence of pterygium

	LCAG (20)	AMG with fibrin glue(20)	Total
Male	2(10%)	3(15%)	5
Female	0(0%)	1(5%)	1
Total	2(10%)	4(20%)	6

Complications

	Misapposition	%	Pyogenic granuloma	%	Increased IOP	%	Total
LCAG	2	10%	0	0%	1	5%	3 (15%)
AMG with fibrin glue	1	5%	0	0%	1	5%	2 (10%)
Total	3		0		2		5

On day 90, in LCAG group grade 1, grade 2, grade 3 & grade 4 were seen in 10(50%) 0(0%), 9(45%) & 0(0%) eyes respectively whereas it was seen in 10(50%), 0(0%), 9(45%) & 1(5%) eyes in AMG group. On day 180, in LCAG group grade 1, grade 2, grade 3 & grade 4(true recurrence) were seen in 10(50%), 0(0%), 8(40%) & 2(10%) eyes respectively whereas it was seen in 9(45%),1(5%), 6(30%) &4(20%) eyes in AMG with fibrin glue group.

DISCUSSION

This study showed recurrence rate of 10% (2 patients) males in LCAG group. There was 0% (0 female) recurrence in females in LCAG group. There was 15% (3 patients) recurrence in AMG with fibrin glue group males whereas it was 5% (1 female) in AMG with fibrin group females. Hence, recurrence was seen in 2 eyes (10%) and in 4 eyes (20%) in LCAG group and AMG with fibrin glue group respectively. This roughly matches with the study done by P Luanratnokorn, T Ratanopokorn & S Chuck et al (2006) in which they found recurrence rate of 12.3% in LCAG group and 25% in AMG group at 6 months follow up. This study also supports Ahmed Ozar, Sumru Yurdakul et al (2009) who in their study found recurrence rate of 14.29% and 23.08% in LCAG and AMG with fibrin glue group respectively. In a study done by P Shashikala et al (2013), recurrence rate in LCAG and AMG group was 0% & 8% respectively at 10 months follow up. Sangwan and Rammurthy et al (2006),^[11] in a study of 86 patients with 44 eyes with LCAG and 42 eyes with AMG with fibrin glue or sutures found recurrence of 9% and 13% respectively. Mean follow up was 6 months.

So, as presented in various studies there are some differences in the recurrence rate of pterygium between two groups whereas some studies have more or less same recurrence rates between two groups.^[14,15] As limbal-conjunctival autograft has relatively low recurrence rate and as is easy to

harvest hence, it is the preferred choice in pterygium surgery. Although amniotic membrane graft with fibrin glue also can be used as an alternative for large double headed pterygium or for pts. who may require glaucoma filtration surgeries.

Limitations:

However, in our study sample size of patients and time period of study was small. Most of the patients belonged to more or less same geographical and environmental conditions. Occupation was not taken in data. So, these factors could influence the surgical outcome of our study.

CONCLUSION

The observations thus made were discussed with current available literature and following conclusions were drawn from the present study which are as follows:

1. True recurrence(Grade 4) was seen in 2 (10%) out of 20 patients in LCAG group whereas it was seen in 4 (20%) out of 20 patients in AMG with fibrin glue group.
2. Recurrence rate in males in this study was higher (16.6%) whereas it was lower in females(10%).
3. p values in LCAG group and AMG with fibrin glue group were 0.385 and 0.411 respectively which were not significant statistically.
4. Odds ratio in LCAG group and AMG with fibrin glue group were 0.176 and 0.444 respectively which were not significant statistically.

Based on above conclusions, we recommend that limbal-conjunctival autograft and amniotic membrane graft with fibrin glue, both can be used as safe and effective procedure as far as recurrence rate is concerned. In our study, we did not find a significant difference in the recurrence of pterygium in these two procedures

REFERENCES

1. Qai A Faijo, Alan Sugar, Pterygium and conjunctival degenerations. In: Yanoff & Duker Ophthalmology, 3rd ed. Mosby Elsevier; 2009. p248-249
2. Sandeep Saxena. Clinical Ophthalmology: Medical & Surgical Approach. 2nd ed. Jaypee Highlights Medical Publishers; 2002. p77-82
3. Sandeep Saxena. Clinical Ophthalmology: Medical & Surgical Approach. 2nd ed. Jaypee Highlights Medical Publishers; 2002. p101-105
4. Kacabora et al, subconjunctival bevacizumab injection in the surgery of primary pterygium: comparison with intraoperative mitomycin-C Bull Socbelge Ophthalmol. 322, 7-12, 2013
5. A. kheirkhah et al, effect of intraoperative steroid injection on the outcome of pterygium surgery Eye 2013, 27(8):906-14
6. Mustafa ozsutcu et al repeated bevacizumab injection vs mitomycin-c in rotational conjunctival flap for prevention of pterygium recurrence Indian J Ophthalmol. 2014 Apr; 62(4): 407-411
7. Larissa Rossana Souza Stival et al efficacy and safety of subconjunctival bevacizumab for recurrent pterygium ArqBres Ophthalmol. 2014; 77(1):4-7
8. Mohammed Reza Razeghinezhad et al subconjunctival bevacizumab for primary pterygium excision; a randomized clinical trial. Journal of Ophthalmic and vision research 2014; vol.9, no.1
9. Razeghinezhad MR, Hosseini H, Ahmadi F, Rahat F, Eghbal H- Preliminary results of subconjunctival bevacizumab in primary pterygium excision. Ophthalmic Res 2010; 43:134-138
10. Mauro J, Foster CS- Pterygia: pathogenesis and the role of subconjunctival bevacizumab in treatment. Semin Ophthalmol 2009; 24:130-134
11. Bahar I, Kaiserman I, McAllum P, Rootman D, Slomovic A- subconjunctival bevacizumab injection for corneal neovascularization in recurrent pterygium. Curr Eye Res 2008; 33:23-28
12. Teng CC, Patel NN, Jacobson L – Effect of subconjunctival bevacizumab on primary pterygium. Cornea 2009; 28:468-470
13. Prabhasawat P, Baston k, Burkett G, Tseng SC. Comparison of Conjunctival autograft, amniotic membrane graft and primary closure for pterygium excision. (pubMed-NCBI) June 1997; 104(6), p85-89
14. P Luanratanokorn, T Ratanapokorn, O Suwan-apichon & S Chuck. Randomized controlled study of conjunctival autograft v/s amniotic membrane graft in pterygium excision. Br J Ophthalmology. 2006 Dec; 90(12), p1476-1480.
15. P Shashikala. Is amniotic membrane transplantation, an adjuvant of choice following excision of primary pterygium?. Journal of clinical ophthalmology & research. 2013; vol.1, issue 2, p91-93.

How to cite this article: Sinha BP, Mohan N, Kumar S. Outcome of Limbal - Conjunctival autograft in Primary Pterygium Surgery Compared with Amniotic Membrane with Fibrin Glue. Ann. Int. Med. Den. Res. 2015; 1(1):54-57.

Source of Support: Nil, **Conflict of Interest:** None declared