

Determination of Normal Dimensions of Pituitary Gland by Magnetic Resonance Imaging Comparison of Age and Gender Groups

Gurinder Bir Singh¹, Harjinder Singh Mann^{2*}, Arvinder Singh³, Daisy Gupta⁴, NS Neki⁵

¹Professor, Department of Radiodiagnosis and Imaging, Govt. Medical College, Amritsar, Punjab, India.

²Junior Resident, Department of Radiodiagnosis and Imaging, Govt. Medical College, Amritsar, Punjab, India. Email: drharjindermann@hotmail.com
*Corresponding author

³Professor and Head, Department of Radiodiagnosis and Imaging, Govt. Medical College, Amritsar, Punjab, India.

⁴Assistant Professor, Department of Radiodiagnosis and Imaging, Govt. Medical College, Amritsar, Punjab, India.

⁵Professor, Department of Medicine, Govt. Medical College, Amritsar, Punjab, India.

Received: November 2020
Accepted: November 2020

Abstract

Background: To determine measurements of pituitary gland dimensions in subjects with normal pituitary gland aged 1 to 70 years presenting at Radiodiagnosis and Imaging Department, Government Medical College Amritsar, Punjab. **Methods:** Total 100 subjects of different age groups (50 males and 50 females) with normal pituitary gland were evaluated using T1 weighted Magnetic resonance imaging. Mid-sagittal and coronal planes were used to measure height, width and depth of pituitary gland. Data was stratified into groups on the basis of age and sex to observe the differences. **Results:** Mean height, length, width and volume of pituitary was $5.25 \pm 1.18\text{mm}$, $8.69 \pm 2.17\text{mm}$, $9.09 \pm 2.12\text{mm}$ and $224.56 \pm 101.01\text{mm}^3$ respectively. There is significant difference in height (p value .001) and volume (p value .020) of pituitary gland among genders. Among females the mean height of pituitary was highest among 21-30 years subjects ($5.86 \pm 0.80\text{ mm}$) and lowest among 61-70 years subjects ($3.73 \pm 0.42\text{ mm}$) reflecting the hormonal changes. **Conclusions:** We have provided reference values for the normal pituitary gland dimensions in northern Indian population which will aid in assessment and diagnosis of patients with abnormalities in pituitary gland function.

Keywords: Pituitary Gland, Magnetic Resonance Imaging, Height, Length, Width, Volume.



INTRODUCTION

The pituitary gland was first described anatomically by a Belgian scientist Andreas Vesalius in 1543.^[1] Pituitary gland is the master endocrine gland of human body. The pituitary is an organ of dual origin. The anterior lobe is derived from oral ectoderm and also known as adenohypophysis and is epithelial in origin, whereas the posterior lobe is known as neurohypophysis and is derived from the neural ectoderm. The pituitary gland lies within the sella turcica which is a cup shaped depression in the sphenoid bone.^[2] The gland is located at the base of skull in the sella turcica which is a concavity within the sphenoid bone. It is inferiorly related to the hypothalamus and optic chiasma.

On plain radiographs there is a close correlation between pituitary gland and sella turcica volume when the three dimensions of sella turcica are measured. However the size of the sella does not always reflect the pituitary gland's size. Also, the size of the bony sella is not a sensitive indicator of pituitary gland abnormality, since an empty sella can lead to an enlarged fossa.^[3]

Due to superior soft tissue contrast, multiplanar capability and lack of ionizing radiation currently, MRI is the examination of choice for sellar and parasellar pathologies. In addition, MRI also provides useful information about the relationship of the gland with adjacent anatomical structures and

helps to plan medical or surgical strategy.

The appearance and size of the pituitary gland changes during life. At birth it shows high signal on T1 weighted images and is typically globular in shape. By approximately 6 weeks of age this high signal is diminished and the anterior pituitary tissue has isointense signal to brain tissue. The posterior pituitary tissue, however, retains a bright signal on T1 weighted sequences. This so-called "posterior pituitary bright spot" is a normal appearance thought to be due to the high neurophysin content (which is not present in the anterior pituitary tissue).^[3]

There is variation in pituitary dimensions in different age groups and this has been well documented. It reflects changes in the hormonal status of the gland at different phases of life. The volume of the gland changes according to the hormonal status of the individual. Usually, young adults have larger glands. Hormonally active states such as puberty and pregnancy results in increase in the volume of the gland. The pituitary height peaked at the second decade of life in both sexes, with higher values found in females. Some authors differ on this finding and have reported peak values in the third decade.^[4]

MATERIALS & METHODS

This study was conducted at Department of Radiodiagnosis and Imaging, Government Medical College,

Amritsar, Punjab. All patients with age between 1 to 70 years with no history of neuroendocrine or neuropsychiatric disease and who had normal pituitary gland on brain MRI scan, were included in the study. Out of these 100 cases were selected randomly. MRI was done on 1.5 Tesla Siemens Magnetom Aera scanner. Appropriate MR sequences and multiplanar imaging was performed for every patient using following parameters:

3D T1 weighted Image

Slice thickness: As per pulse sequence applied.

TR 520 -550 ms

TE 10-15 ms

Acquisition plane : sagittal and coronal Pituitary gland dimensions were taken as the maximum distance in mm between two surfaces lateral and supero inferior surfaces using the in built electronic calipers provided by the software. The pituitary height and depth were measured in saggital plane, using a midline image at a section where the cerebral aqueduct is visible [Figure 1]. Pituitary gland width was measured in coronal plane, at a section where pituitary stalk is visible [Figure 2]. The pituitary volume was obtained by multiplying the height (H) by depth (D) by width (W) by 0.52. The factor 0.52 is derived from sphere volume equation coefficient and cubic volume calculation.

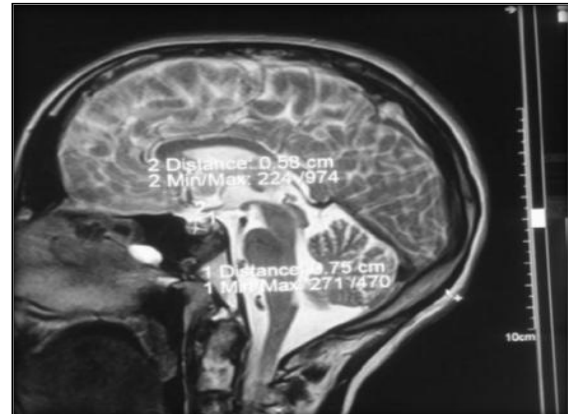


Figure 1: T1W Sagittal image showing height and length of pituitary gland

Exclusion criteria:

- Patient with pituitary gland or hormonal disorders
- Patients on hormonal therapy
- Pituitary undergone pituitary surgeries
- Patients treated by exogenous steroids/drugs like phenothiazine sulpride therapy
- Patients with pregnancy and lactation
- Any gross pathology of pituitary gland noted during the scan
- Patients with post-menopausal estrogen and progesterone replacement were excluded from the study.
- The study excluded patient having history of claustrophobia.
- Patient having metallic implants insertion, cardiac pacemakers and metallic foreign body in situ were excluded from study.

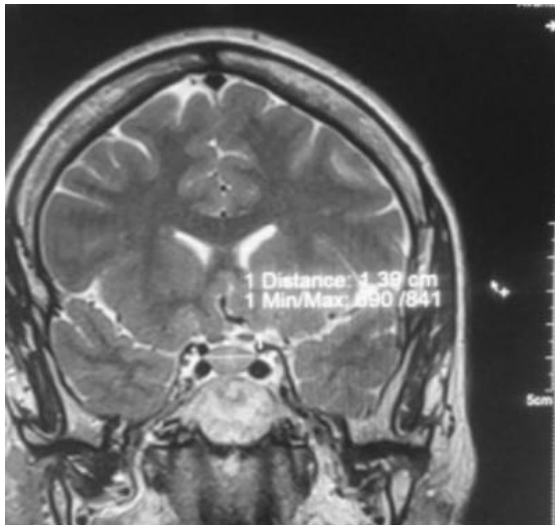


Figure 2: T1W Coronal Image showing width of pituitary gland.

Statistical analysis:

SPSS (Statistical package for social science) software version 22.0 was used. The patients were stratified on the bases of age and sex. Quantitative data was expressed as means and standard deviation and was illustrated using tables and graphs. The relationship between pituitary gland dimensions with age groups and gender was evaluated. P-value less than 0.05 was considered to indicate statistically significant difference.

RESULTS

In this study, out of 100 subjects, 50 were males and 50 were females. All our subjects were aged between 1 to 70 years. The youngest subject was 1-year-old and oldest was 70 years old. They were stratified into age groups with an interval of 10 years.

Table 1: Age and sex distribution of patients

Age (years)	N	%
0-10	25	25.0
11-20	16	16.0
21-30	15	15.0
31-40	13	13.0
41-50	18	18.0
51-60	7	7.0
61-70	6	6.0
Total	100	100.0

Maximum number of patients were in the age group of 1-10 years (25 patients) and minimum were in the age group of 61-70 years (6 patients).

In our study 50% were males and 50% were females. Equal proportion of males and females were included in the study.

Mean height, length, width and volume of pituitary was 5.25 ±1.18mm, 8.69±2.17mm, 9.09±2.12mm and 224.56±101.01mm³ respectively. [Table 2]

There was no significant difference between the length and width of the pituitary gland between the two genders. However, there is significant difference in height (p value .001) and volume (p value 0.020) of pituitary gland among genders. [Table 3]

In our study mean pituitary volume was highest in the age group 31-40 years (283.31±88.87) mm and lowest in the age group 0-10 years (141.91±93.98) mm. However there was highly significant difference in volume of pituitary gland with respect to age distribution (P value 0.001). [Table 4]

Table 2: Mean Height, Length, Width and Volume of Pituitary Among Subjects of the Study.

	Mean	Median	SD	Minimum	Maximum
Height	5.250	5.30	1.189	2.50	8.00
Length	8.695	9.30	2.178	1.10	13.00
Width	9.097	9.00	2.129	3.60	15.00
Volume	224.563	240.59	101.01	18.26	421.56

Table 3: Pituitary height, length and width in different genders.

	Total mean \pm SD	Male mean \pm SD	Female mean \pm SD	P value
Height	5.250 \pm 1.189	5.63 \pm .97	4.87 \pm 1.27	0.001*
Length	8.695 \pm 2.178	8.81 \pm 2.22	8.58 \pm 2.15	0.606
Width	9.097 \pm 2.129	9.49 \pm 1.81	8.71 \pm 2.36	0.066
Volume	224.563 \pm 101.01	247.86 \pm 93.83	201.26 \pm 103.46	0.020*

*p<0.05; Significant

Table 4: Volume of pituitary comparison with respect to age group.

Age (years)	Volume		
	Mean	SD	Median
0-10	141.91	93.98	96.53
11-20	247.73	111.98	279.67
21-30	272.49	96.36	308.88
31-40	283.31	88.87	289.29
41-50	238.38	77.89	256.64
51-60	222.82	40.60	227.64
61-70	220.64	44.74	216.57

DISCUSSION

Despite its small size the pituitary gland plays a major role in neuroendocrine regulation. Evaluation of pituitary height and volume is of great diagnostic and prognostic significance.

Mean height of pituitary in our study was 5.25 \pm 1.18 mm, with range between 2.50 mm to 8.00 mm irrespective of age groups and sex of subjects. The difference in the mean pituitary height was significant among genders with P value 0.001. Mean height of pituitary

was 5.63 \pm 0.97mm and 4.87 \pm 1.27mm in males and females respectively. Among females, the mean height of pituitary was highest among 21-30 years subjects (5.86 \pm 0.80) mm and lowest among 61-70 years subjects (3.73 \pm 0.42) mm. The results of this study are comparable to study in Indian population by Naik D et al,^[5] (5.5 \pm 1.6mm and 6.0 \pm 1.5mm for males and females), and also in studies by Burghio S et al,^[6] (5.6 \pm 0.74mm and 5.8 \pm 0.67 mm for males and females), Sinclair J et al,^[7] (5.52 \pm 0.72 for males and 5.66 \pm 0.96 for females), Cemdenk C et al,^[8] (5.7 \pm 0.2 for males and 6.1 \pm 0.1 for females), Tsunoda A et al,^[4] (4.93 \pm 1.0

for males and 5.35 ± 1.3 for females) and Ikram MF et al,^[9] (5.9 ± 1.0 for males and 6.3 ± 1.4 for females), respectively.

Mean length of pituitary in our study is 8.69 ± 2.17 mm, with range between 1.10 to 13.0 mm irrespective of age groups and sex of subjects. Mean length of pituitary was 8.58 ± 2.15 mm and 8.81 ± 2.20 mm for females and males respectively. There is no significant difference in the mean pituitary length among genders with p value .606. The results are comparable to studies conducted by Ibinaiye PO et al,^[3] (10.59 ± 1.71 mm and 10.49 ± 1.57 mm), however the analysis done by Bughio S et al,^[6] (12.1 ± 2.26 mm and 12.5 ± 2.21 mm), Sinclair J et al,^[7] (11.18 ± 1.1 mm and 11.09 ± 1.01) and Naik D et al,^[5] (14 ± 1.5 mm and 10.1 ± 1.4 mm) have higher values.

Mean width of pituitary in our study was 9.09 ± 2.12 mm, with range between 3.60 mm to 15.00 mm, irrespective of age groups and sex of subjects. Mean width of pituitary was 8.71 ± 2.36 mm and 9.49 ± 1.81 mm for females and males respectively. The difference in the mean pituitary width among genders with P value 0.066 was not found to be significant. This study results are comparable as reported by Badawi K et al,^[10] (9.60 mm and 11.77 mm for males and females) respectively, Ibinaiye PO et al,^[3] (9.08 ± 2.59 mm and 9.21 ± 1.86 mm) for males and females respectively) and Sinclair J et al,^[7] (11.57 ± 1.42 mm and 11.91 ± 1.61 mm for males and females respectively).

Mean volume of pituitary in our study was 224.563 mm³ with range between 18.26 mm³ to 421.56 mm³ irrespective of age groups and sex of subjects. The difference in the mean pituitary volume among genders with p value 0.02 was significant statistically. The results of study are comparable with study done by Dr. Tapasvi C et al,^[11] (219 and 244 for males and females) respectively.

We have observed that among the four parameters that we studied in relation to the pituitary gland, pituitary height changed most remarkably with respect to age and sex.

Limitations

Our study is limited by selection bias due to the fact that the high cost of the examination did not permit us to study normal volunteers. Hence, patients with other conditions, but without clinical or imaging evidence of neuroendocrine or neuropsychiatric pathology were selected. Small size of study group is another limitation.

CONCLUSION

In this study, the reference value of normal size of pituitary gland in various genders and age groups has been standardized. Any variation in size will help the clinician to deduce any pathology and make early diagnosis and plan adequate this will be avoid unnecessary suffering to patients.



REFERENCES

1. Sahni D, Jit I, Bhansali A. Weight and dimensions of the pituitary in north western Indians. *Pituitary*. 2006;9(1):19-26.
2. Evanson J. Radiology of the Pituitary. *Endotext*. 2020;89(2):574-80.
3. Ibinaiye PO, Olarinoye-Akorede S, Kajogbola O, Bakari AG. Magnetic resonance imaging determination of normal pituitary gland dimensions in Zari Northwest Nigerian population. *J clin imag sci*. 2015;5:29-33.
4. Tsunoda A, Okuda O, Sato K. MR height of the pituitary gland as a function of age and sex: especially physiological hypertrophy in adolescence and in climacterium. *American Journal of Neuroradiology*. 1997;18(3):551-4.
5. Naik D, Reddy P, Srinath MG, Kumar AA. Pituitary Gland Assessment by MR Volumetry in the Normal Indian Adolescent Population. *International Journal of Medical Imaging*. 2015;3(6):105-9.
6. Bughio S, Ali M, Mughal AM. Estimation of pituitary gland volume by mri and its correlation with sex and age. *PJR*. 2017;27(4):1-5
7. Sinclair J, Kanodia AK, Schembri N, Sudarshan T, Guntur P. MRI measurement of normal pituitary size using volumetric imaging in Scottish patients. *Curr Trends Clin Med Imag*. 2017;1(3):63-9.
8. Denk CC, Önderoglu S, Ilgi S, Gürcan F. Height of normal pituitary gland on MRI: differences between age groups and sexes. *Okajimas folia anatomica Japonica*. 1999;76(3):81-7.
9. Ikram MF, Sajjad Z, Shokh I, Omair A. Pituitary height on magnetic resonance imaging observation of age and sex related changes. *JPMA. The Journal of the Pakistan Medical Association*. 2008;58(5):261.
10. Badawi K, Algadir OA, Seddeg Y. Radiological Study of the Normal Pituitary Gland among Sudanese population. *IOSR Journal of Dental and Medical Sciences*. 2018;17(1):64-7.
11. Tapasvi C, Parmdeep S, Isha T, Anirudh S, Sukhpreet
12. S. Quantitative determination of normal anterior pituitary gland dimensions in North Indian population by magnetic resonance (MRI) *Indian journal of Basic and Applied Medical Research*. 2017;6(2):535-42.

Source of Support: Nil, Conflict of Interest: None declared