

Primary Non- Hodgkin's lymphoma of ovary – An uncommon ovarian mass in a nine year old child.

Mustafa Ali¹, Monika Singh¹, Udit Chauhan², A. Kumar³

¹Resident, Department of Pathology, King George Medical University, Lucknow, Uttar Pradesh, India

²Senior Resident, Department of Radiology, GB Pant Institute of Post Graduate Medical Education and Research, New Delhi, India.

³Professor, Department Of Pathology, King George Medical University, Lucknow, Uttar Pradesh, India.

ABSTRACT

Primary lymphomas of the ovary are extremely rare; their definitive diagnosis requires correlation of the clinical, radiological, and pathological findings. Secondary ovarian lymphomas are well known. We report a case of primary Non-Hodgkin's Lymphoma of ovary in a 9 year old female child with unilateral involvement, which was managed by salpingo-oophorectomy and chemotherapy. Computed tomography revealed a large abdominal pelvic mass, without associated loco-regional or distant lymphadenopathy. The diagnosis of malignant lymphoma was established by histological study of the excised tissue. The case is rare because of its primary nature and location in this age group. Prognosis of primary ovarian lymphoma is the same as that of other primary nodal lymphomas. The authors aim to highlight the importance of considering this as a differential diagnosis in appropriate clinico-radiological scenario.

Keywords: Child, Non- Hodgkin's Lymphoma, Ovary, Primary

INTRODUCTION

Lymphoma of ovary occurring as a late manifestation of disseminated nodal disease is well known and is invariably of the Non-Hodgkin's type. But primary ovarian lymphomas are rare.^[1] Primary ovarian Non-Hodgkin's lymphoma accounts for 0.5% of all Non-Hodgkin's lymphomas and 1.5% of all ovarian neoplasms.^[2] Gynaecological malignant conditions account for approximately 3% of all malignancies in children.^[3] The incidence of ovarian tumors in childhood account for only 1% of paediatric malignancy.^[4] We present a case of primary ovarian Non-Hodgkin's lymphoma, in a 9 year old child, which was managed by surgery and chemotherapy.

CASE REPORT

A nine year old female child presented with one month history of abdominal pain and lump in left iliac fossa extending upto hypogastrium. Haematological profile was unremarkable. Serum CA-125 and Lactate Dehydrogenase (LDH) were raised measuring 242U/ml (<25U/ml) and 1218 IU/l (180–460 IU/l) respectively. Computed Tomography of abdomen revealed a large (8x7cm) well defined lobulated homogeneously enhancing soft tissue attenuation mass lesion in the abdomino-pelvic region.

No loco regional and distant lymphadenopathy was present. Of the remarkable significance, the left ovary was not visualised neither on CT nor on sonographic examination thereby ascertaining the origin of mass from left ovary. Based on the radiological findings and considering the age of the patient, an initial diagnosis of dysgerminoma of left ovary was suggested. An exploratory laparotomy followed by a left salpingo-oophorectomy was performed. No tumour extension or omental deposition was seen. The right ovary and uterus were preserved in consideration of the patient's age. Specimen was sent for histopathological examination. Specimen was received as single, firm, lobulated, ovarian mass measuring 8x7x5 cm in size. Cut section revealed greyish white tumour. Microscopic examination of ovarian mass revealed replacement of ovarian tissue by diffuse sheets, trabeculae and cords of monotonous medium-sized cells intersected by fibro vascular septa. The cells had scant cytoplasm and cleaved nuclei, clumped chromatin with inconspicuous nucleoli. Based on histomorphology differentials of NHL, dysgerminoma, teratoma, granulose cell tumour and metastatic carcinoma was considered. On immunohistochemistry, the cells were positive for LCA, CD20, and negative for Cytokeratin, Alpha Fetoprotein, Inhibin and CD3 .A diagnosis of Non-Hodgkin's lymphoma was rendered. Postoperative bone marrow and radiological studies were done for staging which were negative. Based on the complete work-up, a final diagnosis of primary Non-Hodgkin's lymphoma of left ovary without any dissemination was suggested with clinical Ann Arbor stage IE (A).

Name & Address of Corresponding Author

Dr. Monika Singh
Resident, Department Of Pathology
King George Medical University
Lucknow, Uttar Pradesh
India
E mail: mona.nov10@gmail.com

DISCUSSION

Malignant lymphomas frequently involve the ovaries but primary lymphomas of ovary are extremely rare, accounting for 0.5% of all Non-Hodgkin's lymphomas (NHL) and 1.5% of all ovarian neoplasms.^[1,2] Primary ovarian NHL present more often with pelvic complaints and are usually larger in size than secondary lymphomas at the time of presentation. Burkitt's lymphoma and diffuse large B-cell lymphoma are the most common histologic types of primary NHL.^[5] The differential diagnosis of ovarian NHL includes other small round cell tumours like rhabdomyosarcoma, teratoma, neurogenic tumor, glanulosa cell tumor and dysgerminoma. An exact diagnosis can only be confirmed by histological examination of the tumor tissue.^[6, 7] Origin of primary lymphomas in the ovary is debated as it requires the presence of pre-existing benign lymphoid infiltrate in the ovary. Few case series conducted studies on oophorectomy specimens and confirmed immunohistochemically that ovaries contain scattered lymphocytes or small lymphoid aggregates.^[8] They suggested that the reactive lymphocytes can secondarily populate the ovary in response to various ovarian lesions and on rare occasions these lymphocytes may undergo malignant change and give rise to primary ovarian lymphoma. The reactive ovarian lesions giving rise to such a phenomenon include PID, endometriosis, benign/malignant neoplasm, the lutein, follicular and surface inclusion cysts. However, not all the cases show such reactive changes.

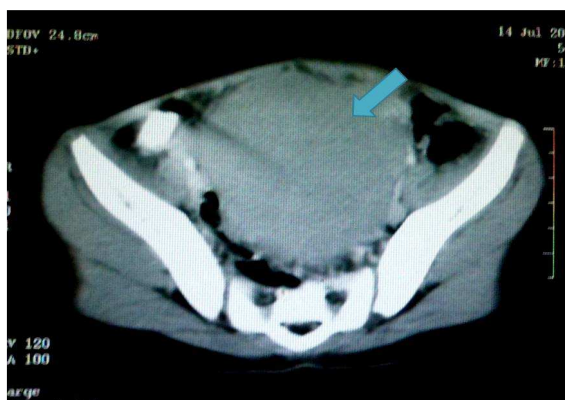


Figure 1: Axial contrast enhanced CT of pelvis through the porto-venous phase reveals a large (approximately 8x7cm), lobulated, homogeneous mass lesion with mild enhancement occupying the pelvis. No evidence of any necrosis/ calcification is evident. Left ovary was not seen separately from the mass.

There are cases in which there was no clinical or histological evidence of inflammation was seen as in our case.^[5] Skodras et al.^[8] have proposed that the

designation of an ovarian lymphoma as primary should require the following: (1) There is presence of an ovarian mass, confined to one or both ovaries; and in these cases the lymphoma should be considered primary ovarian even if there is microscopic involvement of the contiguous lymph nodes. (2) Extensive staging procedures show no evidence of lymphoma elsewhere in the body.

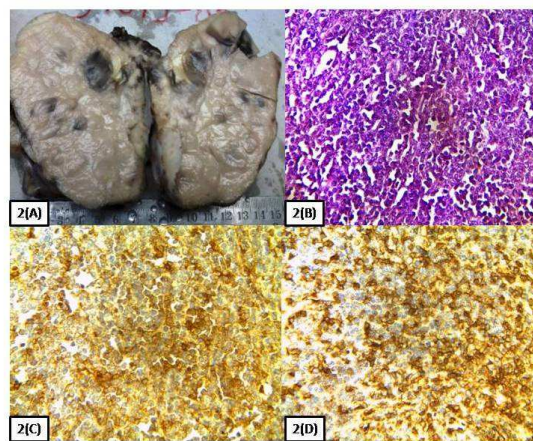


Figure 2: (A) Gross of tumour mass replacing whole of the ovarian parenchyma (B) Hematoxylin and eosin-stained section of the ovarian mass revealed monotonous population of tumour cells arranged in cords and trabeculae. Cells were round to oval in shape with hyperchromatic nucleus inconspicuous nucleoli and scant cytoplasm. These tumour cells were strongly positive for leucocyte common antigen LCA(C) and CD20 (D). Magnifications: 400× in B, C, and D.

However, Paladugu et al.,^[9] thought the criteria were insufficiently stringent and mandated that there should be a disease-free interval of at least 60 months after the oophorectomy. Clinical staging of lymphomas is based on a combination of clinical, radiologic, and surgical findings, following the Ann Arbor staging system. Currently recommended approaches for staging consists of routine physical examination, laboratory analysis, chest X-ray, cross-sectional imaging of the chest, abdomen, and pelvis, bone marrow biopsy, and lumbar puncture (in selected cases of NHL) for any stage beyond clinical stage IA. Fluorine-18 fluorodeoxyglucose positron emission tomography (18F-FDG PET) is included in the most recent recommendations for pre-treatment evaluation, particularly in the setting of equivocal results (4). As in our patient all the criteria were fulfilled for a primary lymphoma and clinical staging was done, a diagnosis of primary ovarian NHL with Ann Arbor stage IE (A) was considered.

To summarise, primary ovarian Non-Hodgkin's lymphoma are rare especially in paediatric age. Pain and abdominal lump are the most common

presentation. Prognosis depends on the size of the tumor, stage and histological subtype. Conservative surgery with chemotherapy is the mainstay of management. Primary lymphomas carry a good prognosis compared to secondary lymphomas of ovary. Thus, through above case report the authors wish to create awareness amongst the clinicians, radiologists and pathologists alike that primary ovarian lymphoma can also be encountered in the pediatric age group and should be promptly identified so as to ascertain expeditious management.

REFERENCES

1. Monterosso V, Jaffe ES, Merino MJ, Medeiros LJ. Malignant lymphomas involving the ovary: A clinicopathologic analysis of 39 cases. *Am J Surg Pathol* 1993; 17:154-70.
2. Dimopoulos MA, Daliani D, Pugh W, Gershenson D, Cabanillas F, Sarris AH. Primary ovarian non-Hodgkin's lymphoma: Outcome after treatment with combination chemotherapy. *Gynecol Oncol* 1997; 64: 446-50.
3. Singhal SR, Rattan KN, Nanda S, Singhal SK. A 9-Year Review of ovarian masses in Children and Adolescents. *J Gynecol Surg* 2008; 24: 113-6.
4. Andres MM, Costa E, Canete A, Moreno L, Castel V. Solid ovarian tumors in childhood: A 35-year review in a single institution. *Clin Transl Oncol* 2010; 12: 287-91.
5. Vang R, Medeiros LJ, Fuller GN, Sarris AH, Deavers M. Non-Hodgkin's lymphoma involving the gynecologic tract: a review of 88 cases. *Adv Anat Pathol* 2001; 8: 200-217.
6. Roth H, Daum R, Benz K, Schafer K. Rare ovarian tumors in childhood. *Eur J Pediatr Surg* 1991; 1: 210-215.
7. Osborne BM, Robboy ST. Lymphomas or leukemia presenting as ovarian tumors, an analysis of 42 cases. *Cancer* 1983; 52: 1933-1946.
8. Skodras G, Fields V, Kragel PJ. Ovarian lymphoma and serous carcinoma of low malignant potential arising in the same ovary: A case report with review of literature of 14 primary ovarian lymphomas. *Arch Pathol Lab Med* 1994; 118:647-503.
9. Palagadu RR, Bearmen RM, Rappaport H, Fox H. Malignant lymphoma with primary manifestation in the gonad: A clinicopathological study of 38 patients. *Cancer* 1980; 45:561-71.

How to cite this article: Ali M, Singh M, Chauhan U, Kumar A. Primary Non- Hodgkin's lymphoma of ovary – An uncommon ovarian mass in a nine year old child. *Ann. Int. Med. Den. Res.* 2015;1(3):358-60.

Source of Support: Nil, **Conflict of Interest:** None declared