

Lipoma of the Perineum: A Case Report

Preeti Amit Kale¹

¹Associate Professor, Chief Consultant Gynecologist, B.J. Medical College and Sasoon General Hospital, Pune, Maharashtra, India.

ABSTRACT

Lipomas may occur in almost any part of the body in which there are deposits of normal fat. Occasionally it may get developed in perineal or perianal region. The site generally causes severe discomfort to the patient to the extent to hamper day to day activity. It should be thoroughly investigated and excised completely. Its association of urological abnormalities and close a proximity to anal and vaginal area should be always kept in mind.

Keywords: Lipoma, Perineum, Tumors.

INTRODUCTION

Lipomas may occur in almost any part of the body in which there are deposits of normal fat. They generally develop where these deposits are greatest, and it is only rarely that they are found in parts where little fat naturally exists. Grossly, histologically and chemically, lipomas resemble normal fatty tissue. They are more compact on the cut surface than fat and the lobules are smaller. Practically all fatty tumors have a fibrous capsule and are divided into lobules by septums.^[1] In most cases, the capsule and its branches are quite delicate, but they may be thick and strong, particularly following inflammatory changes. They then acquire density and toughness similar to that of fibrous tumors.^[2] There is undoubtedly some physiologic difference between fat of lipoma and normal fat. Perineal lipomas are rare and may have deeper or inter-sphincteric extensions.^[3] Preoperative evaluation to rule it out is a necessary part of the work up for any perianal lipoma.

CASE REPORT

A 20 yrs old unmarried girl came to the gynecology outpatient department with chief complaints of swelling in the perineal region according to her the swelling was observed since two months which got suddenly increased after her menstruation [Figure 1]. It was 8th day of her menstrual cycle. On examinations the swelling was present 3cm laterally to fourchette. It was painless and without any signs of inflammations.

Name & Address of Corresponding Author

Preeti Amit Kale¹
Associate Professor,
Chief Consultant Gynaecologist,
B.J. Medical College and Sasoon General Hospital, Pune
Maharashtra
Email: drpreetikale@rediffmail.com

The swelling was firm in consistency. She was advised to undergo special tests like ultrasonography and MRI pelvis. All the investigations revealed the swelling to be encapsulated and isolated and without any extensions [Figure 2]. The decision of excision biopsy was taken [Figure 3,4]. It was removed under short general anaesthesia. Skin incision was closed with un-absorbable sutures which were removed on post-operative day 10. Post operatively patient was started on full diet and was given oral antibiotic prophylaxis for 3 days. Post-operative recovery was uneventful. Histo-pathological examination confirmed the diagnosis of lipoma.

DISCUSSION

Perineal lipoma is a very rare site of lipoma to occur which leads to difficulty insitting for the patient and may interfere with defecation. Inter-sphincteric extension or obstruction by the swelling may occur if it is close to anal sphincter. If it is in close a proximity to vagina may lead to dyspareunia or hematocolpos.^[4,5]

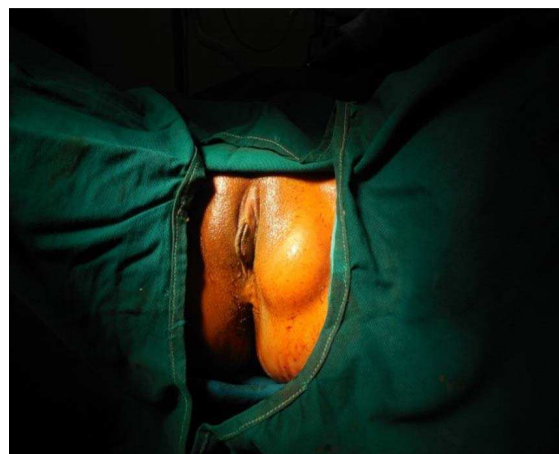

Figure 1: Swelling in perineal region

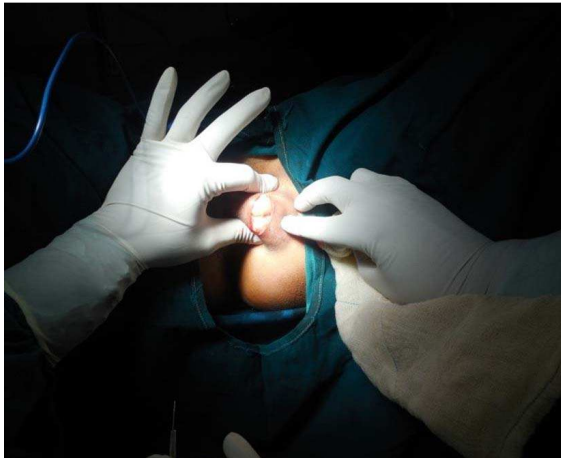


Figure 2: Isolated swelling

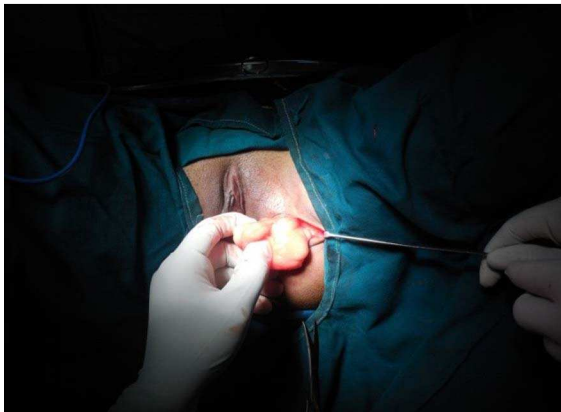


Figure 3: Lipoma is excised

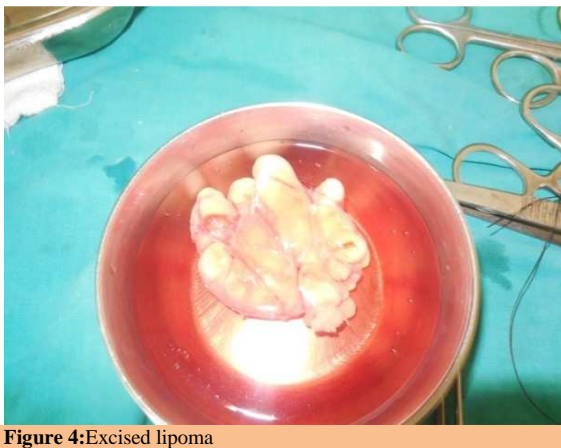

Figure 4: Excised lipoma

Takayashu et al. believed that perineal lipomas resulted from pluripotential anlage of labio-scrotal swelling from a teratoid structure.^[6] Thorough investigation in the form of local ultrasound, FNAC, and if indicated MRI of the pelvis is required to

know the exact extent and inter-spincteric, vaginal extension.

Sule et al classified accessory labio-scrotal folds by the presence or absence of an associated perineal lipoma, because cases with or without a perineal lipoma may be associated with other genitourinary and anorectal anomalies that require diagnostic imaging for their detection and evaluation.^[7] Management involves preoperative bowel preparation and elliptical incision to visualize the lipomatous swelling. Carefully it should be dissected away from the perianal or labial fat and relentlessly attempting to save the anal sphincters and adjuvant soft tissue.^[8] This swelling should be completely enucleated with all the pseudopodia.^[9]

CONCLUSION

Perineal lipoma is a rare site of lipomas that warrants removal as it is a reason of constant discomfort for the patient. Preoperative evaluation is necessary to know the extent and type of lesion. MRI is a best modality to rule out inter-spincteric extension of the tumors and presence of concurrent urological anomalies.

REFERENCES

1. Enzinger FM, Weiss SE, Benign lipomatous tumour. In: Soft tissue tumours, 3rd edn. St. Louis, Mosby, 1995, pp 381.
2. Adair FE, Pack GT, Farrior JH. Lipoma. Am J Cancer 1982;16:1104-6.
3. TurcCarel C, Dal Cin P, Boghosian L. Breakpoints in benign lipoma may beat 12q13 or 12q14. Cancer Genet Cytogenet, 1988;36:131.
4. Goldfarb M, Finelli R, McCally D, Firoozi T. Benign perineal masses in the male. Int Surg, 1977;62(10):541-2.
5. Musierowicz A, Matejczuk A. Giant perineal lipoma. Pol Przegl Chir, 1977,49(6a):757-8.
6. Lamm DL, Kaplan GW. Accessory and ectopic scrota. Urology, 1977;9:149-53.
7. Sule JD, Skoog SJ, Tank ES. Perineal lipoma and the accessory labioscrotal fold: an etiological relationship. J Urol, 1994;151(2):475-7.
8. Goldfarb M, Finelli R, McCally D, Firoozi T. Benign perineal masses in the male. Int Surg, 1977;62(10):541-2.
9. Gregoire FM, Smas CM, Sul HS. Understanding adipocyte differentiation. Physiol Rev, 1998;78:783-809.

How to cite this article: Kale PA. Lipoma of the Perineum: A Case Report. Ann. Int. Med. Den. Res. 2015;1(3):348-49.

Source of Support: Nil, **Conflict of Interest:** None declared