

## Outcome of Discectomy by Fenestration Technique in Prolapsed Lumbar Intervertebral Disc.

Mohammad Aslam<sup>1</sup>, Fauzia Rehman Khan<sup>2</sup>, Najmul Huda<sup>3</sup>, Ajay Pant<sup>3</sup>, Mohd. Julfiqar<sup>1</sup>, Akshat Goel<sup>4</sup>

<sup>1</sup>Assistant Professor, Department of Orthopaedics, TMMC&RC, Moradabad, India.

<sup>2</sup>Associate Professor, Department of Anaesthesia, TMMC&RC, Moradabad, India.

<sup>3</sup>Professor, Department of Orthopaedics, TMMC&RC, Moradabad, India.

<sup>4</sup>Senior Resident, Department of Orthopaedics, TMMC&RC, Moradabad, India.

### ABSTRACT

**Background:** Prolapsed disc is the major cause of low backache with radiculopathy. Many different techniques, from extensive laminectomy to minimal invasive endoscopic surgeries have been described with aim to minimize the possibility of damage to other structures. **Methods:** Twenty patients with clinical symptoms and signs prolapsed disc having radiological confirmation by MRI were subjected to disc excision by fenestration technique. **Results:** The follow-up analysis as per Modified Mac Nab's Criteria showed excellent results in 15 patients, good in 4 patients and fair in 1. **Conclusion:** Discectomy by fenestration offers sufficient and adequate exposure for lumbar disc excision. Advantages over conventional discectomy are smaller incision, lesser morbidity, shorter convalescence, early return to work and comparable overall results. It can even be performed in peripheral centers where recent microscopic and endoscopic facilities are not available.

**Keywords:** Discectomy, Fenestration, Prolapsed Lumbar Intervertebral Disc (PIVD).

### INTRODUCTION

In Orthopaedic practice patients having lesions of lumbosacral region causing low backache with radiculopathy are not uncommon since the beginning of recorded history. Low back pain due to lumbar disc prolapse is the major cause of morbidity affecting mainly the young adults. Lifetime incidence of low back pain is 50-70% with incidence of radiculopathy more than 40%. However clinically significant radiation due to lumbar disc prolapse occurs in 4-6% of the population.

The degeneration of the disc results from many factors and can lead to prolapse into the intervertebral foramen, particularly at L4-L5 & L5-S1 level. The L3-L4 & L2-L3 account for the majority of remaining herniation. Detailed history, clinical examination supplemented by relevant radiological investigations can differentiate herniated lumbar disc prolapse from other causes of low back pain and sciatica. The outcome of surgery depends on many factors, most importantly careful selection of patients.

The success rate after lumbar discectomy reported in the literature varies considerably from 46% to 90%. In the past various authors have attributed this variability to the surgical technique. It is apparent, however, that a more common reason is faulty patient selection criteria.

The technique of lumbar discectomy has undergone significant modifications. Originally, a wide laminectomy was performed in an attempt to remove as much disc material as possible.<sup>[1-3]</sup> This more radical surgery is no longer common as because extensive laminectomy may cause destabilization of spine later. Love described extradural removal of herniated disc and devised inter-laminar fenestration for treatment of lumbar disc prolapse.<sup>[4]</sup> In 1982, Spengler described limited disc excision, only the ligamentum flavum and if necessary small portion of lamina inferiorly is removed to expose the prolapsed disc space and the extruded disc were removed.<sup>[5]</sup> Machenson advocated removal of only sequestered and extruded loose disc fragments, with the minimal removal of tissue fragments from the intervertebral space.

The advantage of limited lumbar disc excision by fenestration technique is a decrease in the incidence of postoperative spinal instability, decreased manipulation of the neural elements and subsequent peri-neural fibrosis. In addition limited disc excision lessens the likelihood of penetration of the anterior annulus with potential injury to the viscera. Furthermore, the recent techniques like Percutaneous Lumbar Disc Decompression (PLDD), Percutaneous

#### **Name & address of Corresponding author**

Dr. Mohammad Aslam  
Assistant Professor,  
Department of Orthopaedics,  
TMMC&RC, Moradabad  
UP, India  
E mail: dr.mohd.aslam@gmail.com

Endoscopic Lumbar Discectomy (PELD) and Yeung Endoscopic Spine System (YESS) need lots of expertise, experience and expensive equipments which are not available at every center.<sup>[6,7]</sup> Hence disc excision through fenestration is the procedure which can be performed by majority of orthopedic surgeons even in small peripheral centers.

This study is performed to assess the results of limited lumbar disc excision through inter-laminar fenestration in patients fulfilling specific criteria.

## **MATERIALS AND METHODS**

The study design was prospective and carried out on twenty patients attending the out patient department and casualty with low backache and radiculopathy. Clinical history, physical examination and neurological examination of the patients were done to assess the presence of signs of nerve root tension, neurological deficit and involvement of bladder or bowel [Table 1&2]. Calculation of Mc Cullough's score based on Mc Cullough's criteria was done.<sup>[8,9]</sup> Radiological evaluation was done to rule out any bony pathology of spine.

MRI was done to evaluate the level and type of disc prolapse and staging of disc prolapse was done according to Eismont and Currier grading.<sup>[10]</sup>

The patients were initially given a trial of conservative management for at least six weeks, which consist of bed rest, pelvic traction, analgesic and diathermy. The patients who fail to improve on conservative treatment were subjected to surgical treatment. Patients for surgical management by discectomy through fenestration were selected on basis of Mc Cullough's criteria. The patients were treated surgically by discectomy through fenestration technique. Patients were taken up for surgery after the pre-anesthetic check up was done. Surgery was done under general anaesthesia with induced hypotension. Patients were kept on spinal frame or over bolsters to relieve the abdominal compression. The vertebral level was identified with help of marker coin and marker X-rays or with help of image intensifier when available. The skin and para spinal muscles were infiltrated with 1 in 200000 diluted adrenaline to decrease the bleeding. A posterior longitudinal mid line incision of 2.5 cm long was given over the level of disc to be removed. The skin and subcutaneous tissue was incised. The supraspinous ligament was then incised by subperiosteal dissection; and stripping of the muscle from the spine and lamina of the vertebra on the side of the lesion was done. Muscles were retracted using self-retaining retractor. Packing the wound achieves haemostasis was done.

Inter-laminar space was located and Ligamentum flavum was identified and incised, lower 3rd part of upper lamina or upper 3rd of lower lamina was cut to enlarge the fenestration for a clear view.

The dura was retracted medially with the help of dural retractors, the nerve root and disc were identified with utmost care. The bulging disc was felt and PLL was identified. Cruciate incision was given in the PLL. The sequestered and extruded loose disc fragments were removed with the help of discectomy forceps, with minimal removal of tissue fragments from the intervertebral space. The exiting nerve roots were cleared of compression in all cases. Meticulous hemostasis was achieved with bipolar coagulation. Incision was closed in layers over a suction drain.

Post operatively patient was made to stand up and ambulate on the next day; prolonged sitting and flexion were avoided. Patient were discharged within a week from the hospital. Suture removal was done at two weeks. Heavy weight lifting, forward bending and stooping prohibited for 6 weeks. Back strengthening exercises were advised from second week. Patient was advised to return to original occupation after 8-12 weeks. Patients were called at 1 month, 3 months, 6 months, 12 months of surgery and were clinically evaluated and final patient rating was done in accordance with modified Mac Nab's criteria.<sup>[11,12]</sup>

## **RESULTS**

Out of 20 patients, there were 12 males and 8 females. The age of the patients varied from 26 to 70 years with the mean age of 43.3 years. Fourteen patients were sedentary workers while rest were light workers. Onset was gradual in seventeen patients, while three patients had sudden onset. Claudication distance was less than hundred meters in sixteen patients. The most common level of involvement was L4-L5 followed by L5-S1. On MRI, disc protrusion was commonest finding followed by disc bulge, disc sequestration and disc extrusion [Figure 1, 2]. Fourteen patients had unilateral radiculopathy while six had bilateral symptoms. The duration of average post-op hospital stay was 7.2 days.

The results of the surgery were analyzed on the basis of Modified Mac Nab's criteria [Table 3].

Based on Modified Mac Nab's criteria 15 patients had excellent, 4 good and 1 fair result. Eighteen patients returned to work within 6 weeks and regained their pre-op functional status. Four patients complained of persistent mild back pain, while one patient had objective signs of nerve root irritation.

Intraoperative bleeding obscuring the operative field was encountered in two patients, and was controlled by packing the field with Adrenaline soaked gauze pieces and waiting for some time. Three patients had temporary urinary retention in post –op period and was relieved by single catheterization. One patient

had inadvertent nerve root injury initially resulted in paresthesia (in S1 dermatome which was absent initially) which subsided spontaneously in 4 months. No other major complications reported in literature, occurred in our study [Table4].<sup>[13-15]</sup>

**Table 1:** Symptoms associated with Lumbar disc disease

SNo.	Symptoms	Frequency	Percentage
1	Back pain	19	95
2	Radicular pain	20	100
3	Numbness	16	80
4	Paresthesia	6	30
5	Voiding difficulty	2	10
6	Perianal Anaesthesia	2	10

**Table 2:** Signs elicited in lumbar disc disease

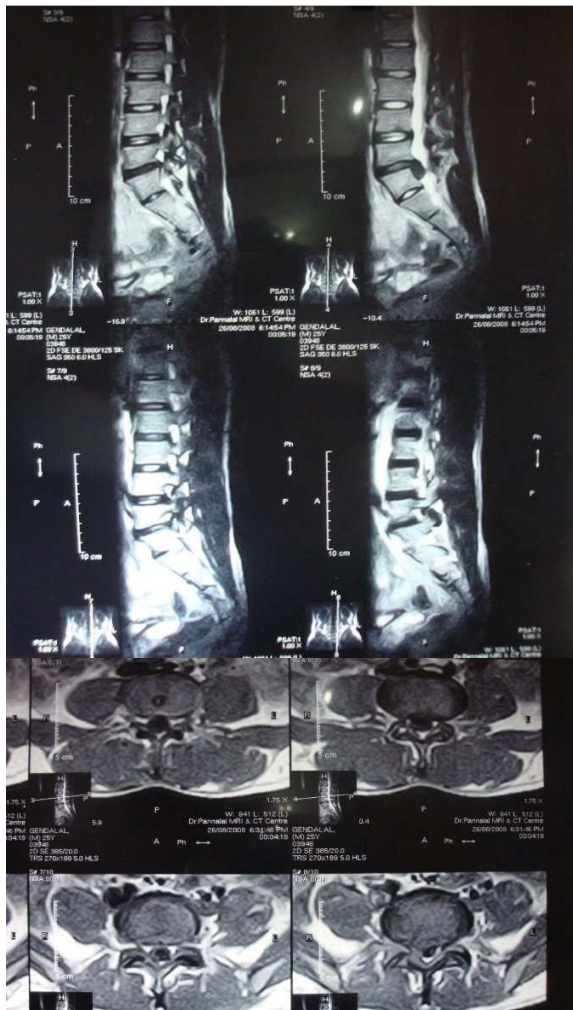
Sr. No.	Signs	Frequency	Percentage
1	Lasègue (+) with 60° or less	16	80
2	Crossed SLR (+) in unilateral sciatica	3 14	21.4
3	Paraspinal spasm	15	75
4	Restricted Spinal Movements	12	60
5	Motor deficit(s)	9	45
6	Sensory deficit(s)	16	80
7	Sluggish ankle reflex	3	15
8	Absent ankle reflex	4	20
9	Bladder involvement	2	10

**Table 3:** Assessment of the Surgical Outcome (Result analyzed on the basis of Modified Mac Nab's criteria)

Post-op assessment parameter	Yes	No
Pre-op functional status regained	18	2
Back pain/Leg pain	4	16
Dependency on medications	1	19
Appropriate activity	18	2
Objective signs of N. root irritation	1	19

**Table 4:** Complications

Complications	Frequency
<b>A)Local specific complications</b>	
Wrong level exposure	0
Missed pathology	0
Intraoperative bleeding obscuring the visual field	2
Dural injury	0
Root injury	1
Disc space infection	0
Repeat surgery	0
Failed back	0
<b>B)Local nonspecific complications</b>	
Major vessel or visceral injury	0
Cauda equina injury	0
Foreign body retention	0
Pressure complications secondary to positioning on table	0
<b>C)General complications</b>	
Postoperative thrombophlebitis	0
Pulmonary embolism	0
Atelectasis	0
Urinary retention	3 (Temporary)
Post-operative ileus	0
Mortality	0

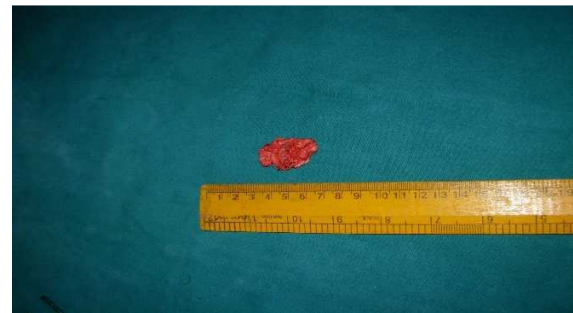

**Figure 1:** MRI impression – annular disc bulge at L5-S1 level with right paracentral extrusion and caudal migration at L5-S1 level indenting the thecal sac and the nerve roots bilaterally, more on the right side.

## DISCUSSION

Although lumbar discectomy is an operation in common practice, valid indications for operative treatment of patient with PIVD are still elusive and the results of such treatment have been inconsistent. Lumbar laminectomy is the most common operation for a herniated lumbar disc, but it has its inherent draw backs - prolonged surgical time, more blood loss and a delayed convalescence period. The post operative complications (e.g. arachnoiditis and adhesions) are found to be more when laminectomy is used as a procedure. Besides, it also found to jeopardize the mechanical stability of the spine. In such a situation a surgical procedure which offers less damage to the stability of the spine, shorter surgical time, less blood loss, lesser incidence of

post-operative complications and ultimately shorter convalescence period would be the ideal one. Discectomy by inter-laminar fenestration technique is exactly that kind of a surgical procedure where only the inter-laminar space is utilized without removal of any significant part of the lamina, the cord is exposed, retracted and the discectomy carried out.



**Figure 2:** Excised disc material

The advantages of this technique are decrease in the incidence of postoperative spinal instability, decreased manipulation of the neural elements and subsequent perineural fibrosis and less likelihood of penetration of the anterior annulus with potential injury to the viscera. In our study, the clinical outcome was evaluated for discectomy through fenestration in PIVD. However, the mean duration of the follow up was only 10.20 months with a minimum of 6 months; therefore, these patients have to be followed for a longer period of time to come to a definitive conclusion regarding long term results.

## REFERENCES

1. Hedtmann A. Das sog. Post-diskotomies syndrom Fehlschläge der Bandscheiben-operation? Z Orthop. 1992;130:456-66.
2. Loew F, Casper W. Surgical approach to lumbar disc herniations. Adv. standards Neurosurg. 1978;5:153-74.
3. Spengler D.M. Lumbar discectomy, Results with limited disc excision and selective foraminotomy. Spine. 1982;7:604-7.
4. Mixter WJ, Barr JS. Rupture of intervertebral discs with involvement of spinal canal. New Eng J Med. 1934;211:210-14.
5. Love JG. Root pain resulting from intraspinal protrusion of vertebral discs: diagnosis and treatment. J Bone Joint Surg. 1939;19:776-80
6. Kleinpeter G, Markowitsch MM, Bock F Percutaneous endoscopic lumbar discectomy: Minimally invasive, but perhaps only minimally useful? Surg Neurol. 1995;43(6):534-9.
7. Yeung AT The evolution of percutaneous spinal endoscopy and discectomy: State of the art. Mt Sinai J Med. 2000;67(4):327-332.
8. McCullough J.A. Chemoneucleolysis. J. Bone Joint Surg. 1977;59:45-52.

9. McCulloch JA. Chemonucleolysis for relief of sciatica due to a herniated intervertebral disc, *Can Med Assoc J.*1981;124:879.
10. Eismont F. and Currier B. Current Concept review, surgical management of lumbar intervertebral disc disease. *J.Bone Joint Surg.*1989;71:1266-1271.
11. McNab I Backache. Baltimore, Williams and Wilkins, 1977.
12. McNab I In surgical treatment of degenerative disc disease of the lumbar spine, *Recent Advances In Orthopaedics 2*, Edited by B. McKibbin, Churchill Living stone, Edinburg, London, New York, pp 1-33.
13. Hudgins WR The role of microdiscectomy. *Orthop Clin North Am.*1983;14:589-603.
14. Ebeling U,Reichenberg W,Reulen HJ Results of microsurgical lumbar discectomy: Review of 485 patients. 1986;81:45-52.
15. Nystrom B. Experience of microsurgical compared to conventional technique in lumbar disc operations. *Acta Neurol Scand.*1987;76:129-41.

**How to cite this article:** Aslam M, Khan FR, Huda N, Pant A, Julfiqar M, Goel A. Outcome of Discectomy by Fenestration Technique in Prolapsed Lumbar Intervertebral Disc. *Ann. Int. Med. Den. Res.* 2015;1(3):286-90.

**Source of Support:** Nil, **Conflict of Interest:** None declared