

Comparative Study of Surgically Induced Astigmatism in One and Two Side Port 2.8mm Clear Corneal Temporal Phacoemulsification in Cataract Surgery.

Arvind Kumar Morya¹, Arunendu Shekhar Thakur², Aftab Alam³

¹Associate Professor, Department of Ophthalmology, Teerthankar Mahaveer Medical College & Research Centre, Moradabad, India.

²Professor, Department of Ophthalmology, Teerthankar Mahaveer Medical College & Research Centre, Moradabad, India.

³Senior-Resident, Department of Ophthalmology, Teerthankar Mahaveer Medical College & Research Centre, Moradabad, UP, India.

ABSTRACT

Background: Surgically induced astigmatism (SIA) remains a common obstacle for achieving an excellent UCVA (Un Corrected Visual Acuity). The aim of this study is to compare surgically induced astigmatism (SIA) after one or two side ports with clear corneal temporal 2.8 mm phacoemulsification cataract surgery. **Methods:** Study comprised a multi-centric, nonrandomized prospective consecutive series of 358 eyes of 328 patients between age group of 9 to 71 years who had uneventful 2.8mm main temporal clear corneal incision and one or two side ports phacoemulsification cataract surgery with implantation of aspheric foldable intraocular lens (IOL). All surgery was performed by one experienced surgeon. Surgically induced astigmatism was calculated using Holladay-Carvy-Koch formula method. **Results:** At 1.5 months, the mean SIA was 0.51 diopter (D) for the one side port incisions and 1.50 D for two side port incisions ($P = 0.04$). At 3 months, the mean SIA were 0.41 D for one side port incisions and 1.25 D for two side port incisions ($P = 0.03$). **Conclusion:** The UCVA was far better in the one side port group, at 1.5 and 3 months post-operatively.

Keywords: Clear cornea, Phacoemulsification, SIA (Surgically Induced Astigmatism), Side-port, Temporal, UCVA (Un Corrected Visual Acuity)

INTRODUCTION

Nowadays clear corneal temporal phacoemulsification with IOL (Intra-Ocular lens) implantation is the surgery of choice in operable cataract cases with advantages of rapid vision-restoration, fast healing and minimum surgically induced astigmatism (SIA).^[1]

But surgically induced astigmatism (SIA) remains a common obstacle to achieving an excellent UCVA (Un Corrected Visual Acuity).^[2] SIA is related to the type, length and location of the incision, and the suture closure technique.^[3,4]

This multi-centric, prospective study compared the SIA in cataract patients undergoing 2.8mm clear corneal main incision phacoemulsification with one or two side ports.

MATERIALS AND METHODS

This multi-centric, prospective study included 358 eyes of 328 patients with various types of cataract between age group of 9 to 71 years.

Name & Address of Corresponding Author

Dr. Arvind Kumar Morya
Associate Professor,
Department of Ophthalmology, TMMC&RC,
Moradabad, UP, India.
Email: bulbul.morya@gmail.com

The patients with bilateral cataract underwent surgery with an interval of at least 7 days between procedures. None of the patients had a history of previous ocular surgery or diseases that would affect the corneal refraction. Written informed consent was obtained from each patient.

All eyes underwent a complete ophthalmological examination pre-operatively and post-operatively at 1.5 month and 3 month, including a manifest refraction using a refractometer and snellen projector chart. Astigmatism was measured from the keratometry readings. Data on gender, age, UCVA, manifest refraction, and automatic keratometry were collected.

All operations were performed by a single experienced surgeon using the same technique and topical or peribulbar anesthesia in all cases. The surgeon sat in the temporal position. Three-step, CCIs were made with a 2.8 mm disposable keratome. Temporal CCIs were used in all eyes. The depth of the first cut, a precut, was approximately one third of the corneal depth; the tunnel length was 1.50 mm to 1.75 mm. After injecting sodium hyaluronate), capsulorhexis (approximately 5.0-5.75 mm in diameter), a single or double side port incisions and hydro-dissection were performed. After phacoemulsification and cortex removal, a 1-piece foldable aspheric intraocular lens was then inserted. At the conclusion of surgery, proper hydro was done across all the wounds along the sides of the incision

and closed to achieve simple apposition of the wound without tension or gape [Figure 1-4].

SIA was calculated by vector analysis using the Holladay-Carvy-Koch formula.^[5-7] A paired Wilcoxon test was performed to determine if there was a significant effect on induced astigmatism depending on the one or two side ports group location (superior or inferior or both). A comparison of the 2 groups (one side-port or two side-port) was considered significant if $P < 0.05$ on SIA estimation.

RESULTS

Each group contained 179 cases. The mean age of the patients at the time of the baseline was 40.8 ± 31.0 years; there were 217 male and 111 female. The pre-operative corneal astigmatism in both groups ranged from 0.0 to 2.58 diopter (D). The level of pre-operative astigmatism was similar in the two groups (0.72 ± 0.42 in one side- port group, and 0.59 ± 0.52 in two side port group, $P = 0.100$).

Table 1. Mean Pre-Operative and Post-Operative Corneal Astigmatism

	Total Astigmatism- Mean \pm SD n=358		P - value
	One side-port(n=179)	Two side port (n=179)	
Pre-Operative	0.72 \pm 0.42	0.59 \pm 0.52	0.100
Post-Operative			
1.5 months	0.88 \pm 0.67	1.20 \pm 0.55	0.05
3.0 months	0.58 \pm 0.44	1.04 \pm 0.34	0.04

Table 2: UCVA % on Snellen Vision Projector in both the groups after 3 month.

Snellen Vision Range	One side port(n=179)	Two side-port(n=179)
6/5-6/9	79 (44.1%)	19 (10.6%)
6/9p-6/12	69 (38.5%)	75 (41.8%)
6/12p-6/18	26 (14.5%)	39 (21.7%)
6/18p-6/24	05 (2.7%)	30 (16.7%)
< 6/24	00	16 (8.9%)

Table 3: Surgically-induced mean astigmatic change by vector analysis using the Holladay-Cravy-Koch formula using Auto-Refrectrometer and Auto- Keratometer.

	Total Astigmatism- Mean \pm SD n=358		p- value
	One Side-Port(n=179)	Two Side-Port (n=179)	
Post-Operative			
1.5 months	0.51 \pm 0.64	1.50 \pm 0.53	0.04
3.0 months	0.41 \pm 0.39	1.25 \pm 0.48	0.03

DISCUSSION

Most modern cataract surgeons sit at the temporal aspect of the patient and use temporal CCIs (temporal approach). Most operating tables are now constructed for a surgeon sitting at the temporal side of the patient.^[7-9]

The main aim of this study was to compare the SIA caused by 2.8 mm temporal clear corneal main incisions with one or two side ports for 358 cataract eyes. The study was designed to assess variations in SIA in both the groups. In this study, a 2.8 mm corneal incision was used, and the effects on the SIA and corneal astigmatism of the one or two port incision on the 358 eyes were compared over a 3 month follow-up. The UCVA in the 2 types of incision were also compared. Both the SIA and UCVA were better in the one side- port group, post-operatively.

Nowadays, the size of the corneal incision has become gradually smaller, and previous studies

indicated that a smaller incision size is associated with earlier refraction stabilization and a reduced magnitude and variability of SIA.^[10-14]

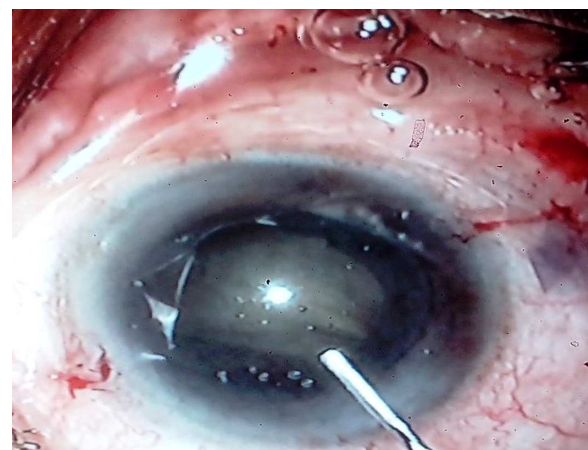


Figure. 1: Two Side-Ports with 2.8 mm Temporal Clear corneal Incision.

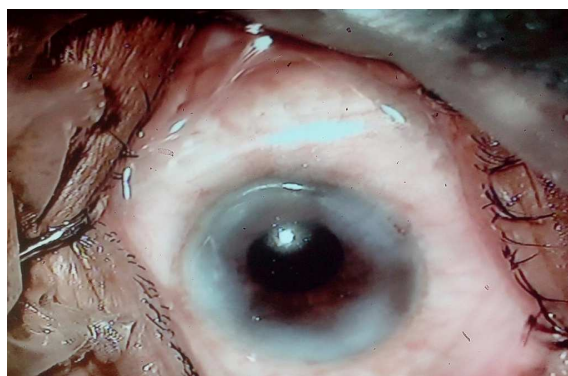

Figure 2: Same case after aspheric IOL Implantation & sealing of three Wounds

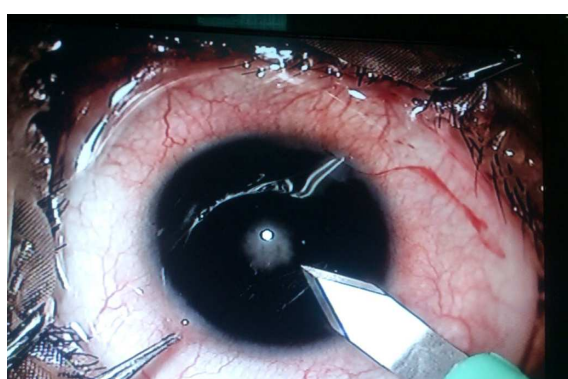


Figure 3: One Side Port with 2.8 mm temporal clear corneal incision.

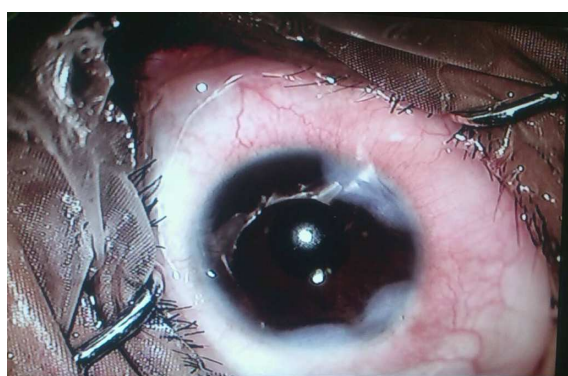

Figure 4: Same case after aspheric IOL Implantation & sealing of two wounds.

Although, an astigmatic axis shift is affected by the size, location, and shape of the incision, it was reported that the incision size has a major impact on SIA.^[15] The appropriate size for a self-sealing corneal incision is 2.8-3.5 mm,^[16] and the allowable limit of the keratometric shift for refraction and visual rehabilitation is approximately 0.50 D.^[12,13] This can be achieved with a 2.8 mm incision. With the introduction of micro-incisions (2.2 mm or less), it is now possible to minimize the SIA compared to larger

incisions.^[10] This means that in the future there will be no need to consider the incision locations, temporally, nasally or elsewhere.

Moreover, surgical equipment and skills in modern cataract surgery have been advanced gradually. Therefore, wound stress and stretching of the corneal tissue might be decreased. Decreased wound stress and stretching can make a smaller SIA. Therefore, the differences in SIA between a one side-port incision and two side-port incision in the present study could be smaller than in previous studies. In this study, the amounts of SIA were different in one and two side-ports incision.

In modern cataract surgery, the considering factors for optimum UCVA are surgical experience, preexisting corneal astigmatism, biometry prediction, and induced astigmatism.^[2] Currently, surgical complications and biometry prediction errors are rather low. Induced astigmatism shows a diminishing tendency. In the present study, the SIAs following 2.8 mm CCIs temporal with both one side-port and two side-ports were different, approximately 0.41 D in one side-port group and 1.25 D in two side port group. The induced corneal astigmatic change would be minimal with the introduction of micro-incision cataract surgery. Therefore, induced astigmatism may not be a limiting factor for an improved UCVA. One side-port incisions (2.0 mm or less) are more suitable for astigmatism-neutral cataract surgery, especially in deep-seated Indian eyes.

Acknowledgment

This research was supported by a fund from Teerthankar Mahaveer Medical College & Research Centre, Moradabad.

REFERENCES

1. Rainer G, Menapace R, Vass C, Annen D, Findl O, Schmetterer K. Corneal shape changes after temporal and superolateral 3.0 mm clear corneal incisions. *J Cataract Refract Surg.* 1999;25:112:1-6.
2. Barequet IS, Yu E, Vitale S, Cassard S, Azar DT, Stark WJ. Astigmatism outcomes of horizontal temporal versus nasal clear corneal incision cataract surgery. *J Cataract Refract Surg.* 2004;30:418-23.
3. Simşek S, Yaşar T, Demirok A, Cinal A, Yilmaz OF. Effect of superior and temporal clear corneal incisions on astigmatism after sutureless phacoemulsification. *J Cataract Refract Surg.* 1998;24:515-8.
4. Roman SJ, Auclin FX, Chong-Sit DA, Ullern MM. Surgically induced astigmatism with superior and temporal incisions in cases of with-the-rule preoperative astigmatism. *J Cataract Refract Surg.* 1998;24:1636-41.
5. Kohnen S, Neuber R, Kohnen T. Effect of temporal and nasal unsutured limbal tunnel incisions on induced astigmatism after phacoemulsification. *J Cataract Refract Surg.* 2002;28:821-5.

6. Giansanti F, Rapizzi E, Virgili G, Mencucci R, Bini A, Vannozzi L, et al. Clear corneal incision of 2.75 mm for cataract surgery induces little change of astigmatism in eyes with low preoperative corneal cylinder. *Eur J Ophthalmol.* 2006;16:385–93.
7. Holladay JT, Cravy TV, Koch DD. Calculating the surgically induced refractive change following ocular surgery. *J Cataract Refract Surg.* 1992;18:429–43
8. Ermi SS, Inan UU, Oztürk F. Surgically induced astigmatism after superotemporal and superonasal clear corneal incisions in phacoemulsification. *J Cataract Refract Surg.* 2004;30:1316–9.
9. Duke-Elder S, Wybar KC. *The Anatomy of the Visual System*. Vol. 2. London: Henry Kimpton; 1961,pp:234–9.
10. Wang J, Zhang EK, Fan WY, Ma JX, Zhao PF. The effect of micro-incision and small-incision coaxial phaco-emulsification on corneal astigmatism. *Clin Experiment Ophthalmol.* 2009;37:664–9.
11. Wei YH, Chen WL, Su PY, Shen EP, Hu FR. The influence of corneal wound size on surgically induced corneal astigmatism after phacoemulsification. *J Formos Med Assoc.* 2012;111:284–9.
12. Long DA, Monica ML. A prospective evaluation of corneal curvature changes with 3.0-to 3.5-mm corneal tunnel phacoemulsification. *Ophthalmology.* 1996;103:226–32.
13. Kohnen T, Dick B, Jacobi KW. Comparison of the induced astigmatism after temporal clear corneal tunnel incisions of different sizes. *J Cataract Refract Surg.* 1995;21:417–24.
14. Luo L, Lin H, He M, Congdon N, Yang Y, Liu Y. Clinical evaluation of three incision size-dependent phacoemulsification systems. *Am J Ophthalmol.* 2012;153:831–9
15. Anders N, Pham DT, Antoni HJ, Wollensak J. Postoperative astigmatism and relative strength of tunnel incisions: A prospective clinical trial. *J Cataract Refract Surg.* 1997;23:332–6.
16. Monica ML, Long DA. Nine-year safety with self-sealing corneal tunnel incision in clear cornea cataract surgery. *Ophthalmology.* 2005;112:985–6.

How to cite this article: Morya AK, Thakur AS, Alam A. Comparative Study of Surgically Induced Astigmatism in One and Two Side Port 2.8mm Clear Corneal Temporal Phacoemulsification in Cataract Surgery. *Ann. Int. Med. Den. Res.* 2015;1(3):277-80.

Source of Support: Nil, **Conflict of Interest:** None declared